1343

CALIFORNIA
TUMOR TISSUE REGISTRY

Tumors & Tumor-like Conditions of Lymph Nodes & Spleen

Study Cases, Subscription B

April, 2008

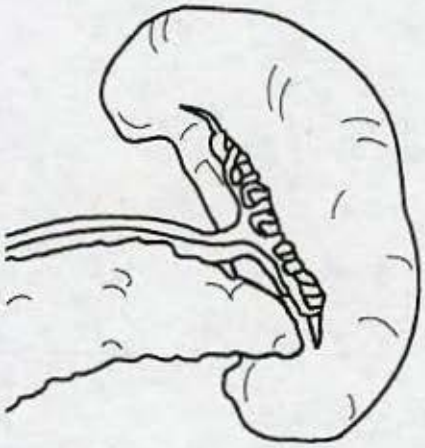

California Tumor Tissue Registry
c/o: Department of Pathology and Human Anatomy
Loma Linda University School of Medicine
11021 Campus Avenue, AH 335
Loma Linda, California 92350
(909) 558-4788
FAX: (909) 558-0188
E-mail: cttr@linkline.com
Web site & Case of the Month: www.cttr.org

Target audience:

Practicing pathologists and pathology residents.

Goal:

To acquaint the participant with the histologic features of a variety of benign and malignant neoplasms and tumor-like conditions.

Objectives:

The participant will be able to recognize morphologic features of a variety of benign and malignant neoplasms and tumor-like conditions and relate those processes to pertinent references in the medical literature.

Educational methods and media:

Review of representative glass slides with associated histories.
Feedback on consensus diagnoses from participating pathologists.
Listing of selected references from the medical literature.

Principal faculty:

Donald R. Chase, MD

CME Credit:

Loma Linda University School of Medicine designates this continuing medical education activity for up to 2 hours of Category I of the Physician's Recognition Award of the American Medical Association.
CME credit is offered for the subscription year only.

Accreditation:

Loma Linda University School of Medicine is accredited by the Accreditation Council for Continuing Medical Education (ACCME) to sponsor continuing medical education for physicians.

Contributor: LLUMC Pathology Group (cz)
Loma Linda, CA

Case No. 1 - April, 2008

Tissue from: Right hip

Accession # 30354

Clinical Abstract:

For nine months, this 5-year-old girl had been noted to walk with a limp. During that time, an FNA of the right hip was performed with negative results. An MRI revealed an expansile mass arising in the medial aspect of the acetabulum. There was no history of fevers or infection. Laboratory data included a WBC of 8.5, Hgb of 11.5, and ESR of 62.

Gross Pathology:

Unavailable.

Special Studies:

Negative: PAS, GMS, Acid Fast, S-100 protein.

Contributor: Guillermo Acero, M.D.
Ojai, CA

Case No. 2 - April, 2008

Tissue from: Left axillary lymph node

Accession #29912

Clinical Abstract:

A 31-year-old woman presented with an asymptomatic mass in the left axilla. She was six months post-partum and stated that the mass had been present for some time. She denied any fever or weight loss. CBC and biochemical studies were within normal limits. No other adenopathy was noted on examination. Past medical history included the removal of a right axillary lymph node approximately six years previously.

Gross Pathology:

The partially encapsulated lymph node measured 4.0 x 3.3 x 1.2 cm. The cut surface was pink-red with focal hemorrhage. No necrosis or fibrosis was identified.

Special Studies:

Bcl-2: Germinal centers positive
CD20: B cells & follicles positive
CD43: T cells & histiocytes positive
CD45: Many positive cells, including immunoblasts
CD15: Negative
CD3: Small T cell positive
CD23: Dendritic cell networks positive
CD30: Many immunoblasts positive

Contributor: Phillip Gordon, M.D.
Winter Haven, FL

Case No. 3 - April, 2008

Tissue from: Kidney

Accession #30191

Clinical Abstract:

A 78-year-old man presented with left flank discomfort. Work-up revealed a mass in the left kidney.

Gross Pathology:

The 426 gram nephrectomy specimen included hemorrhagic perinephric fat and a proximally dilated, slightly thickened ureter. The cut surface of the kidney was diffusely fleshy tan and white-tan with areas of geographic hemorrhage and white-yellow infarct. No distinct mass was seen.

Contributor: Steven A. Gustafson, D.O.
San Antonio, TX

Case No. 4 - April, 2008

Tissue from: Abdomen

Accession #30326

Clinical Abstract:

After complaining of abdominal pain with accompanying nausea and vomiting, this 4-year-old boy was found to have an abdominal mass.

Gross Pathology:

The 352.5 gram, 13.0 x 9.5 x 5.5 cm specimen consisted of a partially encapsulated, red to pink, rubbery tumor and attached blood clot. Several lymph nodes were partially embedded in the tumor. Cut surfaces showed of multiple ill-defined lobules.

Special Studies:

Positive: CD20, CD43, Bcl-2, CD5, Ki-67 (70%).
Negative: ALK-1, Bcl-6, TdT, Cyclin D-1, CD10.

Contributor: LLUMC Pathology Group (jw)
Loma Linda, CA

Case No. 5 - April, 2008

Tissue from: Left ovary

Accession #30506

Clinical Abstract:

A 35-year-old woman presented with complaints of back and abdominal pain. CT scan of the pelvis and abdomen revealed a left ovarian mass. No hematuria or problems with urination were noted. A left salpingo-oophorectomy was performed.

Gross Pathology:

The specimen consisted of a 115 gram, 6.0 x 4.0 x 4.0 cm mass with a 7.0 cm long oviduct. Sectioning of the tumor revealed firm white-tan parenchyma with scattered clear fluid-filled and smooth-walled cysts ranging from 0.1 to 0.5 cm. No definite ovarian parenchyma was seen.

Flow Cytometry:

Immunophenotyping showed an abnormal blast population (~80% total cells) expressing HLA-DR, CD9, CD10, CD19, CD20dim, CD22dim, CD34, CD38, and TdT, but not CD45, T-cell antigens, or myeloid antigens.

Contributor: Frank DeGregorio, M.D.
Sylmar, CA

Case No. 6 - April, 2008

Tissue from: Spleen

Accession #30283

Clinical Abstract:

A 51-year-old man had a four-day history of diffuse abdominal pain and decreased food intake. The patient reported a history of alcohol abuse, and stated that his last drink was approximately one week prior to admission through the Emergency Room. CT scan revealed a splenic laceration. Exploratory laparotomy and splenectomy were performed.

Gross Pathology:

The 1650 gram spleen had red-brown hemorrhage adherent to the external surface. On cut sectioning, there was partial necrosis which extended into the parenchyma, measuring 5.0 x 4.0 x 4.0 cm.

Special Studies:

Positive: CD3, CD20, CD43, CD57, CD79a, HgbA, MPO, TIA-1.
Negative: CD30.

Contributor: Frank DeGregorio, M.D.
Sylmar, CA

Case No. 7 - April, 2008

Tissue from: Left groin lymph nodes

Accession #30385

Clinical Abstract:

A 41-year-old man with a known history of hematologic disease elected to have a groin mass removed due to discomfort, after completing neoadjuvant chemotherapy.

Gross Pathology:

The specimen consisted of a 10 x 3 cm elliptical portion of skin with a 7.5 x 9.0 x 9.0 cm subjacent spherical portion of soft tissue. The cut surface showed fish-flesh consistency, yellow tissue with numerous areas of necrosis.

Special Studies:

Positive: CD34, CD43, CD117.
Negative: Pan-cytokeratin.

Contributor: Jozef Kollin, M.D.
Lakewood, CA

Case No. 8 - April, 2008

Tissue from: Left anterior medial thigh

Accession #30253

Clinical Abstract:

For six months, this 53-year-old woman had noticed a rapidly growing mass in her left thigh. MRI confirmed a circumscribed, 3 x 4 x 5 cm mass within the soft tissues of the anterolateral left thigh with impression onto the anterior aspect of the left sartorius muscle.

Gross Pathology:

The specimen consisted of an oval-shaped, encapsulated, shelled-out tissue fragment measuring 6.0 x 4.0 x 3.0 cm. It had an elastic consistency, and on sectioning, was lobular and grayish-tan with minute nodular foci of yellow necrosis.

Special Studies:

CD20, CD10, CD23, Bcl-2, Bcl-6: Follicles positive
CD3, CD5, CD43: Interfollicular areas positive
Ki-67: 70% positive.
Negative: Bcl-1.

Contributor: Pamela Boswell, D.O.
San Diego, CA

Case No. 9 - April, 2008

Tissue from: Left atrium

Accession #29408

Clinical Abstract:

A 29-year-old man presented with a middle cerebral artery stroke and a left atrial heart mass suspicious for an atrial myxoma, which was identified on echocardiogram. CT of the chest, abdomen and pelvis were negative. Physical examination revealed no peripheral lymphadenopathy. PCR for HIV was negative. Past medical history was significant for Von Willebrand's disease.

Gross Pathology:

The specimen consisted of a fimbriated and bosselated, glistening, 6.0 x 4.5 x 3.0 cm mass which was variegated gray-yellow and tan with red-brown ribbons on cut sectioning.

Special Studies:

Positive:	CD20, CD45 (focally).
Negative:	CD3 43 45 RO, CD30, Pan-cytokeratin, Low and high molecular weight cytokeratins, S-100, EMA, HMB-45, AFP, HCG, PLAP, Desmin, Smooth muscle actin, Muscle specific actin, Chromogranin, Synaptophysin, NSE.
Non-contributory:	Kappa, Lambda, Vimentin.

Immunoglobulin kappa light chain gene rearrangements were detected by PCR analysis.

Contributor: Jin Mei, M.D.
Hangzhou, China

Case No. 10 - April, 2008

Tissue from: Anterior mediastinum

Accession #30171

Clinical Abstract:

A 32-year-old man presented with complaints of chest "stuffiness", shortness of breath and cough of one month's duration. An anterior mediastinal mass was identified, which involved the sternum, pericardium and right pulmonary hilum.

Gross Pathology:

The specimen consisted of gray and gray-red tissue measuring 10.0 x 10.0 x 7.0 cm. The cut surface was soft and partially dark red.

Special Studies:

Positive:	Bcl-2 (focal), CD3, CD43, TdT.
Negative:	CD20, CD34, Kappa, Lambda, Pancytokeratin.

CALIFORNIA
TUMOR TISSUE REGISTRY

"Tumors of Lymph Nodes and Spleen"

Minutes – Subscription B

April, 2008

SUGGESTED READING (General Topics from Recent Literature):

Glypican-3 Expression in Benign Liver Tissue with Active Hepatitis C. Implications for the Diagnosis of Hepatocellular Carcinoma. Abdul-Al HM, Makhlouf HR, et al. *Hum Pathol* 2008: 209-212.

Expression of Platelet-Derived Growth Factors and Their Receptors in Ovarian Clear-Cell Carcinoma and Its Putative Precursors. Yamamotot S, Tsuda H, et al. *Mod Pathol* 2008; 21:115-124.

Effect of Device-Guided Breathing Exercises on Blood Pressure in Hypertensive Patients with Type 2 Diabetes Mellitus. A Randomized Controlled Trial. Logtenberg SJ, Kleefstra N, et al. *J Hypertens* 2007; 25:241-246.

Her2+Breast Cancer. Review of Biologic Relevance and Optimal Use of Diagnostic Tools. Hicks DG and Kulkarnia S. *Am J Clin Pathol* 2008; 129:263-273.

Microcystic Adnexal Carcinoma. An Immunohistochemical Reappraisal. Hoang MP, Dresser KA, et al. *Mod Pathol* 2008; 21:178-185.

California Tumor Tissue Registry
c/o: Department of Pathology and Human Anatomy
Loma Linda University School of Medicine
11021 Campus Avenue, AH 335
Loma Linda, California 92350
(909) 558-4788
FAX: (909) 558-0188
E-mail: cttr@linkline.com
Web site & Case of the Month: www.cttr.org

FILE DIAGNOSES

(Preferably submitted on website at www.cttr.org. Click "subscriptions", then "submit answers.")

CTTR Subscription B

Case 1:

Necrotizing granulomatous inflammation, acetabular region
T-Y2320, M-96303

Case 2:

Follicular hyperplasia with features suggestive of progressive transformation, axillary lymph node
T-08000, M-72200

Case 3:

Diffuse large cell lymphoma, kidney
T-71000, M-95903

Case 4:

Diffuse large B-cell lymphoma, abdominal lymph node
T-Y4100, M-95903

Case 5:

Precurser B-cell lymphoblastic leukemia (lymphoma, ovary)
T-87000, M-98613

Case 6:

Extramedullary hematopoesis with myeloid left shift (myeloproliferative disorder), spleen
T-07000, M-73500

Case 7:

Extramedullary myeloid tumor (granulocytic sarcoma), groin
T-Y7000, M-99303

Case 8:

Large B-cell lymphoma, follicular (75%) and diffuse (25%), lymph node of thigh
T-Y9100, M-95903

Case 9:

Diffuse large B-cell lymphoma, atrium
T-32120, M-95903

Case 10:

Precursor T-cell lymphoblastic lymphoma (WHO classification), mediastinum
T-Y2320, M-96303

Case No. 1 - Accession No. 30354 **April, 2008**

Costa Mesa (College Hospital) - Inflammatory pseudotumor
Escondido - Inflammatory synovitis
Loma Linda - Necrotizing lesion (granuloma)
Los Angeles (USC Medical Center) - Rheumatoid synovitis
San Diego (Naval Medical Center) - Inflammatory synovitis consistent with juvenile rheumatoid arthritis
San Diego (UCSD) - Necrotizing granulomatous inflammation (1); Low grade cartilaginous tumor (1)
Alabama (UAB) - Necrotizing granulomatous inflammation
Georgia, Decatur - Langerhans cell histiocytosis
Glendale - Necrotizing granuloma
Kansas (Coffeyville Regional Medical Center) - Necrotizing lymphadenitis, cat scratch disease
Kansas (Peterson Laboratory Services) - Mast cell disease (mastocytoma)
Maryland (DC) - Histiocytosis x
Michigan (HFH Pathology Residents) - Necrotizing granulomatous inflammation
New York (Stony Brook University Medical Center) - Cat scratch disease
Nevada (Sunrise Hospital) - Necrotizing granulomatous inflammation
New York (Roosevelt Hospital) - Langerhans histiocytosis
New York (SUNY Downstate Medical Center) - Granulomatous change, favor chronic granulomatous disease, rule out infectious etiology
North Carolina (Wake Forest University) - Necrotizing granulomatous inflammation
Pennsylvania (Drexel University) - Necrotizing lymphadenitis
Puerto Rico (University of Puerto Rico) - Granulomatous disease, probably sarcoidosis
San Francisco (SF Veterans Hospital) - Benign fibrous histiocytoma
Texas, Crystal Beach - Necrotizing granulomatous lesion (? Infectious)
Texas (Scott & White Memorial Hospital) - Sea blue histiocytosis
Wisconsin (St. Mary's Hospital) - Histiocytic lesion Langerhans cell histiocytosis vs. infection
Canada (Pasqua Hospital) - Chronic granulomatous disease
Canada (University of Sherbrooke) - Necrotizing granulomatous disease
Japan (Asahi General Hospital) - Legg, calve, Perthes disease
Saudi Arabia (King Abdulaziz Medical Center) - Necrotizing granulomatous inflammation
Spain (Povisa) - Necrotizing granulomatous lymphadenitis
United Kingdom (Oxford Study Group) - Necrotizing granulomatous inflammation

Case 1 - Diagnosis:

Necrotizing granulomatous inflammation, acetabular region
T-Y2320, M-96303

Outside Consultation: AFIP, Infectious Disease: "Granulomatous inflammation, probably tuberculosis despite negative AFB stains."

Case 1 - References:

Tan HW, Chuah KL, Goh SG, et al. An Unusual Cause of Granulomatous Inflammation. Eosinophilic Abscess in Langerhans Cell Histiocytosis. *J Clin Pathol* 2006; 59(5):548-549.

Spannuth WA, Leath CA, Conner MG, et al. Inflammatory Pseudotumor of Pelvic Lymph Nodes. *Obstet Gynecol* 2006; 108(3 pt 2):779-782.

Kurata A, Terado Y, Schulz A, Fujioka Y, et al. Inflammatory Cells in the Formation of Tumor-Related Sarcoid Reactions. *Hum Pathol* 2005; 36(5):546-554.

Zardawi IM, Barker BJ, Simons DP, et al. Hodgkin's Disease Masquerading as Granulomatous Lymphadenitis on Fine Needle Aspiration Cytology. *Cytol* 2005; 49(2):224-226.

Odenthal M, Koenig S, et al. Detection of Opportunistic Infections By Low-Density Microarrays. A Diagnostic Approach for Granulomatous Lymphadenitis. *Diagn Mol Pathol* 2007; 16(1):18-26.

Case No. 2 - Accession No. 29912 **April, 2008**

Costa Mesa (College Hospital) - Focal nodular lymphoma arising in follicular hyperplasia
Escondido - Reactive follicular hyperplasia
Loma Linda - Follicular lymphoma
Los Angeles (USC Medical Center) - Reactive lymphadenopathy
San Diego (Naval Medical Center) - Reactive follicular hyperplasia
San Diego (UCSD) - Interfollicular hyperplasia (1); Myelolipoma (1)
Alabama (UAB) - Follicular lymphoma
Georgia, Decatur - Reactive follicular hyperplasia
Glendale - Reactive lymph node
Kansas (Coffeyville Regional Medical Center) - Lymph node hyperplasia
Kansas (Peterson Laboratory Services) - Reactive lymphadenopathy
Maryland (DC) - Rosai-Dorfman disease
Michigan (HFH Pathology Residents) - Florid follicular and interfollicular hyperplasia with immunoblastic proliferation
New York (Stony Brook University Medical Center) - Follicular colonization of lymph node
Nevada (Sunrise Hospital) - Reactive follicular hyperplasia
New York (Roosevelt Hospital) - Reactive lymphoid hyperplasia
New York (SUNY Downstate Medical Center) - Progressive transformation of germinal centers
North Carolina (Wake Forest University) - Progressive transformation of germinal centers
Pennsylvania (Drexel University) - Follicular hyperplasia
Puerto Rico (University of Puerto Rico) - Follicular hyperplasia with follicular lymphoma (focal involvement)
San Francisco (SF Veterans Hospital) - Follicular colonization by HG B-cell lymphoma
Texas, Crystal Beach - Progressive transformation of germinal centers
Texas (Scott & White Memorial Hospital) - Follicular lymphoma
Wisconsin (St. Mary's Hospital) - Reactive follicular hyperplasia (rule out follicular lymphoma in flow)
Canada (Pasqua Hospital) - Hyperplasia
Canada (University of Sherbrooke) - Type B follicular lymphoma
Japan (Asahi General Hospital) - Follicular lymphoma
Saudi Arabia (King Abdulaziz Medical Center) - Reactive lymphoid follicular hyperplasia
Spain (Povisa) - Follicular lymphoma and follicular hyperplasia
United Kingdom (Oxford Study Group) - Low grade follicular lymphoma

Case 2 - Diagnosis:

Follicular hyperplasia with features suggestive of progressive transformation, axillary lymph node
T-08000, M-72200

Outside Consultation: Jun Wang, M.D., LLUMC: "Prominent follicular and focal parafollicular lymphoid hyperplasia with focal features suggestive of progressive transformation of germinal centers."

Case 2 - References:

de Leval L. Scary But Benign. Follicular Lymphoid Hyperplasia. *Int J Surg Pathol* 2008; 16(1):65.
Chang CC, Osipox v, Wheaton B, et al. Follicular Hyperplasia, Follicular Lysis, and Progressive Transformation of Germinal Centers. A Sequential Spectrum of Morphologic Evolution in Lymphoid Hyperplasia. *Am J Clin Pathol* 2003; 120(3):322-326.
Kojima M, Nakamura S, Mottori E, et al. Progressive Transformation of Germinal Centers. A Clinicopathological Study of 42 Japanese Patients. *Int J Surg Pathol* 2003; 11(2):101-107.
Yamamoto K, Okamura A, et al. A Novel (t(2; 6) (p12; q23) Appearing During Transformation of Follicular Lymphoma with t(18; 22) (q21; q11) to Diffuse Large Cell Lymphoma. *Cancer Genet Cytogenet* 2003; 147(2):128-133.
Montoto A, Davies AJ, Matthews J, et al. Risk and Clinical Implications of Transformation of Follicular Lymphoma to Diffuse Large B-Cell Lymphoma. *J Clin Oncol* 2007; 25(17):2426-2433.

Case No. 3 - Accession No. 30191 **April, 2008**

Costa Mesa (College Hospital) - Malignant lymphoma, possible mycosis fungoides
Escondido - Diffuse large cell lymphoma
Loma Linda - Kidney, lymphoma
Los Angeles (USC Medical Center) - Renal pseudolymphoma
San Diego (Naval Medical Center) - Atypical lymphoid infiltrate, favor lymphoma
San Diego (UCSD) - Favor diffuse aggressive large cell lymphoma (1); Atypical lipomatous tumor/well-differentiated liposarcoma (1)
Alabama (UAB) - Large cell lymphoma
Georgia, Decatur - Large cell lymphoma with anaplastic features
Glendale - Lymphoma
Kansas (Coffeyville Regional Medical Center) - Malignant lymphoma, angiocentric T-cell (lymphomatoid granulomatosis
Kansas (Peterson Laboratory Services) - Diffuse large cell lymphoma
Maryland (DC) - Follicular lymphoma
Michigan (HFH Pathology Residents) - Poorly differentiated malignant neoplasm, sus. for large cell lymphoma
New York (Stony Brook University Medical Center) - Diffuse large B-cell lymphoma
Nevada (Sunrise Hospital) - Non-Hodgkin lymphoma, extranodal marginal zone B cell lymphoma
New York (Roosevelt Hospital) - Maloleoplakia
New York (SUNY Downstate Medical Center) - Large cell lymphoma, rule out lymphomatoid granulomatosis
North Carolina (Wake Forest University) - Lymphomatoid granulomatosis
Pennsylvania (Drexel University) - Xanthogranulomatosis
Puerto Rico (University of Puerto Rico) - Diffuse large B-cell lymphoma
San Francisco (SF Veterans Hospital) - Lymphoma (1/2) vs. chronic inflammatory process (1/2)
Texas, Crystal Beach - Lymphoma non-Hodgkins, high grade
Texas (Scott & White Memorial Hospital) - Xanthogranulomatous pyelonephritis
Wisconsin (St. Mary's Hospital) - Lymphoma vs. xanthogranulomatous pyelonephritis
Canada (Pasqua Hospital) - Xanthogranulomatous pyelonephritis
Canada (University of Sherbrooke) - Leukemic infiltrate
Japan (Asahi General Hospital) - Xanthogranulomatous pyelonephritis
Saudi Arabia (King Abdulaziz Medical Center) - Non Hodgkin lymphoma, favor peripheral T-cell lymphoma
Spain (Povisa) - Diffuse large cell lymphoma/ana
United Kingdom (Oxford Study Group) - Large cell lymphoma (1); Myeloma (4); Leukemia (3)

Case 3 - Diagnosis:

Diffuse large cell lymphoma, kidney
T-71000, M-95903

Case 3 - References:

Sawa N, Ubara Y, et al. Renal Intravascular Large B-Cell Lymphoma Localized Only With Peritubular Capillaries. Report of a Case. Sawa N, Ubara Y, et al. *Inter Med* 2007; 46(10):657-662.

Al-Masri H and Alkan S. Osseous Metaplastia In Diffuse Large B-Cell Lymphoma of the Kidney. *Am J Hematol* 2007; 82(4):321-324.

Guilpain P, Delarue R, Matignon M, et al. Primary Bilateral Diffuse Renal Lymphoma. *Am J Hematol* 2006; 81(10):804-804.

Ahmad AH, Maclennan GT, and Listinsky C. Primary Renal Lymphoma. A Rare Neoplasm That May Present as a Primary Renal Mass. *J Urol* 2005; 173(1):239.

Wagner SD, Amen F, Trivedi PS, et al. Bcl-6 and C-Myc Are Rarely Co-Expressed in Adult Diffuse Large B-Cell Lymphoma. *Leuk Lymphoma* 2007; 48(8):1510-1513.

Case No. 4 - Accession No. 30326 **April, 2008**

Costa Mesa (College Hospital) - Malignant lymphoma, small B-cell type, diffuse
Escondido - Burkitt's lymphoma
Loma Linda - Large B-cell lymphoma
Los Angeles (USC Medical Center) - Small lymphocytic lymphoma
San Diego (Naval Medical Center) - Diffuse B-cell lymphoma
San Diego (UCSD) - Diffuse aggressive B-cell lymphoma (1); Aggressive fibromatosis (1)
Alabama (UAB) - Diffuse large B-cell lymphoma
Georgia, Decatur - Diffuse large B-cell lymphoma
Glendale - High-grade B-cell lymphoma
Kansas (Coffeyville Regional Medical Center) - Malignant lymphoma, mantle cell type
Kansas (Peterson Laboratory Services) - Diffuse large B-cell lymphoma
Maryland (DC) - Diffuse large B-cell lymphoma
Michigan (HFH Pathology Residents) - de novo CD5+ diffuse large B-cell lymphoma
New York (Stony Brook University Medical Center) - Atypical Burkeitts lymphoma
Nevada (Sunrise Hospital) - Diffuse large B-cell lymphoma
New York (Roosevelt Hospital) - CD5 (+) DLBCL
New York (SUNY Downstate Medical Center) - Diffuse large B-cell lymphoma
North Carolina (Wake Forest University) - Diffuse large B-cell lymphoma
Pennsylvania (Drexel University) - Diffuse large B-cell lymphoma
Puerto Rico (University of Puerto Rico) - Diffuse large B-cell lymphoma
San Francisco (SF Veterans Hospital) - Diffuse large B-cell lymphoma
Texas, Crystal Beach - Burkitt-like lymphoma
Texas (Scott & White Memorial Hospital) - Burkitt-like lymphoma
Wisconsin (St. Mary's Hospital) - Burkitt's lymphoma
Canada (Pasqua Hospital) - Mantle cell lymphoma
Canada (University of Sherbrooke) - Large B cell lymphoma
Japan (Asahi General Hospital) - Burkitt lymphoma
Saudi Arabia (King Abdulaziz Medical Center) - Diffuse large B-cell lymphoma
Spain (Povisa) - CD5+ Burkitt lymphoma
United Kingdom (Oxford Study Group) - Burkitt-like lymphoma

Case 4 - Diagnosis:

Diffuse large B-cell lymphoma, abdominal lymph node
T-Y4100, M-95903

Case 4 - References:

Connor J and Ashton-Key M. Gastric and Intestinal Diffuse Large B-Cell Lymphoma are Clinically and Immunophenotypically Different. An Immunohistochemical and Clinical Study. *Histopathol* 2007; 51(5):697-703.

Kim DH, Baek JH, Chae YS, et al. Absolute Lymphocyte Counts Predicts Response to Chemotherapy and Survival in Diffuse Large B-Cell Lymphoma. *Leukemia* 2007; 21(10): 2227-2230.

Linderoth J, Ehinger M, et al. CD40 Expression Identifies A Prognostically Favourable Subgroup of Diffuse Large B-Cell Lymphoma. *Leuk Lymphoma* 2007 48(9):1774-1779.

Armitage JO. How I Treat Patients with Diffuse Large B-Cell Lymphoma. *Blood* 2007; 110(1):1774-1779.

De Paepe P, De Wolf-Peeters C, et al. Diffuse Large B-Cell Lymphoma. A Heterogeneous Group of Non-Hodgkin Lymphomas Comprising Several Distinct Clinicopathological Entities. *Leukemia* 2007; 21(1):37-43.

Case No. 5 - Accession No. 30506 **April, 2008**

Costa Mesa (College Hospital) - Lymphoblastic lymphoma
Escondido - B-cell lymphoblastic lymphoma
Loma Linda - Precursor B-cell lymphoblastic lymphoma
Los Angeles (USC Medical Center) - Pre-B lymphoblastic lymphoma

San Diego (Naval Medical Center) - B-LBL
San Diego (UCSD) - Lymphoblastic lymphoma (1); Low grade fibromyxoid sarcoma (1)
Alabama (UAB) - Early precursor B-lymphoblastic leukemia/lymphoma
Georgia, Decatur - B-cell acute lymph
Glendale - Lymphoblastic lymphoma
Kansas (Coffeyville Regional Medical Center) - Malignant lymphoma diffuse B-cell
Kansas (Peterson Laboratory Services) - Lymphoblastic lymphoma
Maryland (DC) - Precursor B lymphoblastic lymphoma
Michigan (HFH Pathology Residents) - Precursor B-cell lymphoblastic lymphoma/leukemia
New York (Stony Brook University Medical Center) - Precursor B acute lymphoblastic leukemia
Nevada (Sunrise Hospital) - B-cell lymphoblastic lymphoma
New York (Roosevelt Hospital) - Precursor B-cell lymphoma
New York (SUNY Downstate Medical Center) - Precursor B-cell acute lymphoblastic lymphoma
North Carolina (Wake Forest University) - Precursor B-cell lymphoblastic lymphoma
Pennsylvania (Drexel University) - Precursor B-lymphoblastic lymphoma
Puerto Rico (University of Puerto Rico) - Precursor B lymphoblastic lymphoma
San Francisco (SF Veterans Hospital) - B-cell acute lymphocytic leukemia
Texas, Crystal Beach - Lymphoblastic lymphoma B-cell
Texas (Scott & White Memorial Hospital) - Lymphoblastic lymphoma
Wisconsin (St. Mary's Hospital) - ALL leukemic infiltrate, B-cell type
Canada (Pasqua Hospital) - Lymphoblastic lymphoma
Canada (University of Sherbrooke) - Lymphoblastic B-cell lymphoma
Japan (Asahi General Hospital) - Mantle cell lymphoma
Saudi Arabia (King Abdulaziz Medical Center) - Precursor B lymphoblastic lymphoma
Spain (Povisa) - Precursor B-cell lymphoblastic lymphoma
United Kingdom (Oxford Study Group) - Precursor B lymphoblastic lymphoma

Case 5 - Diagnosis:

Precurser B-cell lymphoblastic leukemia (lymphoma, ovary)
T-87000, M-98613

Outside Consultation: Edward Rowsell, M.D., Ph.D. (LLUMC): "Precursor B-cell lymphoblastic leukemia/lymphoma."

Case 5 - References:

Cox CV and Blair A. A Primitive Cell Origin for B-Cell Precursor ALL? *Stem Cell Rev* 2005; 1(3):189-196.
Alvarez Y, Coll MD, Ortega JJ, et al. Genetic Abnormalities Associated with the t(12; 21) and their Impact In the Outcome of 56 Patients with B-Precursor Acute Lymphoblastic Leukemia. *Cancer Genet Cytogenet* 2005; 162(1):3302-3304.
Jeha S, Behm F, Pei D, et al. Prognostic Significance of CD20 Expression in Childhood B-Cell Precursor Acute Lymphoblastic Leukemia. *Blood* 2006; 108(10):3302-3304.
Sahni C and Desai S. Primary Testicular Precursor B-Lymphoblastic Lymphoma. A Rare Entity. *Leuk Lymphoma* 2007; 48(10):2060-2062.
Iyengar P, Ismiil N, Deodhare S, et al. Precursor B-Cell Lymphoblastic Lymphoma of the Ovaries. An Immunohistochemical Study and Review of the Literature. *Int J Gynecol Pathol* 2004; 23(2):193-197.

Case No. 6 - Accession No. 30283 **April, 2008**

Costa Mesa (College Hospital) - Extramedullary hematopoeisis and chronic passive congestion
Escondido - CMML
Loma Linda - Lymphoplasmacytic lymphoma
Los Angeles (USC Medical Center) - Extramedullary hematopoeisis
San Diego (Naval Medical Center) - Extramedullary hematopoeisis
San Diego (UCSD) - Myeloproliferative disorder, favor CML (1); Fibrosarcoma (fibrosarcomatous DFSP with giant rosettes) (1)
Alabama (UAB) - Extramedullary, hematopoiesis

Georgia, Decatur - Extramedullary hematopoiesis
Glendale - Granulocytic sarcoma
Kansas (Coffeyville Regional Medical Center) - Marginal zone hyperplasia
Kansas (Peterson Laboratory Services) - Hepatosplenic T-cell lymphoma
Maryland (DC) - Splenic extramedullary hematopoiesis due to myeloid metaplasia or megaloblastic anemia
Michigan (HFH Pathology Residents) - Extramedullary hematopoiesis
New York (Stony Brook University Medical Center) - Extramedullary hematopoeisis
Nevada (Sunrise Hospital) - Extramedullary hematopoiesis
New York (Roosevelt Hospital) - Myeloproliferative syndrome
New York (SUNY Downstate Medical Center) - Extramedullary hematopoiesis (due to idiopathic myelofibrosis)
North Carolina (Wake Forest University) - Extramedullary hematopoiesis (suggest marrow exam)
Pennsylvania (Drexel University) - Extramedullary hematopoiesis
Puerto Rico (University of Puerto Rico) - Extramedullary hematopoiesis
San Francisco (SF Veterans Hospital) - Extramedullary hematopoiesis
Texas, Crystal Beach - Extramedullary hematopoiesis
Texas (Scott & White Memorial Hospital) - Extramedullary hematopoiesis
Wisconsin (St. Mary's Hospital) - Myeloid dysplasia (extramedullary hematopoiesis), spleen
Canada (Pasqua Hospital) - Extramedullary hematopoesis
Canada (University of Sherbrooke) - Extramedullary hematopoesis (myeloproliferative syndrome)
Japan (Asahi General Hospital) - Agnogenic myeloid metaplasia
Saudi Arabia (King Abdulaziz Medical Center) - Myeloid metaplasia
Spain (Povisa) - Nodular lymphocyte predominance Hodgkin lymphoma/T-cell-rich large B-cell lymphoma
United Kingdom (Oxford Study Group) - Extramedullary haemopoiesis

Case 6 - Diagnosis:

Extramedullary hematopoesis with myeloid left shift (myeloproliferative disorder), spleen
T-07000, M-73500

Case 6 - References:

Singer A, Maldjian P, Simmons MZ, et al. Extramedullary Hematopoiesis Presenting as a Focal Splenic Mass. A Case Report. *Abdom Imaging* 2004; 29(6):710-712.

Nappi O, Boscaino A and Wick MR. Extramedullary Hematopoietic Proliferations, Extraosseous Plasmacytomas, and Ectopic Splenic Implants (Splenosis). *Semin Diagn Pathol* 2003; 20(4):338-356.

Pandit TS, Sikora L, et al. Sustained Exposure to Nicotine Leads to Extramedullary Hematopoiesis in the Spleen. *Stem Cells* 2006; 24(11):2373-2381.

Khaldoyanidi S, Sikora L, Broide DH, et al. Constitutive Overexpression of IL-5 Induces Extramedullary Hematopoiesis in the Spleen. *Blood* 2003; 101(3):863-868.

Suttie Aw. Histopathology of the Spleen. *Toxicol Pathol* 2006; 34(5): 466-503.

Case No. 7 - Accession No. 30385 April, 2008

Costa Mesa (College Hospital) - Malignant lymphoma, large cell type B
Escondido - Myeloid (granulocytic) sarcoma
Loma Linda - Leukemia
Los Angeles (USC Medical Center) - Granulocytic sarcoma
San Diego (Naval Medical Center) - Myeloid sarcoma
San Diego (UCSD) - Myeloid sarcoma (1); Leiomyosarcoma (1)
Alabama (UAB) - Granulocytic sarcoma
Georgia, Decatur - Extramedullary myeloid tumor
Glendale - Granulocytic sarcoma
Kansas (Coffeyville Regional Medical Center) - Malignant stem cell tumor
Kansas (Peterson Laboratory Services) - Myeloid sarcoma
Maryland (DC) - Myeloid sarcoma
Michigan (HFH Pathology Residents) - Extramedullary myeloid tumor, consistent with granulocytic sarcoma
New York (Stony Brook University Medical Center) - Granulocytic sarcom

Nevada (Sunrise Hospital) - Granulocytic sarcoma
New York (Roosevelt Hospital) - Granulocytic sarcoma
New York (SUNY Downstate Medical Center) - Myeloid sarcoma, blastic type
North Carolina (Wake Forest University) - Granulocytic sarcoma
Pennsylvania (Drexel University) - Myelosarcoma
Puerto Rico (University of Puerto Rico) - Myeloid sarcoma
San Francisco (SF Veterans Hospital) - Granulocytic/myeloid sarcoma (chloroma)
Texas, Crystal Beach - Leukemia blastic (lymphoblastic)
Texas (Scott & White Memorial Hospital) - Granulocytic sarcoma
Wisconsin (St. Mary's Hospital) - Granulocytic sarcoma (AML infiltration)
Canada (Pasqua Hospital) - Myeloid leukemia
Canada (University of Sherbrooke) - Undifferentiated rule out leukemia (acute myeloid)
Japan (Asahi General Hospital) - Myeloid sarcoma
Saudi Arabia (King Abdulaziz Medical Center) - Granulocytic sarcoma
Spain (Povisa) - Granulocytic sarcoma
United Kingdom (Oxford Study Group) - Acute myeloid leukemia

Case 7 - Diagnosis:

Extramedullary myeloid tumor (granulocytic sarcoma), groin
T-Y7000, M-99303

Outside Consultation: Jonathan Said, M.D. (UCLA Medical Center): "Extramedullary myeloid tumor (granulocytic sarcoma)."

Case 7 - References:

Paydas S, Zorludemir S, Ergin M, et al. Granulocytic Sarcoma. 32 Cases and Review of the Literature. *Leuk Lymphoma* 2006; 47(12):2527-2541.

Pelosini M and Benedetti E, et al. Granulocytic Sarcoma and Subsequent Acute Leukemia Recurrence with Different Bilogic Characteristics 5 Years After Allogeneic Bone Marrow Transplantation for Acute Myeloid Leukemia. *Bone Marrow Transplant* 2006; 37(9):897-898.

Shahid Z, Saleh H and Nasser KA. Myeloid Sarcoma Presenting with Acute Renal Failure and Bilateral Ureteral Obstruction. A Case Report and Review of the Literature. *Am J Med Sci* 2007; 334(2):136-138.

Fulciniti F, Zeppa P, et al. Lymph Node Localizaton of Extramedullary Myeloid Cell Tumor in Myelodysplastic Syndrome. Report of One Case Diagnosed by Fine-Needle Cytology. *Diagn Cytopathol* 2003; 28(3):136-139.

Madhumathi DS, Sundareshan TS, Amirtham U, et al. Blastic Extramedullary Myeloid Cell Tumor of the Lymph Node Diagnosed By Fine Needle Aspiration. *Acta Cytol* 2003; 47(1):101-103.

Case No. 8 - Accession No. 30253 April, 2008

Costa Mesa (College Hospital) - Hodgkin's disease, extranodal
Escondido - Diffuse large B-cell lymphoma
Loma Linda - Follicular lymphoma
Los Angeles (USC Medical Center) - Follicular lymphoma
San Diego (Naval Medical Center) - Diffuse large B-cell arising from Grade III follicular lymphoma
San Diego (UCSD) - T-cell lymphoma, rule out anaplastic large cell lymphoma (1); Pleomorphic rhabdomyosarcoma (1)
Alabama (UAB) - Diffuse large B-cell lymphoma, anaplastic variant
Georgia, Decatur - Follicular lymphoma with high content of cells with lobated nuclei
Glendale - High-grade B-cell lymphoma
Kansas (Coffeyville Regional Medical Center) - Malignant lymphoma, nodular, large B-cell type
Kansas (Peterson Laboratory Services) - Follicular lymphoma, Grade 3
Maryland (DC) - Anaplastic diffuse large B-cell lymphoma
Michigan (HFH Pathology Residents) - Follicular lymphoma, grade 3/3, with focal diffuse large B-cell lymphoma
New York (Stony Brook University Medical Center) - High-grade follicular lymphoma
Nevada (Sunrise Hospital) - Follicular lymphoma 3/3 with areas of diffuse large B-cell lymphoma
New York (Roosevelt Hospital) - Follicular lymphoma, grade III

New York (SUNY Downstate Medical Center) - Diffuse large B-cell lymphoma (germinal center B-cell like)
North Carolina (Wake Forest University) - Diffuse large B-cell lymphoma arising from Grade 3 follicular lymphoma
Pennsylvania (Drexel University) - Follicular lymphoma
Puerto Rico (University of Puerto Rico) - Follicular lymphoma, grade 3/3
San Francisco (SF Veterans Hospital) - Follicular lymphoma, grade 3
Texas, Crystal Beach - High grade non Hodgkin's lymphoma B-cell Burkitt-like
Texas (Scott & White Memorial Hospital) - Follicular and diffuse B-cell lymphoma
Wisconsin (St. Mary's Hospital) - Large B-cell lymphoma (follicular cell lymphoma), follicular pattern
Canada (Pasqua Hospital) - Follicualr lymphoma
Canada (University of Sherbrooke) - Follicular lymphoma (transformed large cell)
Japan (Asahi General Hospital) - Follicular lymphoma
Saudi Arabia (King Abdulaziz Medical Center) - Follicular lymphoma, grade 3
Spain (Povisa) - Diffuse large B-cell lymphoma
United Kingdom (Oxford Study Group) - High grade follicular lymphoma

Case 8 - Diagnosis:

Large B-cell lymphoma, follicular (75%) and diffuse (25%), lymph node of thigh
T-Y9100, M-95903

Case 8 - References:

Yokose N, Shioi y, Sugisaki Y, et al. CD5-Positive Diffuse Large B-Cell Lymphoma with an Unusual Phenotype. Cytoplasmic CD20 (+), Surface CD20 (-). *Leuk Lymphoma* 2006; 47(7):1415-1417.

Muris JJ, Meijer CJ, Ossenkoppele GJ, et al. Apoptosis Resistance and Respose to Chemotherapy in Primary Nodal Diffuse Large B-Cell Lymphoma. *Hematol Oncol* 2006; 24(3):97-104.

Airaghi L, Greco I, et al. Unusual Presentation of Large B-Cell Lymphoma. A Case Report and Review of Literature. *Clin Lab Haematol* 2006; 28(5):338-342.

Coiffier B. Standard Treatment of Advanced-Stage Diffuse Large B-Cell Lymphoma. *Semin Hematol* 2006; 43(4): 213-220.

Case No. 9 - Accession No. 29408 **April, 2008**

Costa Mesa (College Hospital) - Introvascular lymphoma, large B-cell type
Escondido - Diffuse large B-cell lymphoma
Loma Linda - Necrotic nodular lymphocytie predominant Hodgkin's disease NLPHD
Los Angeles (USC Medical Center) - Infectious nononucleosis
San Diego (Naval Medical Center) - Primary cardiac lymphoma
San Diego (UCSD) - Large B-cell lymphoma (1); Pleomorphic undifferentiated sarcoma, MPNST (1)
Alabama (UAB) - Intravascular large B-cell lymphoma
Georgia, Decatur - Intravascular large B-cell lymphoma
Glendale - High-grade B-cell lymphoma
Kansas (Coffeyville Regional Medical Center) - Malignant lymphoma, large B-immunoblastic
Kansas (Peterson Laboratory Services) - Large B-cell lymphoma, favor primary
Maryland (DC) - Diffuse large B-cell lymphoma
Michigan (HFH Pathology Residents) - Intravascular large B-cell lymphoma
New York (Stony Brook University Medical Center) - Diffuse large B-cell lymphoma
Nevada (Sunrise Hospital) - Diffuse large B-cell lymphoma, plasmablastic type
New York (Roosevelt Hospital) - Intravascular B-cell lymphoma
New York (SUNY Downstate Medical Center) - Diffuse large B-cell lymphoma
North Carolina (Wake Forest University) - Diffuse large B-cell lymphoma
Pennsylvania (Drexel University) - Lymphoplasmablastic lymphoma
Puerto Rico (University of Puerto Rico) - Diffuse large B-cell lymphoma
San Francisco (SF Veterans Hospital) - Diffuse large B-cell lymphoma
Texas, Crystal Beach - High grade non-Hodgkin's lymphoma
Texas (Scott & White Memorial Hospital) - Large B-cell lymphoma
Wisconsin (St. Mary's Hospital) - B-cell lymphoma
Canada (Pasqua Hospital) - Large B-cell lymphoma

Canada (University of Sherbrooke) - Large B-cell lymphoma vs. primary effusion lymphoma
Japan (Asahi General Hospital) - Diffuse large B-cell lymphoma
Saudi Arabia (King Abdulaziz Medical Center) - Diffuse large B-cell lymphoma
Spain (Povisa) - Diffuse large B-cell lymphoma (immunoblastic/plasmocytoid)
United Kingdom (Oxford Study Group) - Diffuse large B-cell lymphoma

Case 9 - Diagnosis:

Diffuse large B-cell lymphoma, atrium
T-32120, M-95903

Case 9 - References:

Zakynthinos E, Tasopoulos G, et al. Huge Biatrial Primary Cardiac B-Cell Lymphoma Resulting in Bilateral Atrioventricular Valve Obstruction. *Leuk Lymphoma* 2004; 45(11):2339-2342.

Ottavianai G, Matturri L, Rossi L, et al. Sudden Death Due to Lymphomatous Infiltration of the Cardiac Conduction System. *Cardiovasc Pathol* 2003; 2(2):77-81.

Nascimento AF, Winters GL and Pinkus GS. Primary Cardiac Lymphoma. Clinical, Histologic Immunophenotypic, and Genotypic Features of Five Cases of a Rare Disorder. *Am J Surg Pathol* 2007; 31(9):1344-1350.

Gosev I, Siric F, Gasparovic H, et al. Surgical Treatment of a Primary Cardiac Lymphoma presenting with Tamponade Physilogy. *J Card Surg* 2006; 21(4):414-416.

Quigley MM and Schwartzman E, et al. A Unique Atrial Primary Cardiac Lymphoma Mimicking Myxoma Presenting with Embolic Stroke. A Case Report. *Blood* 2003; 101(12):4708-4710.

Case No. 10 - Accession No. 30171 **April, 2008**

Costa Mesa (College Hospital) - Malignant lymphoma, small T-cell type
Escondido - T-cell lymphoblastic lymphoma
Loma Linda - Small T-cell lymphocytic lymphoma
Los Angeles (USC Medical Center) - T-cell lymphoblastic lymphoma
San Diego (Naval Medical Center) - T-LBL
San Diego (UCSD) - T lymphoblastic lymphoma (1); Epithelioid hemangioendothelioma (1)
Alabama (UAB) - T lymphoblastic leukemia/lymphoma
Georgia, Decatur - T-cell acute lymphoblastic lymphoma
Glendale - Lymphoma
Kansas (Coffeyville Regional Medical Center) - Malignant lymphoma, T-cell lymphoblastic
Kansas (Peterson Laboratory Services) - Lymphoblastic lymphoma
Maryland (DC) - Precursor T lymphoblastic lymphoma
Michigan (HFH Pathology Residents) - Precursor T-cell lymphoblastic lymphoma/leukemia
New York (Stony Brook University Medical Center) - Precursor T acute lymphoblastic leukemia
Nevada (Sunrise Hospital) - T-cell lymphoblastic lymphoma
New York (Roosevelt Hospital) - Precursor B-cell lymphoma
New York (SUNY Downstate Medical Center) - Precursor T-cell acute lymphoblastic lymphoma
North Carolina (Wake Forest University) - Precursor T-cell lymphoblastic lymphoma
Pennsylvania (Drexel University) - Precursor T-cell lymphoblastic lymphoma
Puerto Rico (University of Puerto Rico) - Precursor T lymphoblastic lymphoma
San Francisco (SF Veterans Hospital) - T-cell lymphoblastic lymphoma
Texas, Crystal Beach - Lymphoblastic lymphoma T-cell type
Texas (Scott & White Memorial Hospital) - Lymphoblastic lymphoma
Wisconsin (St. Mary's Hospital) - Lymphoblastic lymphoma
Canada (Pasqua Hospital) - Lymphoblastic lymphoma
Canada (University of Sherbrooke) - T-cell lymphoblastic lymphoma
Japan (Asahi General Hospital) - Angioimmunoblastic lymphoma
Saudi Arabia (King Abdulaziz Medical Center) - Precursor T lymphoblastic lymphoma
Spain (Povisa) - Precursor T lymphoblastic lymphoma
United Kingdom (Oxford Study Group) - Lymphoblastic lymphoma

Case 10 - Diagnosis:

Precursor T-Cell lymphoblastic lymphoma (WHO classification), mediastinum
T-Y2320, M-96303

Outside Consultation: Jun Wang, M.D. (LLUMC): "Precursor T-cell lymphoblastic lymphoma (WHO classification)."

Case 10 - References:

Gorczyca W, Tugulea S, Liu Z, et al. Flow Cytometry in the Diagnosis of Mediastinal Tumors with Emphasis on Differentiating Thymocytes from Precursor T-Lymphoblastic Lymphoma/Leukemia. *Leuk Lymphoma* 2004; 45(3):529-538.

Lin YW, Nichols RA, Letterio JJ, et al. Notch1 Mutations Are Important for Leukemic Transformation in Murine Models of Presursor-T Leukemia/Lymphoma. *Blood* 2006; 107(6):2540-2543.

Onishi Y, Matsuno Y, et al. Two Entities of Precursor T-Cell Lymphoblastic Leukemia/Lymphoma Based on Radiologic and Immunophenotypic Findings. *Int J Heamtol* 2004; 80(1):43-51.

Han X, Bueso-Ramos CE, et al. Precursor T-Cell Acute Lymphoblastic Leukemia/lymphoblastic Lymphoma and Acute Biphenotypic Leukemias. *Am J Clin Pathol* 2007; 127(4):528-544.

Lin YW and Aplan PD. Gene Expression Profiling of Precursor T-Cell Lymphoblastic Leukemia/Lymphoma Identifies Oncogenic Pathways That Are Potential Therapeutic Targets. *Leukemia* 2007; 21(6):1276-1284.