1335

CALIFORNIA
TUMOR TISSUE REGISTRY

General Pathology
Study Cases, Subscription B

April, 2007

California Tumor Tissue Registry
c/o: Department of Pathology and Human Anatomy
Loma Linda University School of Medicine
11021 Campus Avenue, AH 335
Loma Linda, California 92350
(909) 558-4788
FAX: (909) 558-0188
E-mail: cttr@linkline.com
Web site & Case of the Month: www.cttr.org

Target audience:
Practicing pathologists and pathology residents.

Goal:
To acquaint the participant with the histologic features of a variety of benign and malignant neoplasms and tumor-like conditions.

Objectives:
The participant will be able to recognize morphologic features of a variety of benign and malignant neoplasms and tumor-like conditions and relate those processes to pertinent references in the medical literature.

Educational methods and media:
Review of representative glass slides with associated histories.
Feedback on consensus diagnoses from participating pathologists.
Listing of selected references from the medical literature.

Principal faculty:
Donald R. Chase, MD

CME Credit:
Loma Linda University School of Medicine designates this continuing medical education activity for up to 2 hours of Category I of the Physician's Recognition Award of the American Medical Association.
CME credit is offered for the subscription year only.

Accreditation:
Loma Linda University School of Medicine is accredited by the Accreditation Council for Continuing Medical Education (ACCME) to sponsor continuing medical education for physicians.

Contributor: Lester Thompson, M.D.
Woodland Hills, CA

Case No. 1 - April, 2007 B

Tissue from: Stomach

Accession #30270

Clinical Abstract:

An 88-year-old man presented with abdominal pain and a recent history of hemoptysis. Endoscopic examination revealed a submucosal polypoid projection in the region of the gastric body.

Gross Pathology:

The mass measured 4.8 cm in greatest dimension and showed focal surface ulceration.

Special Studies:

Positive: CD117 (strong/diffuse positivity).
Negative: S-100 protein, Smooth muscle actin, Desmin, Keratin.

Contributor: Loma Linda Pathology Group (rc)
Loma Linda, CA

Case No. 2 - April, 2007 B

Tissue from: Left breast

Accession #30378

Clinical Abstract:

An 84-year-old man consulted his physician after noticing a mass in his left breast.

Gross Pathology:

The 4 gram, 2.4 x 1.5 x 1.1 cm specimen consisted of yellow, lobulated tissue.

Contributor: Donovan Hare, M.D.
Redlands, CA

Case No. 3 - April, 2007 B

Tissue from: Left breast

Accession #30352

Clinical Abstract:

A 51-year-old woman presented with a mass in the left breast.

Gross Pathology:

The 1620 gram, 20 x 17 x 9.5 cm left mastectomy specimen included a 15 x 6 x 4.5 cm portion of axillary tail. A 5.0 x 4.0 x 3.0 cm stellate mass with a gritty cut surface was present in the upper mid-portion of the breast with an adjacent 2.5 cm area of hemorrhage. In the inferior-lateral portion of the breast there was a 3.5 x 2.5 x 2.5 cm hard, pale pink-tan tumor moderately demarcated from the surrounding breast tissue.

Special Studies:

ER/PR = borderline; HER2 = Negative.

Contributor: Julio Ibarra, M.D.
Fountain Valley, CA

Case No. 4 - April, 2007 B

Tissue from: Left breast & chest wall

Accession #30292

Clinical Abstract:

A 69-year-old woman presented with a hard mass located centrally within the left breast. She underwent a mastectomy and sentinel node dissection. The nodes were negative. After surgery she was found to have a 6 cm recurrence in the left chest wall.

Gross Pathology:

The 55 gram, 6.5 x 4.9 x 3.4 cm recurrence specimen consisted of a well-circumscribed, ovoid white tumor measuring 6.0 x 4.5 x 3.0 cm. The tumor had a white fibrous cut surface and focally extended to the surgical margin.

Special Studies:

Positive: Pan-keratin (diffusely positive).

Contributor: Robert Zuch, M.D.
Baldwin Park, CA

Case No. 5 - April, 2007 B

Tissue from: Left iliac bone & sacrum

Accession #30192

Clinical Abstract:

A large expansive mass was identified in the left iliac bone on CT and MRI scans in a 58-year-old woman.

Gross Pathology:

The hemipelvectomy specimen contained a 12 cm diameter tumor, apparently arising from the sacrum. The tumor showed a chocolate-brown, variegated almost honeycomb appearance throughout, and it cut with a gritty sensation.

Special Studies:

Positive: Smooth muscle actin; Muscle specific actin (weakly).
Negative: CD31, CD34, Factor VIII, Pancytokeratin, EMA.

Contributor: Jin Mei, M.D.
Hangzhou, China

Case No. 6 - April, 2007 B

Tissue from: Left femur

Accession #30327

Clinical Abstract:

A 40-year-old woman presented with pain in the left knee and thigh which had been present for approximately three months. During surgery, destruction of the proximal end and periosteum of the femur was noted.

Gross Pathology:

A 9.0 x 6.0 x 6.0 cm mass was seen at the metaphysis of the femur. It resulted in cortical destruction and an exophytic mass. The cut surface was gray-red and soft.

Contributor: Lester Thompson, M.D.
Woodland Hills, CA

Case No. 7 - April, 2007 B

Tissue from: Stomach

Accession #30224

Clinical Abstract:

A 54-year-old woman presented with complaints of dysphagia and a 70-pound weight loss over the course of the preceding 7 months. The dysphagia was accompanied by nausea, early satiety and episodic epigastric pain. On physical examination a mass was palpable in the left upper quadrant. Upper endoscopy showed a "cobblestone" appearance to the stomach.

Gross Pathology:

Unavailable.

Contributor: LLUMC Pathology (pjw)
Loma Linda, CA

Case No. 8 - April, 2007 B

Tissue from: Pancreatic body & tail

Accession #30254

Clinical Abstract:

This 48-year-old woman was found to have a mass in the distal pancreas.

Gross Pathology:

The 462 gram, 12.0 x 9.0 x 6.0 cm distal pancreas was almost completely replaced by tumor. The cut surface revealed a yellow-brown, focally necrotic, focally cystic parenchyma.

Special Studies:

Positive: Alpha-1-Antitrypsin (diffuse); Vimentin (diffuse); Synaptophysin (focal).
Negative: CAM 5.2; Chromogranin.

Contributor: Kenneth Frankel, M.D.
Glendale, CA

Case No. 9 - April, 2007 B

Tissue from: Pancreas

Accession #30256

Clinical Abstract:

A mass was identified in the pancreas of a 61-year-old person (gender not specified).

Gross Pathology:

The distal portion of pancreas and attached spleen measured 8.0 x 6.0 x 4.0 cm. Within the pancreas was a sharply circumscribed, 5.0 x 5.0 x 4.0 cm, lobulated, pink-gray mass with a central gray-white area of induration.

Contributor: Loma Linda Pathology Group (rc)
Loma Linda, CA

Case No. 10 - April, 2007 B

Tissue from: Mediastinum

Accession #30314

Clinical Abstract:

A 73-year-old male presented with chronic abdominal pain and weight loss of four months' duration. He also complained of having to "raise his head" in order to sleep, and stated that it felt like something was pressing on his chest. CT of the chest, abdomen and pelvis revealed a 4.2 x 2.6 x 4.4 cm retrosternal soft tissue mass.

Gross Pathology:

The 26.6 gram, 4.2 x 4.0 x 2.5 cm well circumscribed portion of brown-tan tissue had a pink to red to yellow-tan cut surface.

CALIFORNIA
TUMOR TISSUE REGISTRY

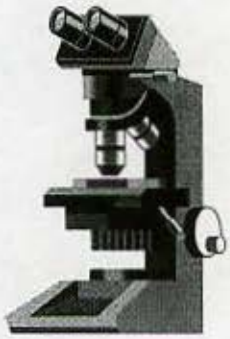

"General Pathology"

Minutes – Subscription B

April, 2007

SUGGESTED READING (General Topics from Recent Literature):

Expression of p63 in Thymomas and Normal Thymus. *Am J Clin Pathol* 2007; 127:415-420. Dotto J, Pelosi G and Rosai J.

Identification of a Basal-Like Subtype of Breast Ductal Carcinoma in Situ. *Hum Pathol* 2007; Livasy CA, Perou CM, et al.

Risk of Invasive Breast Carcinoma Among Women Diagnosed with Ductal Carcinoma In-Situ and Lobular Carcinoma In-Situ. *Cancer* 2006; 106:2104-2112.

Key Issues in Reporting Common Cancer Specimens. Problems in Pathologic Staging of Colon Cancer. *Arch Pathol Lab Med* 2006; Compton CC.

Repeat Thyroid Nodular Fine-Needle Aspiration in Patients with Initial Benign Cytologic Results. *Am J Clin Pathol* 2006; 125:698-702.

California Tumor Tissue Registry
c/o: Department of Pathology and Human Anatomy
Loma Linda University School of Medicine
11021 Campus Avenue, AH 335
Loma Linda, California 92350
(909) 558-4788
FAX: (909) 558-0188
E-mail: cttr@linkline.com
Web site & Case of the Month: www.cttr.org

FILE DIAGNOSES

(Preferably submitted on website at www.cttr.org. Click "subscriptions", then "submit answers.")

CTTR Subscription B

Case 1:
Gastrointestinal stromal tumor, stomach
T-63000, M-88903

Case 2:
Myofibroblastoma, breast
T-04000, M-88100

Case 3:
Invasive micropapillary ductal carcinoma, breast
T-04000, M-85003

Case 4:
Metaplastic (spindle cell) carcinoma, breast
T-04000, M-80232

Case 5:
Talangiectatic osteosarcoma, iliac bone
T-11339, M-91833

Case 6:
Low grade osteosarcoma (grade I of II), femur
T-11710, M-91803

Case 7:
Poorly differentiated (signet-ring) carcinoma, stomach
T-63000, M-84903

Case 8:
Solitary pseudopapillary tumor, pancreas
T-59000, M-03090

Case 9:
Serous microcystic adenoma, pancreas
T-59000, M-81400

Case 10:
Thymoma
T-Y2300, M-85800

Mountain View (El Camino Pathology) - Gastrointestinal stromal tumor
Orange (UCI Medical Center Residents) - Gastrointestinal stromal tumor
Sacramento (U.C. Davis Residents) - Gastrointestinal stromal tumor
San Diego (Naval Medical Center) - Gastrointestinal stromal tumor
San Diego (UCSD) - Gastrointestinal stromal tumor, malignant
Arkansas (University of Arkansas Medical Center) - Gastrointestinal stromal tumor, stomach
Georgia, Decatur - Gastrointestinal stromal tumor
Illinois (Heartland Regional Medical Center) - Gastrointestinal stromal tumor
Illinois (Loyola University Medical Center) - Gastrointestinal stromal tumor, low risk
Massachusetts (St. Mary's Hospital) - Gastrointestinal stromal tumor
Michigan (Pathology Services of West Michigan) - Gastrointestinal stromal tumor
Montana (Forensic Science Division) - Gastrointestinal stromal tumor
New York (Nassau University Medical Center) - Gastrointestinal stromal tumor
New York (Stony Brook University Hospital) - Gastrointestinal stromal tumor
New York (SUNY Downstate Medical Center) - Gastrointestinal stromal tumor, low malignant potential
North Carolina (Wake Forest University Medical Center) - Gastrointestinal stromal tumor
Ohio (Medical University of Ohio) - Gastrointestinal stromal tumor of low malignant potential
Oklahoma (Integris Baptist Medical Center) - Gastrointestinal stromal tumor
Pennsylvania (Drexel University College of Medicine) - Epithelioid gastrointestinal stromal tumor
Pennsylvania (Wilkes-Barre General Hospital) - Malignant gastro-intestinal stromal tumor (GIST)
Puerto Rico (University of Puerto Rico) - Gastrointestinal stromal tumor (GIST), probably high-grade
South Dakota (South Dakota Residents) - Gastrointestinal stromal tumor
Texas, Lubbock - Malignant gastrointestinal stromal tumor
Texas, San Antonio - Gastrointestinal stromal tumor
Texas, Sugarland - Gastrointestinal stromal tumor
Australia (Sullivan Nicolaides Pathology) - Gastrointestinal stromal tumor
Brazil (Lab Anat Pathol E Citol) - Gastrointestinal stromal tumor, with high risk aggressive behavior
Canada (Pasqua Hospital) - Gasatrointestinal stromal tumor
Canada (University Hospital of Sherbrooke) - Gastrointestinal stromal tumor
India, Karnataka - Vascular transformation of sinusoids
Japan (Asahi General Hospital) - Gastrointestinal stromal tumor, high grade
Japan (Gunma University Hospital) - Gastrointestinal stromal tumor, high risk
Japan (Hamamatsu University School of Medicine) - Gastrointestinal stromal tumor
Qatar (Hamad Medical Corporation) - Gastrointestinal stromal tumor
Saudi Arabia (King Fahad National Guard Hospital) - Gastrointestinal stromal tumor, intermediate risk
Spain (Povisa Hospital) - Gastrointestinal stromal tumor
United Kingdom (Oxford Study Group) - Gastrointestinal stromal tumor

Case 1 - Diagnosis:

Gastrointestinal stromal tumor, stomach
T-63000, M-88903

Case 1 - References:

Heinrich MC and Corless CL. Gastric GI Stromal Tumors (GISTs). The Role of Surgery in the Era of Targeted Therapy. *J Surg Oncol* 2005; 90(3):195-207.

Feakins RM. The Expression of p53 and bcl-2 in Gastrointestinal Stromal Tumours is Associated with Anatomical Site, and p53 Expression is Associated with Grade and Clinical Outcome. *Histopathol* 2005; 46(3):270-279.

Lesalnieks I, Rummele P, Dietmaier W, et al. Factors Associated with Disease Progression in Patients with Gastrointestinal Stromal Tumors in the Pre-Imatinib Era. *Am J Clin Pathol* 2005; 124(5):740-748.

Rossi G, Sartori G, Valli R, et al. The Value of C-Kit Mutational Analysis in a Cytokeratin Positive Gastrointestinal Stromal Tumour. *J Clin Pathol* 2005; 58(9):991-993.

Miettinen M, Sobin LH and Lasota J. Gastrointestinal Stromal Tumors of the Stomach. A Clinicopathologic, Immunohistochemical, and Molecular Genetic Study of 1765 Cases with Long-Term Follow-Up. *Am J Surg Pathol* 2005; 29(1):52-68.

Case No. 2 - Accession No. 30378 April, 2007 B

Mountain View (El Camino Pathology) - Myofibroblastoma
Orange (UCI Medical Center Residents) - Myofibroblastoma
Sacramento (U.C. Davis Residents) - Solitary fibrous tumor
San Diego (Naval Medical Center) - Myxoid myofibroblastoma
San Diego (UCSD) - Myofibroblastoma
Arkansas (University of Arkansas Medical Center) - Myofibroblastoma, male breast
Georgia, Decatur - Myofibroblastoma
Illinois (Heartland Regional Medical Center) - Spindle cell lipoma
Illinois (Loyola University Medical Center) - Myofibroblastoma
Massachusetts (St. Mary's Hospital) - Myofibroblastoma
Michigan (Pathology Services of West Michigan) - (Lipo?) sarcoma
Montana (Forensic Science Division) - Neurofibroma
New York (Nassau University Medical Center) - Myofibroblastoma
New York (Stony Brook University Hospital) - Myofibroblastoma
New York (SUNY Downstate Medical Center) - Myofibroblastoma
North Carolina (Wake Forest University Medical Center) - Glomus tumor
Oklahoma (Integris Baptist Medical Center) - Myofibroblastoma
Pennsylvania (Drexel University College of Medicine) - Myofibroblastoma
Pennsylvania (Wilkes-Barre General Hospital) - Smooth muscle tumor, undertermined malignant potential
Puerto Rico (University of Puerto Rico) - Myofibroblastoma
South Dakota (South Dakota Residents) - Fibromatosis
Texas, Lubbock - Spindle cell lipoma
Texas, San Antonio - Myofibroblastoma
Texas, Sugarland - Myofibroblastoma
Australia (Sullivan Nicolaides Pathology) - Myofibroblastoma
Brazil (Lab Anat Pathol E Citol) - Myofibroblastoma
Canada (Pasqua Hospital) - Myofibroblastoma
Canada (University Hospital of Sherbrooke) - Myofibroblastoma
India, Karnataka - Myeloid sarcoma
Japan (Asahi General Hospital) - Myofibroblastoma
Japan (Gunma University Hospital) - Myofibroblastoma, breast
Japan (Hamamatsu University School of Medicine) - Myofibroblastoma
Qatar (Hamad Medical Corporation) - Myofibroblastoma
Saudi Arabia (King Fahad National Guard Hospital) - Benign spindle cell tumor, favoring benign fibrous histiocytoma
Spain (Povisa Hospital) - Myofibroblastoma
United Kingdom (Oxford Study Group) - Myofibroblastoma, breast

Case 2 - Diagnosis:

Myofibroblastoma, breast
T-04000, M-88100

Case 2 - References:

Magro G, Gurrera A and Bisceglia M. H-Caldesmon Expression in Myofibroblastoma of the Breast. Evidence Supporting the Distinction from Leiomyoma. *Histopathol* 2003; 42(3):233-238.

Powari M, Srinivasan R and Radotra BD. Myofibroblastoma of the Male Breast. A Diagnostic Problem on Fine-Needle Aspiration Cytology. *Diagn Cytopathol* 2002; 26(5):290-293.

Odashiro AN, Adashiro Miiji LN, Odashiro DN, et al. Mammary Myofibroblastoma. Report of Two Cases with Fine-Needle Aspiration Cytology and Review of the Cytology Literature. *Diagn Cytopathol* 2004; 30(6):406-410.

McMenamin ME and Fletcher CD. Mammary-Type Myofibroblastoma of Soft Tissue. A Tumor Closely Related to Spindle Cell Lipoma. *Am J Surg Pathol* 2001 25(8):1022-1029.

Dockery WD, Singh HR and Wilentz RE. Myofibroblastoma of the Male Breast. Imaging Appearance and Ultrasound-Guided Core Biopsy Diagnosis. *Breast J* 2001; 7(3):192-194.

Case No. 3 - Accession No. 30352 April, 2007 B

Mountain View (El Camino Pathology) - Metastatic ovarian carcinoma vs. micropapillary carcinoma of breast
Orange (UCI Medical Center Residents) - Invasive micropapillary carcinoma
Sacramento (U.C. Davis Residents) - Cystic papillary carcinoma
San Diego (Naval Medical Center) - Invasive ductal carcinoma, micropapillary variant

San Diego (UCSD) - Infiltrating duct carcinoma, micropapillary type with extensive lymphatic invasion
Arkansas (University of Arkansas Medical Center) - Lymphagitic carcinomatosis, breast
Georgia, Decatur - Invasive micropapillary carcinoma
Illinois (Heartland Regional Medical Center) - Invasive micropapillary carcinoma
Illinois (Loyola University Medical Center) - Invasive micropapillary carcinoma
Massachusetts (St. Mary's Hospital) - Invasive micropapillary carcinoma
Michigan (Pathology Services of West Michigan) - Papillary adenocarcinoma
Montana (Forensic Science Division) - Invasive micropapillary carcinoma
New York (Nassau University Medical Center) - Invasive ductal carcinoma, papillary
New York (Stony Brook University Hospital) - Invasive micropapillary breast carcinoma (r/o gyn metastatic carcinoma)
New York (SUNY Downstate Medical Center) - Invasive micropapillary carcinoma of breast
North Carolina (Wake Forest University Medical Center) - Invasive micropapillary ductal carcinoma
Ohio (Medical University of Ohio) - Micropapillary carcinoma
Oklahoma (Integris Baptist Medical Center) - Micropapillary carcinoma, in situ and invasive
Pennsylvania (Drexel University College of Medicine) - Invasive micro-papillary carcinoma
Pennsylvania (Wilkes-Barre General Hospital) - Invasive ductal carcinoma, micro-papillary type
Puerto Rico (University of Puerto Rico) - Acinic cell carcinoma/invasive micropapillary carcinoma
South Dakota (South Dakota Residents) - Invasive micropapillary carcinoma
Texas, Lubbock - Papillary carcinoma
Texas, San Antonio - Invasive micropapillary carcinoma
Texas, Sugarland - Invasive micropapillary carcinoma
Australia (Sullivan Nicolaides Pathology) - Invasive micropapillary carcinoma of breast
Brazil (Lab Anat Pathol E Citol) - Invasive micropapillary carcinoma
Canada (Pasqua Hospital) - Invasive duct carcinoma, micropapillary pattern
Canada (University Hospital of Sherbrooke) - Micropapillary breast ductal invasive carcinoma
India, Karnataka - Hodgkin nodular sclerosis
Japan (Asahi General Hospital) - Invasive micropapillary carcinoma
Japan (Gunma University Hospital) - Invasive micropapillary carcinoma, breast
Japan (Hamamatsu University School of Medicine) - Invasive micropapillary carcinoma
Qatar (Hamad Medical Corporation) - Invasive ductal mammary carcinoma with extensive lymphovascular permeation
Saudi Arabia (King Fahad National Guard Hospital) - Micropapillary carcinoma
Spain (Povisa Hospital) - Invasive micropapillary carcinoma
United Kingdom (Oxford Study Group) - Micropapillary carcinoma, breast

Case 3 - Diagnosis:

Invasive micropapillary ductal carcinoma, breast
T-04000, M-85003

Case 3 - References:

Jaffer S, Reid-Nicholson M and Bleiweiss IJ. Infiltrating Micropapillary Carcinoma of the Breast. *Acta Cytol* 2002; 46(6):1081-1087.

Zebioglu O, Erhan Y, Ciris M, et al. Invasive Micropapillary Carcinoma of the Breast. High Incidence of Lymph Node Metastasis with Extranodal Extension and Its Immunohitochemical Profile Compared with Invasive Ductal Carcinoma. *Histopathol:* 2004; 44(1):18-23.

Gong Y, Sun X, Huo L, Wiley EL, et al. Expression of Cell Adhesion Molecules, CD44s and E-Cadherin, and Microvessel Density in Invasive Micropapillary Carcinoma of the Breast. *Histopathol* 2005; 46(1):24-30.

Thor AD, Eng C, Devries S, et al. Invasive Micropapillary Carcinoma of the Breast is Associated with Chromosome 8 Abnormalities Detected by Comparative Genomic Hybridization. *Hum Pathol* 2002; 33(6):628-631.

Walsh MM and Bleiweiss IJ. Invasive Micropapillary Carcinoma of the Breast. Eighty Cases of an Underrecognized Entity. *Hum Pathol* 2001; 583-589.

Case No. 4 - Accession No. 30292 April, 2007 B

Mountain View (El Camino Pathology) - Sarcomatoid (metaplastic) carcinoma
Orange (UCI Medical Center Residents) - Metaplastic carcinoma
Sacramento (U.C. Davis Residents) - Metaplastic carcinoma
San Diego (Naval Medical Center) - Poorly differentiated carcinoma
San Diego (UCSD) - Sarcomatoid carcinoma
Arkansas (University of Arkansas Medical Center) - Metaplastic (pseudosarcomatous) carcinoma, breast
Georgia, Decatur - Poorly differentiated epithelioid tumor, consistent with recurrent breast carcinoma

Illinois (Heartland Regional Medical Center) - Spindle cell (sarcomatoid) carcinoma consistent with breast origin
Illinois (Loyola University Medical Center) - Metaplastic carcinoma
Massachusetts (St. Mary's Hospital) - Metaplastic carcinoma
Michigan (Pathology Services of West Michigan) - Infiltrating ductal carcinoma
Montana (Forensic Science Division) - Metaplastic carcinoma
New York (Nassau University Medical Center) - Invasive spindle cell carcinoma
New York (Stony Brook University Hospital) - Metaplastic carcinoma associated with eosinophils
New York (SUNY Downstate Medical Center) - Metaplastic carcinoma of breast
North Carolina (Wake Forest University Medical Center) - Metaplastic carcinoma
Ohio (Medical University of Ohio) - Recurrent infiltrating ductal carcinoma
Oklahoma (Integris Baptist Medical Center) - Metaplastic carcinoma
Pennsylvania (Drexel University College of Medicine) - Metaplastic carcinoma
Pennsylvania (Wilkes-Barre General Hospital) - Metaplastic carcinoma
Puerto Rico (University of Puerto Rico) - Metaplastic carcinoma, spindle cell variant
South Dakota (South Dakota Residents) - Metaplastic carcinoma
Texas, Lubbock - Metaplastic carcinoma
Texas, San Antonio - Invasive sarcomatoid (metaplastic) carcinoma
Texas, Sugarland - Carcinosarcoma
Australia (Sullivan Nicolaides Pathology) - Metaplastic carcinoma of breast
Brazil (Lab Anat Pathol E Citol) - High grade sarcomatoid (metaplastic) carcinoma
Canada (Pasqua Hospital) - Metaplastic carcinoma
Canada (University Hospital of Sherbrooke) - Metaplastic carcinoma
India, Karnataka - MALToma marginal zone lymphoma
Japan (Asahi General Hospital) - Medullary carcinoma
Japan (Gunma University Hospital) - Metaplastic carcinoma, spindle cell type, breast
Japan (Hamamatsu University School of Medicine) - Spindle cell carcinoma
Qatar (Hamad Medical Corporation) - Metaplastic carcinoma of the breast with areas of possible osteoid formation
Saudi Arabia (King Fahad National Guard Hospital) - Spindle cell carcinoma
Spain (Povisa Hospital) - Sarcomatoid invasive carcinoma
United Kingdom (Oxford Study Group) - Spindle cell carcinoma (metaplastic), breast

Case 4 - Diagnosis:

Metaplastic (spindle cell) carcinoma, breast
T-04000, M-80323

Outside Consultation: Christopher Fletcher, M.D.; Brigham & Women's Hospital: "Metaplastic (spindle cell) carcinoma, breast."

Director's Note: Dr. Fletcher indicated that approximately 50% of these tumors metastasize within 2-3 years, despite being "uniformly" negative for sentinel node involvement. (drc)

Case 4 - References:

Koker MM and Kleer CG. P63 Expression in Breast Cancer. A Highly Sensitive and Specific Marker of Metaplastic Carcinoma. *Am J Surg Pathol* 2004; 28(11):1506-1512.

Adem C, Reynolds C, Adlakha H, et al. Wide Spectrum Screening Keratin as a Marker of Metaplastic Spindle Cell Carcinoma of the Breast. An Immunohistochemical Study of 24 Patients. *Histopathol* 2002; 40(6):556-562.

Davis WG, Hennessy B, Babiera G, et al. Metaplastic Sarcomatoid Carcinoma of the Breast with Absent or Minimal Overt Invasive Carcinomatous Component. A Misnomer. *Am J Surg Pathol* 2005; 29(11):1456-1463.

Lien HC, Lin CW, Mao TL, et al. p53 Overexpression and Mutation in Metaplastic Carcinoma of the Breast. Genetic Evidence for a Monoclonal Origin of Both the Carcinomatous and the Heterogeneous Sarcomatous Components. *J Pathol* 2004; 204(2):131-139.

Leibl S and Moinfar F. Metaplastic Breast Carcinomas are Negative for Her-2 but Frequently Express EGFR (Her-1). Potential Relevance to Adjuvant Treatment with EGFR Tyrosine Kinase Inhibitors? *J Clin Pathol* 2005; 58(7):700-704.

Kurian KM and Al-Nafussi A. Sarcomatoid/Metaplastic Carcinoma of the Breast. A Clinicopathological Study of 12 Cases. *Histopathol* 2002; 42(1):94-95.

Case No. 5 - Accession No. 30192 April, 2007 B

Mountain View (El Camino Pathology) - Telangiectatic osteosarcoma
Orange (UCI Medical Center Residents) - Telangiectatic osteosarcoma
Sacramento (U.C. Davis Residents) - Telangiectatic osteosarcoma vs. cavernous hemangioma
San Diego (Naval Medical Center) - Telangiectatic osteosarcoma
San Diego (UCSD) - Telangiectatic osteosarcoma
Arkansas (University of Arkansas Medical Center) - Osteosarcoma, telangiectatic type, bone
Georgia, Decatur - Osteosarcoma, telangiectatic variant
Illinois (Heartland Regional Medical Center) - Telangiectatic osteosarcoma
Illinois (Loyola University Medical Center) - Telangiectatic osteosarcoma
Massachusetts (St. Mary's Hospital) - Telangiectatic osteosarcoma
Michigan (Pathology Services of West Michigan) - Telangiectatic osteosarcoma
Montana (Forensic Science Division) - Osteosarcoma
New York (Nassau University Medical Center) - Telangiectatic osteosarcoma
New York (Stony Brook University Hospital) - Telangiectatic osteosarcoma
New York (SUNY Downstate Medical Center) - Telangiectatic osteosarcoma
North Carolina (Wake Forest University Medical Center) - Telangiectatic osteosarcoma
Ohio (Medical University of Ohio) - Telangiectatic osteosarcoma
Oklahoma (Integris Baptist Medical Center) - Aneurysmal bone cyst
Pennsylvania (Drexel University College of Medicine) - Leiomyosarcoma of bone with secondary aneurysmal bone cyst
Pennsylvania (Wilkes-Barre General Hospital) - Telangiectatic osteosarcoma
Puerto Rico (University of Puerto Rico) - Aneurysmal bone cyst cannot exclude telangiectatic osteosarcoma
South Dakota (South Dakota Residents) - Telangietatic osteosarcoma
Texas, Lubbock - Aneurysmal bone cyst
Texas, San Antonio - Telangiectatic osteosarcoma
Texas, Sugarland - Telangietatic osteosarcoma
Australia (Sullivan Nicolaides Pathology) - Telangiectatic osteosarcoma
Brazil (Lab Anat Pathol E Citol) - Telangiectatic osteosarcoma
Canada (Pasqua Hospital) - Aneurismal bone cyst
Canada (University Hospital of Sherbrooke) - Telangiectatic osteosarcoma
India, Karnataka - Nodal marginal zone lymphoma
Japan (Asahi General Hospital) - Simple cyst
Japan (Gunma University Hospital) - Aneurysmal bone cyst
Japan (Hamamatsu University School of Medicine) - Giant cell tumor
Qatar (Hamad Medical Corporation) - Leiomyosarcoma (pleomorphic) with areas of osteoid formation and secondary aneurismal bone cyst formation
Saudi Arabia (King Fahad National Guard Hospital) - Aneurysmal bone cyst
Spain (Povisa Hospital) - Aneurysmal bone cyst
United Kingdom (Oxford Study Group) - Aneurysmal bone cyst

Case 5 - Diagnosis:

Telangiectatic osteosarcoma, iliac bone
T-11339, M-91833

Case 5 - References:

Murphey MD, wan Jaovisidha S, Temple HT, et al. Telangiectatic Osteosarcoma. Radiologic-Pathologic Comparison. *Radiol* 2003; 229(2):545-553.

Radhi JM and Loewy J. Dedifferentiated Chondrosarcoma with Features of Telangiectatic Osteosarcoma. *Pathol* 1999; 31(4):428-430.

Angervall L, Persson S, Stenman G, et al. Large Cell, Epithelioid, Telangiectatic Osteoblastoma. A Unique Pseudosarcomatous Variant of Osteoblastoma. *Hum Pathol* 1999; 30(10):1254-1259.

Graadt van Roggen JF, Zonderland HM, et al. Local Recurrence of a Phyllodes Tumour of the Breast Presenting with Widespread Differentiation to a Telangiectatic Osteosarcoma. *J Clin Pathol* 1998; 51(9):706-708.

Merino S, Arrazola J, Saiz A, et al. Post-Paget Telangiectatic Osteosarcoma of the Skull. *Skeletal Radiol* 1999; 28(8):470-472.

Case No. 6 - Accession No. 30327 April, 2007 B

Mountain View (El Camino Pathology) - Epithelioid osteosarcoma
Orange (UCI Medical Center Residents) - Malignant giant cell tumor
Sacramento (U.C. Davis Residents) - Giant cell tumor of bone

San Diego (Naval Medical Center) - Poorly differentiated neoplasm
San Diego (UCSD) - High grade epithelioid malignancy
Arkansas (University of Arkansas Medical Center) - Giant cell tumor of bone, femur
Georgia, Decatur - Metastatic malignant tumor, rule out melanoma, metastatic carcinoma
Illinois (Heartland Regional Medical Center) - Osteosarcoma, poorly differentiated
Illinois (Loyola University Medical Center) - Epithelioid osteosarcoma
Massachusetts (St. Mary's Hospital) - Alveolar soft part sarcoma
Michigan (Pathology Services of West Michigan) - Sarcoma
Montana (Forensic Science Division) - Giant cell tumor
New York (Nassau University Medical Center) - Malignant giant cell tumor
New York (Stony Brook University Hospital) - High grade sarcoma (small cell osteosarcoma)
New York (SUNY Downstate Medical Center) - Alveolar soft part sarcoma
North Carolina (Wake Forest University Medical Center) - Malignant giant cell tumor
Oklahoma (Integris Baptist Medical Center) - Giant cell tumor
Pennsylvania (Drexel University College of Medicine) - Osteosarcoma
Pennsylvania (Wilkes-Barre General Hospital) - Osteoblastoma
Puerto Rico (University of Puerto Rico) - Osteosarcoma/metastatic tumor (melanoma?)
South Dakota (South Dakota Residents) - Melanoma
Texas, Lubbock - Osteosarcoma
Texas, San Antonio - Giant cell tumor of bone
Texas, Sugarland - Osteosarcoma
Australia (Sullivan Nicolaides Pathology) - Malignant giant cell tumour
Brazil (Lab Anat Pathol E Citol) - Conventional osteosarcoma (1); Malignant giant cell tumor (1)
Canada (Pasqua Hospital) - Osteosarcoma
Canada (University Hospital of Sherbrooke) - PNET/Ewing's sarcoma
India, Karnataka - Large cell lymphoma
Japan (Asahi General Hospital) - Giant cell tumor
Japan (Gunma University Hospital) - Metastatic carcinoma of femur
Japan (Hamamatsu University School of Medicine) - Large cell carcinoma, metastatic
Qatar (Hamad Medical Corporation) - Alveolar soft part sarcoma
Saudi Arabia (King Fahad National Guard Hospital) - Malignant giant cell tumor
Spain (Povisa Hospital) - Giant cell tumor
United Kingdom (Oxford Study Group) - Clear cell sarcoma of soft parts (4); Metastatic melanoma (3)

Case 6 - Diagnosis:

Low grade osteosarcoma (grade I of III), femur
T-11710, M-91803

Director's Note: We understand that this was a painful neoplasm which had been noticed for approximately three months, and that it resulted in cortical destruction and an exophytic mass. Although we agree with the initial diagnosis of osteosarcoma, this is not a typical variety. The patient is older than most, and there is only a small amount of osteoid that is deposited. Of some curiosity are the large numbers of giant cells. A giant cell tumor of the femur could result in cortical destruction, however, by definition these occur in the epiphysis, and not in the metaphysis. In light of this, we feel that this is a relatively low-grade osteosarcoma (Grade I of III). (drc)

Case 6 - References:

Antonescu CR and Huvos AG. Low-Grade Osteogenic Sarcoma Arising in Medullary and Surface Osseous Locations. *Am J Clin Pathol* 2000; 114 Suppl pS90-103.

Radig K, Schneider-Stock R, Haeckel C, et al. p53 Gene Mutations in Osteosarcomas of Low-Grade Malignancy. *Hum Pathol* 1998; 29(11):1310-1316.

Ogose A, Hotta T, Emura I, et al. Repeated Dedifferentiation of Low-Grade Intraosseous Osteosarcoma. *Hum Pathol* 2000; 31(5):615-618.

Grubb G, Hoctor V, Venter D, et al. Inversion (6)p23q15) as the Sole Anomaly in a Low-Grade Intraosseous Osteosarcoma. *Cancer Genet Cytogenet* 1999; 109(1):70-71.

Okada K, Nishida J, Morita T, et al. Low-Grade Intraosseous Osteosarcoma in Northern Japan. Advantage of AgNOR and MIB-1 Staining in Differential Diagnosis. *Hum Pathol* 2000; 31(6):633-639.

Mountain View (El Camino Pathology) - Poorly differentiated adenocarcinoma, "linitis plastica"
Orange (UCI Medical Center Residents) - Signet ring cell carcinoma
Sacramento (U.C. Davis Residents) - Poorly differentiated carcinoma
San Diego (Naval Medical Center) - Diffuse gastric carcinoma
San Diego (UCSD) - Linitis plastica (signet ring carcinoma)
Arkansas (University of Arkansas Medical Center) - Signet ring cell adenocarcinoma, diffusely infiltrative, stomach
Georgia, Decatur - Gastric adenocarcinoma, diffuse type
Illinois (Heartland Regional Medical Center) - Invasive poorly differentiated adenocarcinoma
Illinois (Loyola University Medical Center) - Signet-ring cell adenocarcinoma
Massachusetts (St. Mary's Hospital) - Gastric adenocarcinoma
Michigan (Pathology Services of West Michigan) - Adenocarcinoma
Montana (Forensic Science Division) - Signet ring cell adenocarcinoma
New York (Nassau University Medical Center) - Signet ring adenocarcinoma, invasive
New York (Stony Brook University Hospital) - Poorly differentiated adenocarcinoma
New York (SUNY Downstate Medical Center) - Diffuse type adenocarcinoma of stomach
North Carolina (Wake Forest University Medical Center) - Signet ring cell carcinoma
Ohio (Medical University of Ohio) - Poorly differentiated carcinoma
Oklahoma (Integris Baptist Medical Center) - Signet ring adenocarcinoma
Pennsylvania (Drexel University College of Medicine) - Signet ring cell carcinoma
Pennsylvania (Wilkes-Barre General Hospital) - Diffuse poorly differentiated adenocarcinoma (linitis plastica)
Puerto Rico (University of Puerto Rico) - High grade adenocarcinoma, diffuse (signet ring cell) type cannot exclude concurrent large cell lymphoma
South Dakota (South Dakota Residents) - Poorly differentiated gastric adenocarcinoma
Texas, Lubbock - Adenocarcinoma
Texas, San Antonio - Invasive poorly differentiated carcinoma, favor diffuse gastric adenocarcinoma, rule out met
Texas, Sugarland - Poorly differentiated adenocarcinoma
Australia (Sullivan Nicolaides Pathology) - Diffuse gastric adenocarcinoma
Brazil (Lab Anat Pathol E Citol) - Gastric adenocarcinoma, diffuse-type
Canada (Pasqua Hospital) - Neoplasm with diffuse gastric cancer pattern
Canada (University Hospital of Sherbrooke) - Diffuse gastric carcinoma (signet ring cell type)
India, Karnataka - Inflammatory pseudotumor
Japan (Asahi General Hospital) - Scirrhous carcinoma
Japan (Gunma University Hospital) - Poorly differentiated adenocarcinoma, stomach
Japan (Hamamatsu University School of Medicine) - Poorly differentiated adenocarcinoma
Qatar (Hamad Medical Corporation) - Gastric carcinoma, diffuse type
Saudi Arabia (King Fahad National Guard Hospital) - Infiltrating poorly differentiated carcinoma
Spain (Povisa Hospital) - Diffuse undifferentiated carcinoma
United Kingdom (Oxford Study Group) - Diffuse infiltrating adenocarcinoma, stomach

Case 7 - Diagnosis:

Poorly differentiated (signet-ring) carcinoma, stomach
T-63000, M-84903

Case 7 - References:

Yokota T, Kunii Y, Teshima S, et al. Signet Ring Cell Carcinoma of the Stomach. A Clinicopathological Comparison with the Other Histological Types. *Tohoku J Exp Med* 1998; 186(2):121-130.

Briest S, Horn LC, Haupt R, et al. Metastasizing Signet Ring Cell Carcinoma of the Stomach-Mimicking Bilateral Inflammatory Breast Cancer. *Gynecol Oncol* 1999; 74(3):491-494.

Morii S, Oka K, Hakozaki H, et al. CEA-Producing Mucin-Negative Gastric Signet-Ring Cell Carcinoma with Neuroendocrine Markers. A Case Report. *J Clin Gastroenterol* 1999; 29(1):82-85.

Otsuji E, Yamaguchi T, Sawai K, et al. Characterization of Signet Ring Cell Carcinoma of the Stomach. *J Surg Oncol* 1998; 67(4):216-220.

Zamboni G, Franzin G, Scarpa A, et al. Carcinoma-Like Signet-Ring Cells in Gastric Mucosa-Associated Lymphoid Tissue (MALT) Lymphoma. *Am J Surg Pathol* 1996; 20(5):588-598.

Mountain View (El Camino Pathology) - Solid-cystic papillary neoplasm
Orange (UCI Medical Center Residents) - Solid pseudopapillary tumor
Sacramento (U.C. Davis Residents) - Solid psudopapillary tumor
San Diego (Naval Medical Center) - Solid pseudopapillary tumor
San Diego (UCSD) - Acinar cell carcinoma
Arkansas (University of Arkansas Medical Center) - Solid pseudopapillary tumor, pancreas
Georgia, Decatur - Solid pseudopapillary tumor
Illinois (Heartland Regional Medical Center) - Solid pseudopapillary tumor
Illinois (Loyola University Medical Center) - Solid pseudopapillary neoplasm
Massachusetts (St. Mary's Hospital) - Acinic cell carcinoma
Michigan (Pathology Services of West Michigan) - Solid pseudopapillary tumor
Montana (Forensic Science Division) - Endocrine cell tumor
New York (Nassau University Medical Center) - Acinic adenocarcinoma
New York (Stony Brook University Hospital) - Solid pseudopapillary neoplasm
New York (SUNY Downstate Medical Center) - Solid pseudopapillary tumor
North Carolina (Wake Forest University Medical Center) - Solid cystic pseudopapillary tumor
Ohio (Medical University of Ohio) - Solid cystic papillary epithelial neoplasm
Oklahoma (Integris Baptist Medical Center) - Solid pseudopapillary tumor
Pennsylvania (Drexel University College of Medicine) - Solid pseudopapillary tumor
Pennsylvania (Wilkes-Barre General Hospital) - Papillary cystic neoplasm, pancreas
Puerto Rico (University of Puerto Rico) - Solid pseudopapillary tumor
South Dakota (South Dakota Residents) - Solid pseudopapillary tumor of pancreas
Texas, Lubbock - Islet cell tumor
Texas, San Antonio - Solid pseudopapillary tumor
Texas, Sugarland - Solid pseudopapillary tumor
Australia (Sullivan Nicolaides Pathology) - Solid pseudopapillary neoplasm, pancreas
Brazil (Lab Anat Pathol E Citol) - Solid pseudopapillary tumor
Canada (Pasqua Hospital) - Solid pseudopapillary tumor
Canada (University Hospital of Sherbrooke) - Solid pseudopapillary tumor
India, Karnataka - Melanoma mets
Japan (Asahi General Hospital) - Solid-pseudopapillary neoplasm
Japan (Gunma University Hospital) - Solid pseudopapillary tumor, pancreas
Japan (Hamamatsu University School of Medicine) - Solid pseudopapillary tumor
Qatar (Hamad Medical Corporation) - Solid pseudopapillary tumor of the pancreas
Saudi Arabia (King Fahad National Guard Hospital) - Solid-cystic pseudopapillary tumor
Spain (Povisa Hospital) - Solid pseudopapillary tumor
United Kingdom (Oxford Study Group) - Solid pseudopapillary tumor, pancreas

Case 8 - Diagnosis:

Solitary pseudopapillary tumor, pancreas
T-59000, M-03090

Case 8 - References:

Piatek S, Manger T, Rose I, et al. Solid Pseudopapillary Tumor of the Pancreas. *Int J Pancreatol* 2000; 27(1):77-81.

Notohara K, Hamazaki S, Tsukayama C, et al. Solid-Pseudopapillary Tumor of the Pancreas. Immunohistochemical Localization of Neuroendocrine Markers and CD10. *Am J Surg Pathol* 2000; 24(10):1361-1371.

Mancini GJ, Dudrick PS, Grindstaff AD, et al. Solid-Pseudopapillary Tumor of the Pancreas. Two Cases in Male Patients. *Am Surg* 2004; 70(1):29-31.

Pettinato G, Di Vizio D, Manivel JC, et al. Solid Pseudopapillary Tumor of the Pancreas. A Neoplasm with Distinct and Highly Characteristic Cytological Features. *Diagn Cytopathol* 2002; 27(6):325-334.

Tang LH, Aydin H, Brennan MF, et al. Clinically Aggressive Solid Pseudopapillary Tumors of the Pancreas. A Report of Two Cases with Components of Undifferentiated Carcinoma and a Comparative Clinicopathologic Analysis of 34 Conventionl Cases. *Am J Surg Pathol* 2005; 29(4):512-519.

Abraham SC, Klimstra DS, Wilentz RE, Yeo CJ, et al. Solid-Pseudopapillary Tumors of the Pancreas are Genetically Distinct from Pancreatic Ductal Adenocarcinomas and Almost Always Harbor Beta-Caterin Mutations. *Am J Pathol* 2002; 160(4):1361-1369.

Mountain View (El Camino Pathology) - Serous (glycogen-rich) cystadenoma
Orange (UCI Medical Center Residents) - Serous cystadenoma
Sacramento (U.C. Davis Residents) - Serous cystadenoma
San Diego (Naval Medical Center) - Serous microcystic adenoma
San Diego (UCSD) - Microcystic serous cystadenoma
Arkansas (University of Arkansas Medical Center) - Serous microcystic adenoma, pancreas
Georgia, Decatur - Serous/microcystic adenoma
Illinois (Heartland Regional Medical Center) - Serous microcystic adenoma
Illinois (Loyola University Medical Center) - Microcystic adenoma
Massachusetts (St. Mary's Hospital) - Microcystic serous cystadenoma
Michigan (Pathology Services of West Michigan) - Serous microcystic adenoma
Montana (Forensic Science Division) - Serous microcystic tumor
New York (Nassau University Medical Center) - Serous cystadenoma
New York (Stony Brook University Hospital) - Serous cyst adenoma
New York (SUNY Downstate Medical Center) - Serous cystadenoma of pancreas
North Carolina (Wake Forest University Medical Center) - Serous microcystic adenoma
Ohio (Medical University of Ohio) - Serous microcystic neoplasm
Oklahoma (Integris Baptist Medical Center) - Microcystic serous cystadenoma
Pennsylvania (Drexel University College of Medicine) - Serous microcystic adenoma
Pennsylvania (Wilkes-Barre General Hospital) - Serous cystadenoma, pancreas
Puerto Rico (University of Puerto Rico) - Microcystic cystadenoma
South Dakota (South Dakota Residents) - Microcystic serous cystadenoma
Texas, Lubbock - Microcystic adenoma
Texas, San Antonio - Microcystic serous cystadenoma
Texas, Sugarland - Serous microcystic adenoma
Australia (Sullivan Nicolaides Pathology) - Serous microcystic adenoma, pancreas
Brazil (Lab Anat Pathol E Citol) - Microcystic serous cystadenoma
Canada (Pasqua Hospital) - Microcystic adenoma
Canada (University Hospital of Sherbrooke) - Serous microcystic adenoma
India, Karnataka - Follicular center lymphoma
Japan (Asahi General Hospital) - Serous microcystic adenoma
Japan (Gunma University Hospital) - Serous cystadenoma, pancreas
Japan (Hamamatsu University School of Medicine) - Serous microcystic adenoma
Qatar (Hamad Medical Corporation) - Microcystic cystadenoma of the pancreas
Saudi Arabia (King Fahad National Guard Hospital) - Serous cystadenoma
Spain (Povisa Hospital) - Serous microcystic adenoma
United Kingdom (Oxford Study Group) - Microcystic adenoma (serous cystadenoma), pancreas

Case 9 - Diagnosis:

Serous microcystic adenoma, pancreas
T-59000, M-81400

Case 9 - References:

Omeroglu A, Paner GP, Ciesla MC, et al. Serous Microcystic Adenoma of the Pancreas. *Arch Pathol Lab Med* 2001; 125(12):1613-1614.

Kosmahl M, Wagner J, Peters K, et al. Serous Cystic Neoplasms of the Pancreas. An Immunohistochemical Analysis Revealing Alpha-Inhibin, Neuro-Specific Enolase, and MUC6 as New Markers. *Am J Surg Pathol* 2004; 28(3):339-346.

Lai A, Bourtsos EP, De Frias DV, et al. Microcystic Adenoma of the Pancreas. Clinical, Radiologic, and Cytologic Features. *Cancer* 2004; 102(5):288-294.

Yasuhara Y, Sakaida N, Uemura Y, et al. Serous Microcystic Adenoma (Glycogen-Rich Cystadenoma) of the Pancreas. Study of 11 Cases Showing Clinicopathological and Immunohistochemical Correlations. *Pathol Int* 2002; 52(4):307-312.

Mountain View (El Camino Pathology) - Thymoma (invasive?)
Orange (UCI Medical Center Residents) - Thymoma
Sacramento (U.C. Davis Residents) - Thymoma
San Diego (Naval Medical Center) - Thymoma, type AB
San Diego (UCSD) - Thymoma (mixed pattern, type AB)
Arkansas (University of Arkansas Medical Center) - Thymoma, thymus
Georgia, Decatur - Well-differentiated thymic invasion
Illinois (Heartland Regional Medical Center) - Thymoma, encapsulated
Illinois (Loyola University Medical Center) - Spindle cell thymoma
Massachusetts (St. Mary's Hospital) - Thymoma
Michigan (Pathology Services of West Michigan) - Thymoma
Montana (Forensic Science Division) - Thymoma
New York (Nassau University Medical Center) - Thymoma
New York (Stony Brook University Hospital) - Spindle cell thymoma (vs. juvenile granulose cell tumor)
New York (SUNY Downstate Medical Center) - Thymoma, type AB
North Carolina (Wake Forest University Medical Center) - Type AB thymoma
Ohio (Medical University of Ohio) - Malignant thymoma
Oklahoma (Integris Baptist Medical Center) - Thymoma, type A
Pennsylvania (Drexel University College of Medicine) - Thymoma, type A
Pennsylvania (Wilkes-Barre General Hospital) - Thymoma
Puerto Rico (University of Puerto Rico) - Thymoma
South Dakota (South Dakota Residents) - Thymoma
Texas, Lubbock - Thymoma
Texas, San Antonio - Thymoma
Texas, Sugarland - Thymoma
Australia (Sullivan Nicolaides Pathology) - Invasive thymoma, type AB
Brazil (Lab Anat Pathol E Citol) - Type AB, thymoma
Canada (Pasqua Hospital) - Thymoma
Canada (University Hospital of Sherbrooke) - Thymoma (AB type)
India, Karnataka - Hodgkin nodular sclerosis
Japan (Asahi General Hospital) - Thymoma, type A
Japan (Gunma University Hospital) - Thymoma, type AB
Japan (Hamamatsu University School of Medicine) - Type AB, thymoma
Qatar (Hamad Medical Corporation) - Thymoma (3); Biphasic synovial sarcoma (2)
Saudi Arabia (King Fahad National Guard Hospital) - Thymoma, type AB
Spain (Povisa Hospital) - Thymoma
United Kingdom (Oxford Study Group) - Thymoma

Case 10 - Diagnosis:

Thymoma

T-Y2300, M-85800

Case 10 - References:

Kondo K and Monden Y. Thymoma and Myasthenia Gravis. A Clinical Study of 1,089 Patients from Japan. *Ann Thorac Surg* 2005; 79(1):219-224.

Moran CA and Suster S. "Ancient" (Sclerosing) Thymomas. A Clinicopathologic Study of 10 Cases. *Am J Clin Pathol* 2004; 121(6):867-871.

Kanzaki M, Oyama K, Ikeda T, et al. Noninvasive Thymoma in the Middle Mediastinum. *Ann Thorac Surg* 2004; 2209-2210.

Kondo K, Yoshizawa K, Tsuyuguchi M, et al. WHO Histologic Classification is a Prognostic Indicator in Thymoma. *Ann Thorac Surg* 2004; 77(4):1183-1188.

Pan CC, Chen PC and Chiang H. KIT (CD117) is Frequently Overexpressed in Thymic Carcinomas but is Absent in Thymomas. *J Pathol* 2004; 202(3):375-381.

Pan CC Chen PC, Chou TY, et al. Expression of Calretinin and Other Mesothelioma-Related Markers in Thymic Carcinoma and Thymoma. *Hum Pathol* 2003; 34(11):1155-1162.