1186

CALIFORNIA
TUMOR TISSUE REGISTRY

"GENERAL PATHOLOGY"

Study Cases, Subscription A

May 2005

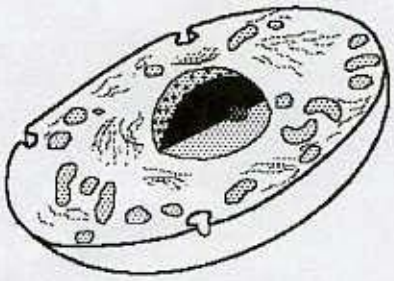

California Tumor Tissue Registry

c/o: Department of Pathology and Human Anatomy
Loma Linda University School of Medicine
11021 Campus Avenue, AH 335
Loma Linda, California 92350 U.S.A.

(909) 558-4788
FAX: (909) 558-0188

E-mail: cttr@linkline.com
Home Page: www.cttr.org

Target audience:

Practicing pathologists and pathology residents.

Goal:

To acquaint the participant with the histologic features of a variety of benign and malignant neoplasms and tumor-like conditions.

Objectives:

The participant will be able to recognize morphologic features of a variety of benign and malignant neoplasms and tumor-like conditions and relate those processes to pertinent references in the medical literature.

Educational methods and media:

Review of representative glass slides with associated histories.
Feedback on consensus diagnoses from participating pathologists.
Listing of selected relevant references from the medical literature.

Principal faculty:

Weldon K. Bullock, MD
Donald R. Chase, MD

CME Credit:

Loma Linda University School of Medicine designates this continuing medical education activity for up to 2 hours of Category I of the Physician's Recognition Award of the American Medical Association.
Note: CME credit is offered for the subscription year only.

Accreditation:

Loma Linda University School of Medicine is accredited by the Accreditation Council for Continuing Medical Education (ACCME) to sponsor continuing medical education for physicians.

Contributor: Nora Ostrzega/Douglas Kahn, M.D.
Sylmar, CA

Case No. 1 - May 2005

Tissue from: Colon

Accession #29828

Clinical Abstract:

A 28-year-old female presented with left lower quadrant pain of five months duration. A barium enema revealed a mucosal-based mass. A polypectomy was performed.

Gross Pathology:

Removed was a polypoid structure measuring 3.5 cm in diameter. The polyp was smooth with a homogeneous cut surface.

Contributor: Henry Slosser, M.D.
Pasadena, CA

Case No. 2 - May 2005

Tissue from: Left breast

Accession #29570

Clinical Abstract:

Over the past ten years a 39-year-old female had two remarkably large masses in her left breast. A mastectomy was performed.

Gross Pathology:

The tumors were similar, consisting of firm gray tissue with focal hemorrhage. The largest mass weighed 5,310 grams and measured 29.0 x 27.0 x 16.0 cm. The second was soft and somewhat ovoid, weighing 326 grams and measuring 11.0 x 10.0 x 6.5 cm.

Contributor: Kenneth A Frankel, M.D.
Glendale, CA

Case No. 3 - May 2005

Tissue from: Breast

Accession #29803

Clinical Abstract:

A 30-year-old female presented with a palpable mass in the upper-outer quadrant of her right breast.

Gross Pathology:

The excision measured 13.0 x 12.0 x 4.0 cm and contained a fairly well-circumscribed mass that was 7.0 cm in greatest diameter.

Contributor: Faramarz Azizi, M.D.
Fontana, CA

Case No. 4 - May 2005

Tissue from: Ovary

Accession #29804

Clinical Abstract:

A 64-year-old gravida 7, para 4, ab 3 female experienced occasional pelvic pain. Ultrasound and CT scan showed an adnexal mass. A TAH/BSO (Marshall-Marchetti-Krantz) was performed.

Gross Pathology:

The smooth-surfaced grayish-pink ovary weighed 248 grams and measured 13.0 x 10.0 x 7.0 cm and had a segment of fallopian tube measuring 5.0 x 0.7 cm. Sectioning through the ovary showed multiple various sized cysts as well as solid homogenous areas which included fresh hemorrhage and some suggestion of infarct-like necrosis.

Contributor: **LLUMC Pathology Group (mm)**
Loma Linda, CA

Case No. 5 - May 2005

Tissue from: **Left parotid**

Accession #29761

Clinical Abstract:

A 55-year-old diabetic male was noted to have a 5 x 3 cm mass inferior to his left ear. It had been present for about 10 years and had been gradually increasing in size. It had recently become painful, and he underwent FNA and a partial parotidectomy.

Gross Pathology:

The 31.8 gram, 5.5 x 4.5 x 2.5 cm pink-tan tissue contained a 3.3 x 3.0 x 2.7 cm circumscribed soft, pink-tan lobulated cut surface with grossly intact thin capsule.

Contributor: **Yasuchi Tamura, M.D.**
Bellflower, CA

Case No. 6 - May 2005

Tissue from: **Pelvis**

Accession #29835

Clinical Abstract:

Having a history of hysterectomy (with previously diagnosed leiomyomas) this 70-year-old female had a pelvic mass removed.

Gross Pathology:

The reddish-gray retroperitoneal mass measured 9.0 x 6.0 x 4.5 cm.

SPECIAL STUDIES:

SMA	positive
Actin	positive
Desmin	positive
Calponin	positive
ER	positive
PR	positive
CAM5.2/AE1	negative
S-100	negative
CD34	negative
CD31	negative
CD117	negative

Contributor: John Sacoolidge, M.D.
Sylmar, CA

Case No. 7 - May 2005

Tissue from: Omentum/Right ovary

Accession #29968

Clinical Abstract:

A 69-year-old female complained of increased abdominal girth. A transabdominal and endovaginal ultrasound of the pelvis showed only a retroverted uterus but also noted thickened omentum. An FNA favored a poorly differentiated adenocarcinoma. A serum CA-125 was normal. An open excisional biopsy was performed.

Gross Pathology:

The resected omentum consisted of a piece of multilobulated fatty tissue measuring 5.0 x 2.0 x 1.0 cm. The surface was studded with pink-yellow nodules ("omental cake").

SPECIAL STUDIES:

CK7	positive
Calretinin	focally positive
EMA	positive
CK20	negative
GCDFP	negative
TTF1	negative
Mucin	negative
S100	negative
CD117	negative
E-cadherin	negative

Contributor: Robert H. Zuch, M.D.
Baldwin Park, CA

Case No. 8 - May 2005

Tissue from: Right knee

Accession #29840

Clinical Abstract:

A 17-year-old male developed a mass on his right knee.

Gross Pathology:

The excised specimen was ovoid and 5.0 x 5.0 x 4.5 x 1.0 cm. It was firm tan-white nodular and 5.0 cm in greatest diameter.

Contributor: LLUMC Pathology Group (rc)
Loma Linda, CA

Case No. 9 - May 2005

Tissue from: Testicle

Accession #30205

Clinical Abstract:

A 57 y/o male presented with a 3-4 month history of an enlarged, firm non-tender testicle. Physical exam showed a left, solid testicular mass approximating 6.0 cm in greatest diameter. An echogram showed enlargement with "inhomogeneous echoic densities and increasing vascularity most consistent with testicular tumor".

Gross Pathology:

The testis was 127 grams and contained a white-tan whorled nodule measuring 4.5 x 4.0 x 4.0 cm.

Contributor: John McGill, M.D.
Pasadena, CA

Case No. 10 - May 2005

Tissue from: Sternum

Accession #29843

Clinical Abstract:

A slow-growing mass was noted on the sternum of an 85-year-old male.

Gross Pathology:

A composite resection of the sternum and ribs showed a 9.0 x 5.0 x 5.0 cm solid well-circumscribed mass. Soft tissue invasion was not seen.

CALIFORNIA
TUMOR TISSUE REGISTRY

GENERAL PATHOLOGY

Minutes – Subscription A

May, 2005

SUGGESTED READING (General Topics from Recent Literature):

Diagnostic Accuracy of Second-Opinion Diagnoses Based on Still Images. Nordrum I, Johansen M, Amin A, et al. *Hum Pathol* 2004; 35(1):129-135.

Proliferative Activity in Primary Breast Carcinomas is a Salient Prognostic Factor. Michels J-J, Marnay J, Delozier T, et al. *Cancer* 2004; 100(3):455-464.

Laparoscopic Surgical Staging in Cervical Cancer. Chu KK, Chang S-D, Chen FP, et al. Preliminary Experience Among Chinese. *Gynecol Oncol* 1997; 64(1):49-53.

Telomerase Activity in Gynecologic Tumors. Zheng P-S, Iwasaka T, Yanasaki F, et al. *Gynecol Oncol* 1997; 64(1):171-175.

Primer on Medical Genomics. Part X1: Visualizing Human Chromosomes. Spurbeck JL, Adams SA, Stupca PJ, et al. *Mayo Clin Proc* 2004; 79:58-75.

California Tumor Tissue Registry
c/o: Department of Pathology and Human Anatomy
Loma Linda University School of Medicine
11021 Campus Avenue, AH 335
Loma Linda, California 92350
(909) 558-4788
FAX: (909) 558-0188
E-mail: cttr@linkline.com
Web site & Case of the Month: www.cttr.org

FILE DIAGNOSES

CTTR Subscription A **May, 2005**

Case 1:

Juvenile polyp with focal low grade dysplasia, colon
T-67000, M-75640

Case 2:

Phyllodes tumor, low grade, breast
T-04000, M-90213

Case 3:

Phyllodes tumor, malignant, breast
T-04000, M-90213

Case 4:

Ovarian fibroma/fibroma with changes likely due to torsion
T-87000, M-86000

Case 5:

Acinic cell carcinoma, low grade, parotid gland
T-55100, M-85501

Case 6:

Epithelial leiomyosarcoma, low grade, pelvis and retroperitoneum
T-Y4600, M-88913

Case 7:

High grade mesothelioma, peritoneum
T-87000, M-90503

Case 8:

Synovial sarcoma, biphasic knee
T-78000, M-88900

Case 9:

Leiomyoma, paratesticular/scrotal
T-78000, M-88900

Case 10:

Low grade chondrosarcoma, sternum
T-78000, M-88900

Alameda (Alameda County Medical Center) - Tubulovillous adenoma
Baldwin Park (Kaiser Permanente) - Peutz-Jegher polyp (3)
Fontana (Kaiser Permanente) - Juvenile polyp
Glendale - Villoglandular adenoma
Irvine (University of California Residents) - Tubular adenoma with features of prolapse
Long Beach - Hamartomatous polyp (Puetz-Jeghers) (7)
Monterey Park (Monterey Peninsula Residents) - Benign hyperplastic polyp (1); Tubular adenoma (1)
Sacramento (UC Davis Medical Center Residents) - Tubular adenoma
San Diego (Naval Medical Center) - Juvenile polyp with adenomatous change
San Francisco (San Francisco General Hospital) - Peutz-Jeghers polyp
Santa Barbara (Cottage Hospital) - Tubulovillous adenoma
Santa Rosa (Santa Rosa Memorial Hospital) - Peutz-Jeghers polyp (3)
Ventura - Villoglandular adenoma
Arizona (Maryvale Medical Center) - Peutz-Jeghers polyp, colon
Colorado, Evergreen - Peutz-Jegher polyp
Colorado (Lutheran Medical Center) - Juvenile polyp
Connecticut - Tubular adenoma with pseudoinvasion
Florida (Baptist Pathology) - Hamartomatous polyp with moderate dysplasia
Florida (Winter Haven Hospital) - Tubular adenoma
Illinois, Burr Ridge - Juvenile polyp
Indiana (Ball Memorial Hospital) - Juvenile polyp
Indiana (Howard Community Hospital) - Cronkite-canada polyp
Louisiana (Louisiana State University Health Science Center) - Tubular adenoma
Maryland (National Naval Medical Center) - Tubular adenoma (10); Juvenile Polyp (1)
Maryland (University of Maryland Residents) - Juvenile polyp
Massachusetts (New England Medical Center) - Juvenile polyp
Michigan (Oakwood Hospital) - Juvenile polyp
Minnesota (Fairview Ridges Hospital) - Juvenile polyp
Nebraska (Creighton University School of Medicine) - Juvenile (retention) polyp
New York (Presbyterian/Weill Cornell Campus) - Adenomatous polyp (tubular adenoma)
New York (Stony Brook University Hospital Residents) - Peutz-Jeghers , syndrome
North Carolina (Mountain Area Pathology) - Tubular adenoma (5)
Ohio (McCullough Hyde Memorial Hospital) - Juvenile polyp
Ohio (Medical College of Ohio) - Tubulovillous adenoma
Ohio (Valley Pathologists, Inc.) - Adenoma (1); Tubular adenoma (1); Tubulovillous adenoma (1)
Pennsylvania (Conemaugh Memorial Medical Center) - Juvenile polyp with dysplasia
Pennsylvania (Lehigh Valley Hospital) - Juvenile polyp
Pennsylvania (Mt. Nittany Medical Center) - Peutz-Jeghers polyp with low-grade dysplasia, colon
Pennsylvania (Pennsylvania Hospital Pathology Residents) - Juvenile polyp
Puerto Rico (University of Puerto Rico) - Peutz-Jeghers polyp with adenomatous transformation
Texas, Lubbock - Adenomatous polyp with focal severe dysplasia
Texas (Propath Associates) - Hamartomatous polyp of colon (2)
Texas (San Antonio) - Peutz-Jegher polyp with adenomatous change
Texas (Scott & White Memorial Hospital) - Peutz-Jegher polyp
West Virginia (Greenbrier Valley Medical Center) - Tubular adenoma
Australia (North Queensland Pathology) - Peutz-Jegher polyp
Australia (Royal Prince Alfred Hospital) - Hamartomatous polyp of Peutz-Jeghers type, dysplasia
Brazil (UNIFESP/EPM) - Intramucosal carcinoma arising in tubular adenoma
Canada (Woodstock General Hospital) - Tubular adenoma with entrapped glands, colon
Germany, Hamburg - Tubular adenoma with low-moderate dysplasia
Hong Kong (Hong Kong Baptist Hospital) - Tubular adenoma with pseudoinvasion

Italy, Naples - Peutz-Jeghers polyp
Netherlands, Amsterdam - Tubulovillous adenoma
Qatar (Hamad Medical Corporation) - Tubular adenomatous polyp

Case 1 - Diagnosis:

Juvenile polyp with focal low grade dysplasia, colon

Director's note: Note close similarity in places to a Peutz-Jegher polyp. (drc)

T-67000, M-75640

Case 1 – References:

Dajani YF and Kamal MF. Colorectal Juvenile Polyps. An Epidemiological and Histopathological Study of 144 Cases in Jordanians. *Histopathol* 1984; 8(5):765-779.

Lipper S, Kahn LB, Sandler RS, et al. Multiple Juvenile Polyposis. A Study of Pathogenesis of Juvenile Polyps and Their Relationship to Colonic Adenomas. *Hum Pathol* 1981; 12(9):804-813.

Mills SE and Fechner RE. Unusual Adenomatous Polyps in Juvenile Polyposis Coli. *Am J Surg Pathol* 1982; 6(2):177-183.

Grotsky HW, Rickert RR, Smith WD, et al. Familial Juvenile Polyposis Coli. A Clinical and Pathologic Study of a Large Kindred. *Gatroenterology* 1982; 82(3):494-501.

Jarvinen H and Franssila KO. Familial Juvenile Polyposis Coli. Increased Risk of Colorectal Cancer. *Gut* 1984; 25(7):792-800.

Goodman ZD, Yardley JH and Milligan FD. Pathogenesis of Colonic Polyps in Multiple Juvenile Polyposis. Report of a Case Associated with Gastric Polyps and Carcinoma of the Rectum. *Cancer* 1979; 43(5):1906-1913.

Case No. 2, Accession No. 29570 May 2005

Alameda (Alameda County Medical Center) - Phyllodes tumor
Baldwin Park (Kaiser Permanente) - Phyllodes tumor (1); Low grade phyllodes tumor (2)
Fontana (Kaiser Permanente) - Malignant Phyllodes tumor
Glendale - Phyllodes tumor
Irvine (University of California Residents) - Malignant Phyllodes tumor with rhabdomyoblastic tumor
Long Beach - Phyllodes tumor, malignant (7)
Monterey Park (Monterey Peninsula Residents) - Phyllodes tumor, high grade (1); Phyllodes tumor (1)
Sacramento (UC Davis Medical Center Residents) - Phyllodes tumor
San Diego (Naval Medical Center) - Juvenile fibroadenoma (giant)
San Francisco (San Francisco General Hospital) - Phyllodes tumor
Santa Barbara (Cottage Hospital) - Angiosarcoma
Santa Rosa (Santa Rosa Memorial Hospital) - Phyllodes tumor (3)
Ventura - Phyllodes tumor
Arizona (Maryvale Medical Center) - Phyllodes tumor, malignant
Colorado, Evergreen - Phyllodes tumor
Colorado (Lutheran Medical Center) - Phyllodes tumor
Connecticut - Phyllodes tumor, intermediate or borderline
Florida (Baptist Pathology) - Phyllodes tumor
Florida (Winter Haven Hospital) - Phyllodes tumor, intermediate grade
Illinois, Burr Ridge - Cystosarcoma phyllodes
Indiana (Ball Memorial Hospital) - Adenomyoepithelioma
Indiana (Howard Community Hospital) - Cellular phyllodes tumor
Louisiana (Louisiana State University Health Science Center) - Phyllodes tumor, low malignant potential
Maryland (National Naval Medical Center) - Phyllodes tumor
Maryland (University of Maryland Residents) - Juvenile (cellular) fibroadenoma
Massachusetts (New England Medical Center) - Malignant Phyllodes tumor
Michigan (Oakwood Hospital) - Phyllodes tumor
Minnesota (Fairview Ridges Hospital) - Phyllodes tumor, low grade with pseudoangiomatous stroma
Nebraska (Creighton University School of Medicine) - Phyllodes tumor, borderline

New York (Presbyterian/Weill Cornell Campus) - Phyllodes tumor (benign)
New York (Stony Brook University Hospital Residents) - Pleomorphic adenoma
North Carolina (Mountain Area Pathology) - Phyllodes tumor, low grade (4); Phyllodes tumor (1)
Ohio (McCullough Hyde Memorial Hospital) - Cystosarcoma
Ohio (Medical College of Ohio) - Low-grade malignant Phyllodes tumor (borderline Phyllodes)
Ohio (Valley Pathologists, Inc.) - Benign mesenchymal tumor (2); Myoepithelioma (1)
Pennsylvania (Conemaugh Memorial Medical Center) - Low grade Phyllodes tumor
Pennsylvania (Lehigh Valley Hospital) - Metaplastic carcinoma
Pennsylvania (Mt. Nittany Medical Center) - Amyloid tumor, breast
Pennsylvania (Pennsylvania Hospital Pathology Residents) - Adenomyoepithelioma
Puerto Rico (University of Puerto Rico) - Phyllodes tumor, benign
Texas, Lubbock - Malignant Phyllodes tumor
Texas (Propath Associates) - Malignant Phyllodes tumor (2)
Texas (San Antonio) - Phyllodes tumor (? rhabdomyoblasts in stroma)
Texas (Scott & White Memorial Hospital) - Phyllodes tumor
West Virginia (Greenbrier Valley Medical Center) - Metaplastic carcinoma (spindle cell)
Australia (North Queensland Pathology) - Benign Phyllodes tumor
Australia (Royal Prince Alfred Hospital) - Malignant Phyllodes tumor of breast
Brazil (UNIFESP/EPM) - Borderline Phyllodes tumor (2)
Canada (Woodstock General Hospital) - Myofibroblastoma, breast (rule/out spindle cell carcinoma)
Germany, Hamburg - Pseudoangiomatous stromal hyperplasia
Hong Kong (Hong Kong Baptist Hospital) - Phyllodes tumor
Italy, Naples - Phyllodes tumor
Jamaica (University Hospital of the West Indies) - Pseudoangiomatous stromal hyperplasia, breast
Netherlands, Amsterdam - Malignant Phyllodes tumor
Qatar (Hamad Medical Corporation) - Phyllodes tumor, most probably benign

Case 2 - Diagnosis:

Phyllodes tumor, low grade, breast
T-04000, M-90213

Case 2 - References:

Krishnamurthy S, Ashfaq R, Shin HJ, et al. Distinction of Phyllodes Tumor From Fibroadenoma. A Reappraisal of an Old Problem. *Cancer* 2000; 25; 90(6):342-349.

Geisler DP, Boyle MJ, Malnar KF, et al. Phyllodes Tumors of the Breast. A Review of 32 Cases. *Am Surg* 2000; 66(4):360-366.

Chhieng DC, Cangiarella JF, Waisman J, et al. Fine-Needle Aspiration Cytology of Spindle Cell Lesions of the Breast. *Cancer* 1999; 87(6):359-371.

Kleer CG, Giordano TJ, Braun T, et al. Pathologic, Immunohistochemical, and Molecular Features of Benign and Malignant Phyllodes Tumors of the Breast. *Mod Pathol* 2001; 14(3):185-190.

Case No. 3, Accession No. 29803 May 2005

Alameda (Alameda County Medical Center) - Sarcoma (pending special stains)
Baldwin Park (Kaiser Permanente) - Phyllodes tumor, malignant (3)
Fontana (Kaiser Permanente) - Sarcoma
Glendale - High-grade Phyllodes tumor
Irvine (University of California Residents) - Metaplastic carcinoma/Phyllodes tumor
Long Beach - Phyllodes tumor, malignant (7)
Monterey Park (Monterey Peninsula Residents) - Low grade stroma sarcoma (1); Sarcoma, ? muscle vs. vascular (1)
Sacramento (UC Davis Medical Center Residents) - Giant fibroadenoma
San Diego (Naval Medical Center) - Adenomyoepithelioma
San Francisco (San Francisco General Hospital) - Borderline Phyllodes tumor
Santa Barbara (Cottage Hospital) - Malignant neoplasm; sarcoma vs. metaplastic carcinoma

Santa Rosa (Santa Rosa Memorial Hospital) - Stromal tumor of breast, probably malignant (1); Phyllodes tumor, probably malignant (1); Myoepithelioma (1)
Ventura - Leiomyosarcoma
Arizona (Maryvale Medical Center) - Liposarcoma, well-differentiated, breast
Colorado, Evergreen - Fibrosarcoma
Colorado (Lutheran Medical Center) - Adenomyoepithelioma
Connecticut - Malignant Phyllodes
Florida (Baptist Pathology) - High grade sarcoma, spindle cell sarcoma vs. angiosarcoma
Florida (Winter Haven Hospital) - Phyllodes tumor, high grade
Illinois, Burr Ridge - Stromal sarcoma
Indiana (Ball Memorial Hospital) - Myoepithelial carcinoma
Indiana (Howard Community Hospital) - Fibrosarcoma
Louisiana (Louisiana State University Health Science Center) - Leiomyosarcoma
Maryland (National Naval Medical Center) - Leiomyosarcoma (5); Angiosarcoma (6)
Maryland (University of Maryland Residents) - Phyllodes tumor
Massachusetts (New England Medical Center) - Juvenile fibroadenoma
Michigan (Oakwood Hospital) - Fibrosarcoma (rule out metaplastic carcinoma)
Nebraska (Creighton University School of Medicine) - High grade sarcoma
New York (Presbyterian/Weill Cornell Campus) - Myofibroblastic tumor
New York (Stony Brook University Hospital Residents) - Myofibroblastoma
North Carolina (Mountain Area Pathology) - Phyllodes tumor, malignant (2); Phyllodes tumor, low grade malignant (1); Phyllodes tumor, malignant potential uncertain (1); Adenomyoepithelioma vs. Phyllodes tumor (1)
Ohio (McCullough Hyde Memorial Hospital) - Low grade sarcoma
Ohio (Medical College of Ohio) - Low-grade fibrosarcoma
Ohio (Valley Pathologists, Inc.) - Leiomyosarcoma (3)
Pennsylvania (Conemaugh Memorial Medical Center) - Fibrosarcoma, high grade
Pennsylvania (Lehigh Valley Hospital) - Leiomyosarcoma
Pennsylvania (Mt. Nittany Medical Center) - Myofibroblastoma, breast
Pennsylvania (Pennsylvania Hospital Pathology Residents) - Nodular fasciitis
Puerto Rico (University of Puerto Rico) - Spindle cell sarcoma
Texas, Lubbock - Nodular fasciitis
Texas (Propath Associates) - Fibrosarcoma (2)
Texas (San Antonio) - Malignant spindle cell neoplasm (favor spindle cell carcinoma)
Texas (Scott & White Memorial Hospital) - Malignant Phyllodes tumor
West Virginia (Greenbrier Valley Medical Center) - Sarcoma, NOS
Australia (North Queensland Pathology) - Malignant Phyllodes tumor
Australia (Royal Prince Alfred Hospital) - Malignant Phyllodes tumor of breast
Brazil (UNIFESP/EPM) - Malignant Phyllodes tumor (2)
Canada (Woodstock General Hospital) - Sarcoma, breast (r/o spindle cell carcinoma and Phyllodes tumor)
Germany, Hamburg - Myoepithelial carcinoma
Hong Kong (Hong Kong Baptist Hospital) - Spindle cell sarcoma
Italy, Naples - Solitary fibrous tumor
Jamaica (University Hospital of the West Indies) - Myofibroblastoma, breast
Netherlands, Amsterdam - Benign Phyllodes tumor
Qatar (Hamad Medical Corporation) - Phyllodes tumor, malignant

Case 3 - Diagnosis:

Phyllodes tumor, malignant, breast

Directors note: This case also probably fits into the spectrum of periductal stomal sarcoma. (drc)

T-04000, M-90213

Case 3 - References:

Burga AM and Tavassoli FA. Periductal Stromal Tumor. A Rare Lesion with Low-Grade Sarcomatous Behavior. *Am J Surg Pathol* 2003; 27(3):343-348.

Asoglu O, Ugurlu MM, Blanchard K, et al. Risk Factors for Recurrence and Death After Primary Surgical Treatment of Malignant Phyllodes Tumors. *Ann Surg Oncol* 2004; 11(11):1011-1017.

Vladescu T, Klijanienko J, Caillaud JM, et al. Fine-Needle Sampling in Malignant Phyllodes Tumors. Clinicopathologic Study of 22 Cases Seen at the Institut Curie. *Diagn Cytopathol* 2004; 31(2):71-76.

Guerrero MA, Ballard BR and Grau AM. Malignant Phyllodes Tumor of the Breast. Review of the Literature and Case Report of Stromal Overgrowth. *Surg Oncol* 2003; 12(1):27-37.

Alameda (Alameda County Medical Center) - Thecoma
Baldwin Park (Kaiser Permanente) - Granulosa cell tumor (3)
Fontana (Kaiser Permanente) - Fibroma
Glendale - Fibrothecoma
Irvine (University of California Residents) - Massive ovarian edema with torsion
Long Beach - Ovarian stromal tumor (Leydig's cell?) (7)
Monterey Park (Monterey Peninsula Residents) - Theca-Lutein cyst (1); Granulosa cell tumor (1)
Sacramento (UC Davis Medical Center Residents) - Sertoli-Leydig cell tumor
San Diego (Naval Medical Center) - Sclerosing stromal tumor
San Francisco (San Francisco General Hospital) - Sclerosing stromal tumor
Santa Barbara (Cottage Hospital) - Probable stromal tumor, favor benign
Santa Rosa (Santa Rosa Memorial Hospital) - Stromal tumor of ovary with necrosis (1); Necrosing stromal tumor, NOS (1); Ovarian thecoma with edema and necrosis-? torsion effect (1)
Ventura - Malignant thecoma
Arizona (Maryvale Medical Center) - Krukenberg tumor
Colorado, Evergreen - Inflammatory myofibroblastoma
Colorado (Lutheran Medical Center) - Adult granulosa cell tumor
Connecticut - Ovarian stromal tumor
Florida (Baptist Pathology) - Stromal luteoma
Florida (Winter Haven Hospital) - Infarcted granulosa cell tumor
Illinois, Burr Ridge - Thecoma
Indiana (Ball Memorial Hospital) - Hyperreactio luteinalis
Indiana (Howard Community Hospital) - Ovarian myxoma
Louisiana (Louisiana State University Health Science Center) - Granulosa cell tumor
Maryland (National Naval Medical Center) - Thecoma
Maryland (University of Maryland Residents) - Fibrothecoma with infarction
Massachusetts (New England Medical Center) - Fibrothecoma consistent with ovarian torsion
Michigan (Oakwood Hospital) - Granulosa cell tumor
Minnesota (Fairview Ridges Hospital) - Sex-cord stromal tumor vs. metastatic melanoma
Nebraska (Creighton University School of Medicine) - Sclerosing stromal tumor
New York (Presbyterian/Weill Cornell Campus) - Juvenile granulose cell tumor
New York (Stony Brook University Hospital Residents) - Thecoma
North Carolina (Mountain Area Pathology) - Fibroma, infracted (1); Fibroma with degenerative changes (1); Sex cord stromal tumor possibly Leydig-cell tumor (1); Sex cord stromal tumor, NOS consistent with necrosis (1); Thecoma (1)
Ohio (McCullough Hyde Memorial Hospital) - Granulosa cell tumor with hemorrhage
Ohio (Medical College of Ohio) - Massive ovarian edema associated with infarction
Ohio (Valley Pathologists, Inc.) - Sex cord stromal tumor (2); Granulosa cell tumor (1)
Pennsylvania (Conemaugh Memorial Medical Center) - Sclerosing stromal tumor
Pennsylvania (Lehigh Valley Hospital) - Sex cord stromal tumor
Pennsylvania (Mt. Nittany Medical Center) - Adult granulosa cell tumor, ovary
Pennsylvania (Pennsylvania Hospital Pathology Residents) - Thecoma with torsion
Puerto Rico (University of Puerto Rico) - Myxoma/inflammatory pseudotumor
Texas, Lubbock - Twisted ovary
Texas (Propath Associates) - Ovarian stromal tumor (2)
Texas (San Antonio) - ? old endometriotic cyst, ? benign stromal tumor vs. massive edema
Texas (Scott & White Memorial Hospital) - Sclerosing stromal tumor
West Virginia (Greenbrier Valley Medical Center) - Granulosa cell tumor
Australia (North Queensland Pathology) - Torted stromal tumor
Australia (Royal Prince Alfred Hospital) - Malignant sex cord stromal tumor; ? poorly differentiated Sertoli-Leydig cell tumor
Brazil (UNIFESP/EPM) - Fibrothecoma (2)
Canada (Woodstock General Hospital) - Massive edema with necrosis, ovary

Germany, Hamburg - Thecoma with infract
Hong Kong (Hong Kong Baptist Hospital) - Stromal hyperthecosis
Italy, Naples - Fibrothecoma
Jamaica (University Hospital of the West Indies) - Infarction, ovary
Netherlands, Amsterdam - Reactive changes due to torsion? (infarction, bleeding, fibroblastic proliferation & chronic inflammation)
Qatar (Hamad Medical Corporation) - Granulosa cell tumor

Case 4 - Diagnosis:

Ovarian fibroma/fibroma with changes likely due to torsion
T-87000, M-86000

Case 4 - References:

Bozot M, Ghossain MA, Buy JN, et al. Fibrothecomas of the Ovary. CT and US Findings. *J Comput Assist Tomogr* 1993; 17(5):754-759.

Kimura I, Togashi K, Kawakami S, et al. Ovarian Torsion. CT and MR Imaging Appearances. *Radiol* 1994; 190(2):337-341.

Troiano RN, Lazzarini KM, Scoutt LM, et al. Fibroma and Fibrothecoma of the Ovary. MR Imaging Findings. *Radiol* 1997; 204(3):795-798.

Conte M, Guariglia L, Benedetti PP, et al. Ovarian Fibrothecoma. Sonographic and Histologic Findings. *Gynecol Obstet Invest* 1991; 32(1):51-54.

Case No. 5, Accession No. 29761 May 2005

Alameda (Alameda County Medical Center) - Acinic cell adenocarcinoma
Baldwin Park (Kaiser Permanente) - Acinic cell carcinoma (3)
Fontana (Kaiser Permanente) - Acinic cell carcinoma
Glendale - Acinic cell adenocarcinoma
Irvine (University of California Residents) - Acinic cell carcinoma
Long Beach - Acinic cell carcinoma (7)
Monterey Park (Monterey Peninsula Residents) - Low grade acinic cell tumor (2)
Sacramento (UC Davis Medical Center Residents) - Acinic cell adenoma
San Diego (Naval Medical Center) - Acinic cell carcinoma
San Francisco (San Francisco General Hospital) - Acinic cell carcinoma
Santa Barbara (Cottage Hospital) - Acinic cell carcinoma
Santa Rosa (Santa Rosa Memorial Hospital) - Acinic cell carcinoma (3)
Ventura - Oncocytoma
Arizona (Maryvale Medical Center) - Acinic cell adenocarcinoma
Colorado, Evergreen - Acinic cell carcinoma
Colorado (Lutheran Medical Center) - Acinic cell carcinoma
Connecticut - Acinic cell carcinoma
Florida (Baptist Pathology) - Acinic cell carcinoma
Florida (Winter Haven Hospital) - Acinic cell carcinoma
Illinois, Burr Ridge - Oxyphilic tumor
Indiana (Ball Memorial Hospital) - Acinic cell carcinoma
Indiana (Howard Community Hospital) - Acinic cell carcinoma
Louisiana (Louisiana State University Health Science Center) - Acinic cell carcinoma
Maryland (National Naval Medical Center) - Acinic cell carcinoma
Maryland (University of Maryland Residents) - Acinic cell carcinoma
Massachusetts (New England Medical Center) - Acinic cell carcinoma
Michigan (Oakwood Hospital) - Acinic cell carcinoma
Minnesota (Fairview Ridges Hospital) - Acinic cell carcinoma, ? ex-pleomorphic melanoma
Nebraska (Creighton University School of Medicine) - Acinic cell carcinoma
New York (Presbyterian/Weill Cornell Campus) - Acinic cell carcinoma

New York (Stony Brook University Hospital Residents) - Acinic cell carcinoma
North Carolina (Mountain Area Pathology) - Acinic cell carcinoma (5)
Ohio (McCullough Hyde Memorial Hospital) - Acinic cell carcinoma
Ohio (Medical College of Ohio) - Acinic cell adenocarcinoma
Ohio (Valley Pathologists, Inc.) - Acinic cell carcinoma (3)
Pennsylvania (Conemaugh Memorial Medical Center) - Pleomorphic adenoma
Pennsylvania (Lehigh Valley Hospital) - Acinic cell carcinoma
Pennsylvania (Mt. Nittany Medical Center) - Acinic cell carcinoma, parotid gland
Pennsylvania (Pennsylvania Hospital Pathology Residents) - Oncocytoma
Puerto Rico (University of Puerto Rico) - Acinic cell carcinoma
Texas, Lubbock - Cellular pleomorphic adenoma
Texas (Propath Associates) - Acinic cell adenocarcinoma (2)
Texas (San Antonio) - Acinar cell carcinoma
Texas (Scott & White Memorial Hospital) - Acinic cell carcinoma
West Virginia (Greenbrier Valley Medical Center) - Acinic cell carcinoma
Australia (North Queensland Pathology) - Acinic cell adenocarcinoma
Australia (Royal Prince Alfred Hospital) - Acinic cell carcinoma
Brazil (UNIFESP/EPM) - Acinic cell carcinoma (2)
Canada (Woodstock General Hospital) - Acinic cell tumor, parotid
Germany, Hamburg - Acinar cell carcinoma
Hong Kong (Hong Kong Baptist Hospital) - Acinic cell carcinoma
Italy, Naples - Acinic cell carcinoma
Jamaica (University Hospital of the West Indies) - Acinic cell tumor, parotid gland
Netherlands, Amsterdam - Acinic cell carcinoma of the parotid gland
Qatar (Hamad Medical Corporation) - Acinic cell carcinoma

Case 5 - Diagnosis:

Acinic cell carcinoma, low grade, parotid gland
T-55100, M-85501

Case 5 - References:

Sakai O, Nakashima N, Takata Y, et al. Acinic Cell Carcinoma of the Parotid Gland. CT and MRI. *Neuroradiol* 1996; 38(7):675-679.
Miki H, Masuda E, Ohata S, et al. Late Recurrence of Acinic Cell Carcinoma of the Parotid Gland. *J Med Invest* 1999; 46(3-4):213-216.
Tucci FM, Bianchi PM, Bottero S, et al. Acinic Cell Carcinoma of the Parotid Gland in Childhood. *Int J Pediatr Otorhinolaryngol* 1993; 27(2):187-191.
Henley JD, Geary WA, Jackson CL, et al. Dedifferentiated Acinic Cell Carcinoma of the Parotid Gland. A Distinct Rarely Described Entity. *Hum Pathol* 1997; 28(7):869-873.
Misselevich I, Podoshin L, Fradis M, et al. Salivary Gland Double Tumor. Synchronous Ipsilateral Pleomorphic Adenoma and Acinic Cell Carcinoma of the Parotid Gland. *Ann Otol Rhinol Laryngol* 1997; 106(3):226-229.

Case No. 6, Accession No. 29835 May 2005

Alameda (Alameda County Medical Center) - Leiomyosarcoma
Baldwin Park (Kaiser Permanente) - Leiomyosarcoma (3)
Fontana (Kaiser Permanente) - Pecoma
Glendale - Leiomyosarcoma
Irvine (University of California Residents) - Leiomyosarcoma
Long Beach - Leiomyosarcoma (7)
Monterey Park (Monterey Peninsula Residents) - Epithelioid leiomyoma (1); Intravenous leiomyomatosis vs. sarcoma (1)
Sacramento (UC Davis Medical Center Residents) - Stromal sarcoma
San Diego (Naval Medical Center) - Endometrial stromal sarcoma vs. epitheloid lumingio endothelioma
San Francisco (San Francisco General Hospital) - Cellular leiomyoma
Santa Barbara (Cottage Hospital) - Leiomyosarcoma

Santa Rosa (Santa Rosa Memorial Hospital) - Epithelioid leiomyoma, rule out malignancy (3)
Ventura - Leiomyosarcoma
Arizona (Maryvale Medical Center) - Cellular leiomyoma with focal hemorrhagic infarction
Colorado, Evergreen - Leiomyosarcoma
Colorado (Lutheran Medical Center) - Leiomyosarcoma
Connecticut - Leiomyosarcoma vs. endometrial stromal sarcoma
Florida (Baptist Pathology) - Epithelioid leiomyosarcoma
Florida (Winter Haven Hospital) - Leiomyoma
Illinois, Burr Ridge - Leiomyosarcoma
Indiana (Ball Memorial Hospital) - Epithelioid leiomyosarcoma
Indiana (Howard Community Hospital) - Leiomyosarcoma
Louisiana (Louisiana State University Health Science Center) - Leiomyoma, decidualized
Maryland (National Naval Medical Center) - Leiomyosarcoma
Maryland (University of Maryland Residents) - Leiomyoma, epithelioid type
Massachusetts (New England Medical Center) - Epithelioid leiomyosarcoma
Michigan (Oakwood Hospital) - Epithelioid leiomyosarcoma
Minnesota (Fairview Ridges Hospital) - Endometrioid stromal sarcoma, low grade
Nebraska (Creighton University School of Medicine) - Leiomyosarcoma
New York (Presbyterian/Weill Cornell Campus) - Glomangioma
New York (Stony Brook University Hospital Residents) - Cellular leiomyoma
North Carolina (Mountain Area Pathology) - STUMP, cannot exclude leiomyosarcoma (1); Leiomyosarcoma (1); Smooth muscle of LMP (1); Cellular leiomyoma with apoplectic changes vs. STUMP (1)
Ohio (McCullough Hyde Memorial Hospital) - Leiomyosarcoma
Ohio (Medical College of Ohio) - Low grade leiomyosarcoma
Ohio (Valley Pathologists, Inc.) - Leiomyosarcoma (2); Endometrial stromal sarcoma (1)
Pennsylvania (Conemaugh Memorial Medical Center) - Cellular leiomyoma
Pennsylvania (Lehigh Valley Hospital) - Cellular leiomyoma focally infarcted
Pennsylvania (Mt. Nittany Medical Center) - Endometrial stromal sarcoma, low-grade, retroperitoneum
Pennsylvania (Pennsylvania Hospital Pathology Residents) - Endometrial stromal parcoma
Puerto Rico (University of Puerto Rico) - Combined smooth muscle stromal tumor
Texas, Lubbock - Epithelioid leiomyosarcoma
Texas (Propath Associates) - Stromal cells sarcoma (2)
Texas (San Antonio) - Epithelioid leiomyosarcoma (? Pecoma ? HMB-45)
Texas (Scott & White Memorial Hospital) - Leiomyoma
West Virginia (Greenbrier Valley Medical Center) - Leiomyosarcoma
Australia (North Queensland Pathology) - Epithelioid leiomyoma
Australia (Royal Prince Alfred Hospital) - Epithelioid leiomyoma
Brazil (UNIFESP/EPM) - Retroperitoneal, smooth muscle tumor, hormonally, sensitive (leiomyoma?) (2)
Canada (Woodstock General Hospital) - Cellular leiomyoma, retroperitoneum
Germany, Hamburg - Intravascular epithelioid leiomyoma
Hong Kong (Hong Kong Baptist Hospital) - Leiomyosarcoma
Italy, Naples - Cellular leiomyoma
Netherlands, Amsterdam - Leiomyosarcoma
Qatar (Hamad Medical Corporation) - Epithelioid leiomyosarcoma

Case 6 - Diagnosis:

Epithelial leiomyosarcoma, low grade, pelvis and retroperitoneum
T-Y4600, M-88913

Consultation: Orthopaedic Hospital, Joseph M. Mirra, M.D. "Epthelioid Leiomyosarcoma, low grade (leiomyoblastoma), low grade, showing 1 of 3 anaplasia."

Case 6 - References:

Shmookler BM and Lauer DH. Retroperitoneal Leiomyosarcoma. A Clinicopathologic Analysis of 36 Cases. *Am J Surg Pathol* 1983; 7(3):269-280.
Paal E and Miettinen M. Retroperitoneal Leiomyomas. A Clinicopathologic and Immunohistochemical Study of 56 Cases with a Comparison to Retroperitoneal Leiomyosarcomas. *Am J Surg Pathol* 2001; 25(11):1355-1363.
Oda Y, Miyajima K, Kawaguchi K, et al. Pleomorphic Leiomyosarcoma. Clinicopathologic and Immunohistochemical Study with Special Emphasis on Its Distinction from Ordinary Leiomyosarcoma and Malignant Fibrous Histiocytoma. *Am J Surg Pathol* 2001; 25(8):1030-1038.
Todd CS, Michael H and Sutton G. Retroperitoneal Leiomyosarcoma. Eight Cases and a Literature Review. *Gynecol Oncol* 1995; 59(3):333-337.
Rajani B, Smith TA, Reith JD, et al. Retroperitoneal Leiomyosarcomas Unassociated with the Gastrointestinal Tract. A Clinicopathologic Analysis of 17 Cases. *Mod Pathol* 1999; 12(1):21-28.

Case No. 7, Accession No. 29968 May 2005

Alameda (Alameda County Medical Center) - Malignant mesothelioma
Baldwin Park (Kaiser Permanente) - Poorly differentiated carcinoma (1); Malignant mesothelioma (2)
Fontana (Kaiser Permanente) - Mesothelioma
Glendale - Mesothelioma
Irvine (University of California Residents) - Mesothelioma
Long Beach - Malignant mesothelioma (7)
Monterey Park (Monterey Peninsula Residents) - Malignant mesothelioma, grade #1 (1); Mesothelioma, epithelioid (1)
Sacramento (UC Davis Medical Center Residents) - Mesothelioma
San Diego (Naval Medical Center) - Poorly differentiated carcinoma, primary peritoneal vs. metastatic ovarian
San Francisco (San Francisco General Hospital) - Undifferentiated carcinoma
Santa Barbara (Cottage Hospital) - Malignant neoplasm, high grade, favor mesothelioma
Santa Rosa (Santa Rosa Memorial Hospital) - Malignant mesothelioma (1); Mesothelioma, epithelioid type (1)
Ventura - Mesothelioma
Arizona (Maryvale Medical Center) - Diffuse malignant epithelial mesothelioma
Colorado, Evergreen - Mesothelioma
Colorado (Lutheran Medical Center) - Epithelioid malignant mesothelioma
Connecticut - Mesothelioma
Florida (Baptist Pathology) - Poorly differentiated mesothelioma
Florida (Winter Haven Hospital) - Poorly differentiated carcinoma
Illinois, Burr Ridge - Malignant mesothelioma
Indiana (Ball Memorial Hospital) - Mesothelioma
Indiana (Howard Community Hospital) - Malignant mesothelioma
Louisiana (Louisiana State University Health Science Center) - Mesothelioma
Maryland (National Naval Medical Center) - Mesothelioma
Maryland (University of Maryland Residents) - Mesothelioma
Massachusetts (New England Medical Center) - Metastatic poorly differentiated carcinoma
Michigan (Oakwood Hospital) - Mesothelioma
Minnesota (Fairview Ridges Hospital) - Malignant mesothelioma
Nebraska (Creighton University School of Medicine) - Peritoneal mesothelioma
New York (Presbyterian/Weill Cornell Campus) - Poorly differentiated adenocarcinoma
New York (Stony Brook University Hospital Residents) - Malignant mesothelioma
North Carolina (Mountain Area Pathology) - Deciduoid mesothelioma (2); Mesothelioma (2); Epithelioid mesothelioma (1)
Ohio (McCullough Hyde Memorial Hospital) - Peritoneal mesothelioma
Ohio (Medical College of Ohio) - High-grade peritoneal serous carcinoma (primary peritoneal carcinoma)
Ohio (Valley Pathologists, Inc.) - Mesothelioma (3)
Pennsylvania (Conemaugh Memorial Medical Center) - Metastatic epithelial carcinoma, favor breast carcinoma
Pennsylvania (Lehigh Valley Hospital) - Poorly differentiated carcinoma involving ovarian
Pennsylvania (Mt. Nittany Medical Center) - Malignant mesothelioma with deciduoid features, peritoneum
Pennsylvania (Pennsylvania Hospital Pathology Residents) - Mesothelioma
Puerto Rico (University of Puerto Rico) - Mesothelioma
Texas, Lubbock - Desmoplastic small cell tumor
Texas (Propath Associates) - Poorly differentiated ovarian adenocarcinoma (2)
Texas (San Antonio) - Metastatic carcinoma (doubt mesothelioma)
Texas (Scott & White Memorial Hospital) - Epithelioid mesothelioma
West Virginia (Greenbrier Valley Medical Center) - Mesothelioma
Australia (North Queensland Pathology) - Epithelioid mesothelioma
Australia (Royal Prince Alfred Hospital) - High grade mesothelioma

Brazil (UNIFESP/EPM) - Malignant mesothelioma (2)
Canada (Woodstock General Hospital) - Mesothelioma, omentum
Germany, Hamburg - Mesothelioma
Hong Kong (Hong Kong Baptist Hospital) - Malignant mesothelioma
Italy, Naples - Malignant mesothelioma
Netherlands, Amsterdam - Malignant mesothelioma
Qatar (Hamad Medical Corporation) - Peritoneal epithelioid mesothelioma

Case 7 - Diagnosis:

High grade mesothelioma, peritoneum
T-87000, M-90503

Case 7 - References:

Ordonez NG. Role of Immunohistochemistry In Distinguishing Epithelial Peritoneal Mesotheliomas from Peritoneal and Ovarian Serous Carcinomas. *Am J Surg Pathol* 1998; 22(10):1203-1214.

Roberts F, Harper CM, Downie I, et al. Immunohistochemical Analysis Still Has a Limited Role in the Diagnosis of Malignant Mesothelioma. A Study of Thirteen Antibodies. *Am J Clin Pathol* 2001; 116(2):253-262.

Bailey ME, Brown RW, Mody DR, et al. Ber EP4 for Differentiating Adenocarcinoma from Reactive and Neoplastic Mesothelial Cells in Serous Effusions. Comparison with Carcinoembryonic Antigen, B72.3 and Leu-M1. *Acta Cytol* 1996; 40(6):1212-1216.

Sato S, Okamoto S, Ito K, et al. Differential Diagnosis of Mesothelial and Ovarian Cancer Cells in Ascites by Immunocytochemistry Using Ber-EP4 and Calretinin. *Acta Cytol* 200; 44(3):485-488.

Khoury N, Raju U, Crissman JD, et al. A Comparative Immunohistochemical Study of Peritoneal and Ovarian Serous Tumors, and Mesotheliomas. *Hum Pathol* 1990; 21(8):811-819.

Case No. 8, Accession No. 29840 May 2005

Alameda (Alameda County Medical Center) - Synovial sarcoma
Baldwin Park (Kaiser Permanente) - Synovial sarcoma, biphasic (3)
Fontana (Kaiser Permanente) - Synovial sarcoma
Glendale - Biphasic synovial sarcoma
Irvine (University of California Residents) - Synovial sarcoma
Long Beach - Synovial sarcoma, biphasic (7)
Monterey Park (Monterey Peninsula Residents) - Nodular tenosynovitis (1); Synovial sarcoma, biphasic (1)
Sacramento (UC Davis Medical Center Residents) - Biphasic synovial sarcoma
San Diego (Naval Medical Center) - Synovial sarcoma
San Francisco (San Francisco General Hospital) - Synovial sarcoma
Santa Barbara (Cottage Hospital) - Biphasic synovial sarcoma
Santa Rosa (Santa Rosa Memorial Hospital) - Synovial sarcoma, biphasic (3)
Ventura - Synovial sarcoma
Arizona (Maryvale Medical Center) - Synovial sarcoma
Colorado, Evergreen - Synovial sarcoma
Colorado (Lutheran Medical Center) - Synovial sarcoma
Connecticut - Synovial sarcoma, biphasic
Florida (Baptist Pathology) - Biphasic synovial sarcoma
Florida (Winter Haven Hospital) - Synovial sarcoma
Illinois, Burr Ridge - Synovial sarcoma
Indiana (Ball Memorial Hospital) - Synovial sarcoma
Indiana (Howard Community Hospital) - Synovial sarcoma
Louisiana (Louisiana State University Health Science Center) - Synovial sarcoma, biphasic
Maryland (National Naval Medical Center) - Synovial sarcoma
Maryland (University of Maryland Residents) - Synovial sarcoma, biphasic
Massachusetts (New England Medical Center) - Synovial sarcoma, biphasic type
Michigan (Oakwood Hospital) - Synovial sarcoma
Minnesota (Fairview Ridges Hospital) - Synovial sarcoma, biphasic

Nebraska (Creighton University School of Medicine) - Biphasic synovial sarcoma
New York (Presbyterian/Weill Cornell Campus) - Biphasic synovial sarcoma
New York (Stony Brook University Hospital Residents) - Ossifying synovial sarcoma
North Carolina (Mountain Area Pathology) - Synovial sarcoma (5)
Ohio (McCullough Hyde Memorial Hospital) - Synovial sarcoma
Ohio (Medical College of Ohio) - Biphasic synovial sarcoma (predominately epithelioid)
Ohio (Valley Pathologists, Inc.) - Synovial sarcoma (3)
Pennsylvania (Conemaugh Memorial Medical Center) - Synovial sarcoma, biphasic type
Pennsylvania (Lehigh Valley Hospital) - Biphasic synovial sarcoma
Pennsylvania (Mt. Nittany Medical Center) - Synovial sarcoma, knee
Pennsylvania (Pennsylvania Hospital Pathology Residents) - Biphasic synovial sarcoma
Puerto Rico (University of Puerto Rico) - Biphasic synovial sarcoma
Texas, Lubbock - Synoviosarcoma
Texas (Propath Associates) - Synovial sarcoma (1); Synovial, mixed pattern (1)
Texas (San Antonio) - Synovial sarcoma (biphasic)
Texas (Scott & White Memorial Hospital) - Synovial sarcoma
West Virginia (Greenbrier Valley Medical Center) - Synovial sarcoma
Australia (North Queensland Pathology) - Biphasic synoviosarcoma
Australia (Royal Prince Alfred Hospital) - Biphasic synovial sarcoma
Brazil (UNIFESP/EPM) - Synovial sarcoma (2)
Canada (Woodstock General Hospital) - Biphasic synovial sarcoma, knee
Germany, Hamburg - Synovial sarcoma
Hong Kong (Hong Kong Baptist Hospital) - Synovial sarcoma, biphasic type
Italy, Naples - Synovial sarcoma
Jamaica (University Hospital of the West Indies) - Synovial sarcoma
Netherlands, Amsterdam - Synoviosarcoma (biphasic)
Qatar (Hamad Medical Corporation) - Synovial sarcoma

Case 8 - Diagnosis:

Synovial sarcoma, biphasic knee
T-Y9200, M-90403

Case 8 – References:

dos Santos NR, de Bruijn DR, van Kessel AG, et al. Molecular Mechanisms Underlying Human Synovial Sarcoma Development of *Gene Chromosomes Cancer* 2001; 30(1):1-14.

Mietteneen M and Virtanen I. Synovial Sarcoma. A Misnomes. *Am J Pathol* 1984; 117(1); 18-25.

Cormier JN and Pollock RE. Soft Tissue Sarcomas. *CA Cancer J Clin* 2004; 54(2):94-109.

Nakasone J, Shimizu T, Gomyo H, et al. Assessment of Microinvasion with Reverse Transcriptase Polymerase Chain Reaction in a Case of Synovial Sarcoma. *J Orthop Sci* 2004; 9(2):162-165.

Weidner N, Goldman R and Johnson J et al. Epithelioid Monophasic Synovial Sarcoma. *Ultrastruct Pathol* 1993; 17(3-4):287-294.

Case No. 9, Accession No. 30205 **May 2005**

Alameda (Alameda County Medical Center) - Leiomyoma
Baldwin Park (Kaiser Permanente) - Leiomyoma (3)
Fontana (Kaiser Permanente) - Leiomyoma vs. peri-testicular spindle cell rhabdomyosarcoma
Glendale - Leiomyoma
Irvine (University of California Residents) - Angiomyoma
Long Beach - Leiomyoma (7)
Monterey Park (Monterey Peninsula Residents) - Leiomyoma (2)
Sacramento (UC Davis Medical Center Residents) - Leiomyoma
San Diego (Naval Medical Center) - Adenomatoid leiomyoma

San Francisco (San Francisco General Hospital) - Leiomyoma
Santa Barbara (Cottage Hospital) - Leiomyoma
Santa Rosa (Santa Rosa Memorial Hospital) - Spindle cell tumor consistent with leiomyoma (1); Leiomyoma (1)
Ventura - Fibrous pseudotumor
Arizona (Maryvale Medical Center) - Leiomyosarcoma
Colorado, Evergreen - Leiomyoma
Colorado (Lutheran Medical Center) - Leiomyoma
Connecticut - Spindle cell neoplasm, favor leiomyoma
Florida (Baptist Pathology) - Leiomyoma
Florida (Winter Haven Hospital) - Leiomyoma
Illinois, Burr Ridge - Cellular leiomyoma
Indiana (Ball Memorial Hospital) - Leiomyoma
Indiana (Howard Community Hospital) - Leiomyoma
Louisiana (Louisiana State University Health Science Center) - Leiomyoma
Maryland (National Naval Medical Center) - Leiomyoma
Maryland (University of Maryland Residents) - Leiomyoma
Massachusetts (New England Medical Center) - Leiomyoma
Michigan (Oakwood Hospital) - Leiomyoma
Minnesota (Fairview Ridges Hospital) - Leiomyoma
Nebraska (Creighton University School of Medicine) - Leiomyoma
New York (Presbyterian/Weill Cornell Campus) - Leiomyoma
New York (Stony Brook University Hospital Residents) - Atypical leiomyoma
North Carolina (Mountain Area Pathology) - Leiomyoma (5)
Ohio (McCullough Hyde Memorial Hospital) - Leiomyoma
Ohio (Medical College of Ohio) - Leiomyoma
Ohio (Valley Pathologists, Inc.) - Leiomyosarcoma (3)
Pennsylvania (Conemaugh Memorial Medical Center) - Paratesticular leiomyoma
Pennsylvania (Lehigh Valley Hospital) - Leiomyoma
Pennsylvania (Mt. Nittany Medical Center) - Scrotal leiomyoma
Pennsylvania (Pennsylvania Hospital Pathology Residents) - Leiomyoma
Puerto Rico (University of Puerto Rico) - Leiomyoma
Texas, Lubbock - Leiomyoma
Texas (Propath Associates) - Leiomyoma (2)
Texas (San Antonio) - Leiomyoma
Texas (Scott & White Memorial Hospital) - Leiomyoma
West Virginia (Greenbrier Valley Medical Center) - Unclassified sex cord-stromal tumor
Australia (North Queensland Pathology) - Sex cord stromal tumor spindle cell unclassified; DDx: parenchymal fibroma of gonadal stromal origin
Australia (Royal Prince Alfred Hospital) - Leiomyosarcoma, low grade
Brazil (UNIFESP/EPM) - Leiomyoma (2)
Canada (Woodstock General Hospital) - Leiomyoma, testis
Germany, Hamburg - Leiomyoma
Hong Kong (Hong Kong Baptist Hospital) - Leiomyoma
Italy, Naples - Leiomyoma
Jamaica (University Hospital of the West Indies) - Angioma/vascular leiomyoma
Netherlands, Amsterdam - Leiomyoma
Qatar (Hamad Medical Corporation) - Leiomyoma

Case 9 - Diagnosis:

Leiomyoma, paratesticular/scrotal
T-78000, M-88900

Case 9 – References:

Chiaramonte RM. Leiomyoma of Tunica Albuginea of Testis. *Urol* 1988; 31(4):344-345.

Longchampt E, Cariou G, Arborio M, et al. The Intratesticular Leiomyoma. An Unusual Location. Report of a Case. *Ann Pathol* 1998; 18(5):418-421.

Lia-Beng T, Wei-Wuang H, Biing-Rorn C, et al. Bilateral Synchronous Leiomyomas of the Testicular Tunica Albuginea. A Case Report and Review of the Literature. *Int Urol Nephrol* 1996; 28(4):549-552.

Nino-Murcia M. and Kosek J. Leiomyoma of the Testis. Sonographic and Pathologic Findings. *Can Assoc Radiol* J 1989; 40(3):178-179.

Srigley JR and Hartwick RW. Tumors and Cysts of the Paratesticular Region. *Pathol Annu* 1990; 25 (pt 2):51-108.

Case No. 10, Accession No. 29843 May 2005

Alameda (Alameda County Medical Center) - Chondrosarcoma

Baldwin Park (Kaiser Permanente) - Chondrosarcoma, grade 1 (1); Chondrosarcoma (1); Low grade chondrosarcoma arising in enchondroma (1)

Fontana (Kaiser Permanente) - Chondrosarcoma

Glendale - Low grade chondrosarcoma

Irvine (University of California Residents) - Chondrosarcoma

Long Beach - Chondrosarcoma, low-grade (7)

Monterey Park (Monterey Peninsula Residents) - Chondrosarcoma (2)

Sacramento (UC Davis Medical Center Residents) - Well-differentiated chondrosarcoma

San Diego (Naval Medical Center) - Chondrosarcoma, high grade

San Francisco (San Francisco General Hospital) - Well-differentiated chondrosarcoma

Santa Barbara (Cottage Hospital) - Chondrosarcoma, grade II/III

Santa Rosa (Santa Rosa Memorial Hospital) - Low-grade chondrosarcoma (2); Chondrosarcoma, well-differentiated (1)

Ventura - Chondrosarcoma

Arizona (Maryvale Medical Center) - Chondrosarcoma

Colorado, Evergreen - Chondrosarcoma

Colorado (Lutheran Medical Center) - Chondrosarcoma

Connecticut - Chondrosarcoma, low grade

Florida (Baptist Pathology) - Well-differentiated chondrosarcoma

Florida (Winter Haven Hospital) - Chondrosarcoma

Illinois, Burr Ridge - Chondrosarcoma

Indiana (Ball Memorial Hospital) - Chondrosarcoma

Indiana (Howard Community Hospital) - Chondrosarcoma

Louisiana (Louisiana State University Health Science Center) - Chondrosarcoma, low grade

Maryland (National Naval Medical Center) - Low grade chondrosarcoma

Maryland (University of Maryland Residents) - Chondrosarcoma

Massachusetts (New England Medical Center) - Chondrosarcoma

Michigan (Oakwood Hospital) - Low grade chondrosarcoma

Minnesota (Fairview Ridges Hospital) - Chondrosarcoma, low grade

Nebraska (Creighton University School of Medicine) - Low grade chondrosarcoma

New York (Presbyterian/Weill Cornell Campus) - Conventional chondrosarcoma, grade II

New York (Stony Brook University Hospital Residents) - Chondrosarcoma, grade 2-3

North Carolina (Mountain Area Pathology) - Low grade chondrosarcoma (4); Clear cell chondrosarcoma (1)

Ohio (McCullough Hyde Memorial Hospital) - Chondrosarcoma

Ohio (Medical College of Ohio) - Low-grade chondrosarcoma

Ohio (Valley Pathologists, Inc.) - Chondrosarcoma (2); Low-grade chondrosarcoma (1)

Pennsylvania (Conemaugh Memorial Medical Center) - Chondrosarcoma

Pennsylvania (Lehigh Valley Hospital) - Well-differentiated chondrosarcoma

Pennsylvania (Mt. Nittany Medical Center) - Central chondrosarcoma, sternum

Pennsylvania (Pennsylvania Hospital Pathology Residents) - Chondrosarcoma
Puerto Rico (University of Puerto Rico) - Chondrosarcoma, grade 2
Texas, Lubbock - Chondrosarcoma
Texas (Propath Associates) - Chondrosarcoma (2)
Texas (San Antonio) - Conventional chondrosarcoma with myxoid change, grade 2-3 of 3
Texas (Scott & White Memorial Hospital) - Chondrosarcoma
West Virginia (Greenbrier Valley Medical Center) - Chondrosarcoma
Australia (North Queensland Pathology) - Chondrosarcoma, low grade
Australia (Royal Prince Alfred Hospital) - Chondrosarcoma, grade II
Brazil (UNIFESP/EPM) - Well-differentiated chondrosarcoma (2)
Canada (Woodstock General Hospital) - Low-grade chondrosarcoma, sternum
Germany, Hamburg - Chondrosarcoma GII
Hong Kong (Hong Kong Baptist Hospital) - Chondrosarcoma, low grade
Italy, Naples - Low grade chondrosarcoma
Jamaica (University Hospital of the West Indies) - Chondrosarcoma
Netherlands, Amsterdam - Chondrosarcoma
Qatar (Hamad Medical Corporation) - Chondrosarcoma, well-differentiated

Case 10 - Diagnosis:

Low grade chondrosarcoma, sternum
T-78000, M-88900

Case 10 - References:

Athanassiadi K, Kalavrouziotis G, Rondogianni D, et al. Primary Chest Wall Tumors. Early and Long-Term Results of Surgical Treatment. *Eur J Cardiothorac Surg.* 2001; 19(5):589-593.

McAfee MK, Pairolero PC, Bergstralh EJ, et al. Chondrosarcoma of the Chest Wall. Factors Affecting Survival. *Ann Thorac Surg* 1985; 40(6):535-541.

Fong YC, Pairolero PC, Sim FH, et al. Chondrosarcoma of the Chest Wall. A Retrospective Clinical Analysis. *Clin Orthop* 2004; 427:184-189.