1184

CALIFORNIA
TUMOR TISSUE REGISTRY

"GYNECOLOGICAL PATHOLOGY"

Study Cases, Subscription A

March 2005

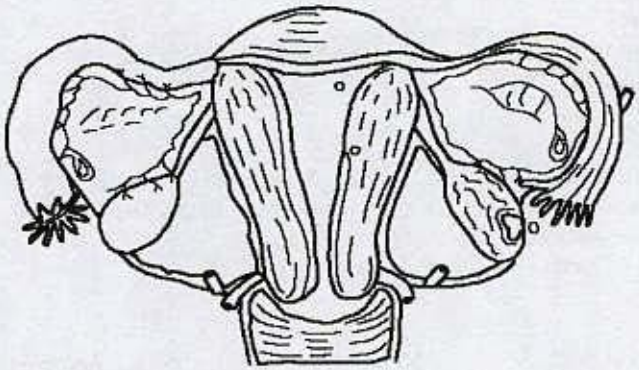

California Tumor Tissue Registry
c/o: Department of Pathology and Human Anatomy
Loma Linda University School of Medicine
11021 Campus Avenue, AH 335
Loma Linda, California 92350
(909) 558-4788
FAX: (909) 558-0188
E-mail: cttr@linkline.com
Web page: www.cttr.org
Web site & Case of the Month: www.cttr.org

Target audience:

Practicing pathologists and pathology residents.

Goal:

To acquaint the participant with the histologic features of a variety of benign and malignant neoplasms and tumor-like conditions.

Objectives:

The participant will be able to recognize morphologic features of a variety of benign and malignant neoplasms and tumor-like conditions and relate those processes to pertinent references in the medical literature.

Educational methods and media:

Review of representative glass slides with associated histories.
Feedback on consensus diagnoses from participating pathologists.
Listing of selected references from the medical literature.

Principal faculty:

Weldon K. Bullock, MD
Donald R. Chase, MD

CME Credit:

Loma Linda University School of Medicine designates this continuing medical education activity for up to 2 hours of Category I of the Physician's Recognition Award of the American Medical Association.

CME credit is offered for the subscription year only.

Accreditation:

Loma Linda University School of Medicine is accredited by the Accreditation Council for Continuing Medical Education (ACCME) to sponsor continuing medical education for physicians.

Contributor: Pamela Boswell, D.O.
San Diego, CA

Case No. 1 - March 2005

Tissue from: Right ovary

Accession #29464

Clinical Abstract:

This 15-year-old female had a 6-month history of a rapidly growing abdominal mass. A CT scan showed bilateral ovarian masses. The right ovarian mass was multiloculated.

Gross Pathology:

The 28.0 x 23. 0 x 10.5 right ovary was largely replaced by a single thin-walled cyst filled with thin red-brown fluid. Two solid foci were present, the largest measuring 5.0 x 4.0 x 2.0 cm. Cut surface of the solid areas showed focally gelatinous areas in focally solid yellow-tan and multicystic masses.

Contributor: Alexander K. Lyster, M.D.
Victoria, TX

Case No. 2 - March 2005

Tissue from: Left ovary

Accession #29301

Clinical Abstract:

A solid-cystic tumor was discovered, apparently originating from the left ovary of this 11-year-old female. The tumor was adherent to the omentum and the right adnexa.

Gross Pathology:

The ovarian tumor weighed about 2 kg. The 10.5 x 5.0 x 1.0 cm resected portion consisted of solid, gray-white tissue with focal hemorrhage and necrosis.

Contributor: Michael A. Favata, D.O.
San Diego, CA

Case No. 3 - March 2005

Tissue from: Left ovary

Accession #29453

Clinical Abstract:

During work-up for abdominal pain, this 16-year-old female was found to have a large abdominal/pelvic mass. Radiographic studies showed a 20 cm heterogeneous left adnexal mass.

Gross Pathology:

The 19.0 x 12.5 x 12.5 cm mass had a variegated, solid and cystic cut surface with evidence of necrosis.

Contributor: LLUMC Medical Group (rr)
Loma Linda, CA

Case No. 4 - March 2005

Tissue from: Ovary

Accession #30137

Clinical Abstract:

This 52-year-old female underwent hysterectomy and bilateral salpingo-oophorectomy because of a clinical diagnosis of uterine cancer.

Gross Pathology:

The 482 gram uterus had a yellow necrotic mass involving the myometrium and uterine serosa, extending from posterior fundus to the lower uterine segment. Both ovaries were enlarged by yellow, cystic, necrotic tumor which also encased the attached Fallopian tubes. The left ovary was 302 grams, and 13.7 x 13.1 x 4.7 cm. The right ovary was 142 grams, and 12.0 x 7.6 3.5 cm.

SPECIAL STUDIES:

Cytokeratin (AE1/AE3)	positive
Vimentin	negative
S100	negative

Contributor: LLUMC Pathology Group (mp) **Case No. 5 - March 2005**
Loma Linda, CA

Tissue from: Omentum & peritoneum **Accession #29397**

Clinical Abstract:

Four years earlier, this 28-year-old female had a laparoscopy for suspected endometriosis and a ruptured right ovarian cyst was removed. One year later she had a normal pregnancy. After the pregnancy, she continued to have chronic pelvic pain. She underwent a TAH/BSO with omentectomy and sampling of numerous peritoneal implants.

Gross Pathology:

Multiple hemorrhagic tumor nodules were up to 8 cm in greatest diameter.

Contributor: Kumari Wickramasinghe, M.D. **Case No. 6 - March 2005**
Lynwood, CA

Tissue from: Ovary **Accession #29396**

Clinical Abstract:

A non-pregnant 19-year-old female developed an abdominal mass.

Gross Pathology:

The left ovary consisted of a 13.0 x 8.5 x 3.0 cm cystic/solid mass with a bosselated yellow-tan to red surface.

Contributor: Kenneth A. Frankel, M.D.
Glendale, CA

Case No. 7 - March 2005

Tissue from: Left adnexa

Accession #29815

Clinical Abstract:

Some years after an abdominal hysterectomy with probable removal of the right adnexa, this 82-year-old female was found to have a left adnexal mass.

Gross Pathology:

The 98 gram, 9.0 x 8.0 x 5.5 cm partially disrupted pink-tan mass had an otherwise smooth external surface. The cut surface was a slightly variegated pale yellow with a 2.5 cm granular purple cystic area.

SPECIAL STUDIES (Outside facility):

Cytokeratin	positive
EMA	negative
ER	negative
Inhibin	positive

Contributor: Peter L. Morris, M.D.
Santa Barbara, CA

Case No. 8 - March 2005

Tissue from: Ovary

Accession #29780

Clinical Abstract:

During a physical examination, this 44-year-old gravida 6, para 3, female was noted to have a pelvic mass. Ultrasound revealed a complex ovarian cyst with a large solid component.

Gross Pathology:

The 700 gram, 13.0 x 7.0 x 6.0 cm ovary had a smooth surface except for a 2.0 x 1.0 cm region of surface papillations. The cut surface showed a large cyst as well as a 6.0 cm solid papillary region corresponding to the area of surface involvement. Foci of necrosis were also noted.

Contributor: Phillip C. Gordon, M.D.
Winter Haven, FL

Case No. 9 - March 2005

Tissue from: Right ovary

Accession #29879

Clinical Abstract:

This 62-year-old female presented with a large pelvic mass.

Gross Pathology:

The 1083 gram, 14.0 cm diameter, smooth-surfaced right ovary was filled with brown-tinged mucoid fluid. The inner surface of the cyst had multiple yellow-tan fleshy mucoid excrescences measuring up to 0.5 cm in thickness.

Contributor: Phillip C. Gordon, M.D.
Winter Haven, FL

Case No. 10 - March 2005

Tissue from: Left ovary

Accession #29794

Clinical Abstract:

Because of a history of fibroid uterus and atypical endometrial hyperplasia, this 59-year-old female underwent a total hysterectomy and BSO.

Gross Pathology:

The 775 gram, 14.0 x 11.5 x 7.0 cm left ovary was replaced by a flocculent pinkish blue cystic mass with an irregular bosselated surface. The cut surface showed multiple small and large cystic spaces containing viscous green mucoid material. Some solid tissue was present between the cystic spaces.

CALIFORNIA
TUMOR TISSUE REGISTRY

GYNECOLOGICAL PATHOLOGY

Minutes – Subscription A

March, 2005

SUGGESTED READING (General Topics from Recent Literature):

Where Does HIV Live? Justin Stebbing, M.D. Ph.D., Brian Gazzard, M.D. and Daniel C. Douek M.D. *New Eng J of Med* 2004; 350:1872-1880.

Invasive Micropapillary Carcinoma Very Aggressive. Clinicopathologic Study of 62 Cases of Poorly Recognized Variant With Highly Aggressive Behavior. Pettinato G, Manivel CJ, et al. *Am J Clin Pathol* 2004; 121:857-866.

Determination of DNA Ploidy by Fluorescence In-Situ Hybridization (FISH) in Hydatidiform Moles. Evaluation of FISH on Isolated Nuclei. Yver M, Carles D, et al. *Hum Pathol* 2004; 35:752-758.

C-Kit Expression in Sarcomatoid Renal Cell Carcinoma. Potential Therapy With Imatinib. Castillo M, Petit A, et al. *J Urol* 2004; 171:2176-2180.

Immunostaining for Human Herpesvirus 8 Latent Nuclear Antigen-1 Helps Distinguish Kaposi Sarcoma From Its Mimickers. *Am J Clin Pathol* 2004; 121:335-342.

California Tumor Tissue Registry
c/o: Department of Pathology and Human Anatomy
Loma Linda University School of Medicine
11021 Campus Avenue, AH 335
Loma Linda, California 92350
(909) 558-4788
FAX: (909) 558-0188
E-mail: cttr@linkline.com
Web site & Case of the Month: www.cttr.org

FILE DIAGNOSES

**(If possible, submit answers on website at www.cttr.org.
Click "subscriptions", then click submit answers.**

Case 1:

Struma ovarii
T-87000, M-90900

Case 2:

Mixed germ cell tumor with immature teratoma, ovary
T-87000, M-89400

Case 3:

Mixed Germ Cell Tumor (Yolk Sac and Dysgerminoma)
T-87000, M-86310

Case 4:

Clear cell adenocarcinoma, ovary
T-86910, M-83103

Case 5:

Granulosa cell tumor
T-63850, T-68000, M-95803

Case 6:

Sclerosing stromal tumor, ovary
T-87000, M-85901

Case 7:

Sertoli-Leydig cell tumor, ovary
T-86922, M-86310

Case 8:

Endometrioid carcinoma, low grade, ovary
T-87000, M-83803

Case 9:

Borderline papillary seromucinous tumor, ovary
T-87000, M-33740

Case 10:

Borderline mucinous tumor with focal invasion, ovary
T-87000, M-80001

Alameda (Alameda County Medical Center) - Struma ovarii
Baldwin Park (Kaiser Permanente) - Struma ovarii (3)
Fontana (Kaiser Permanente) - Struma ovarii
Fresno (St. Agnes Medical Center) - Struma ovarii
Glendale - Struma ovarii
Hayward/Fremont - Ovarian struma
Irvine (UC Davis Medical Center) - Struma ovarii
Irvine (University of California Irvine) - Struma ovarii
Laguna (Laguna Pathology Medical Group) - Struma ovarii
Long Beach (Lakewood Regional Medical Center) - Struma ovarii (9)
Monterey (Community Hospital of the Monterey Peninsula) - Struma ovarii
Monterey (Garfield Medical Center) - Struma ovarii
Mountain View (El Camino Pathology Group) - Struma ovarii
Orange (Orange County Medical Group) - Struma ovarii
San Diego (Naval Medical Center) - Struma ovarii
San Francisco (San Francisco General Hospital) - Mature cystic teratoma with struma ovarii
Santa Barbara (Cottage Hospital) - Struma ovarii
Santa Rosa (Santa Rosa Memorial Hospital) - Struma ovarii (3)
Ventura - Struma ovarii
Arizona, Phoenix - Struma ovarii
Colorada, Evergreen - Struma ovarii
Florida (Baptist Hospital) - Struma ovarii (5)
Florida (Munroe Regional Medical Center) - Struma ovarii
Florida (Pathology Associates) - Struma ovarii
Florida (Winter Haven Hospital) - Struma ovarii
Illinois - Struma ovarii
Illinois (Northwestern Memorial Hospital) - Struma ovarii
Illinois, Oak Brook - Struma ovarii
Indiana (Howard Community Hospital) - Struma ovarii
Maryland (Johns Hopkins Hospital Residents) - Struma ovarii
Maryland (National Naval Medical Center) - Struma ovarii
Maryland (University of Maryland) - Struma ovarii
New York (Long Island Jewish Medical Center) - Struma ovarii with infarction
New York (Stony Brook University Hospital Residents) - Struma ovarii
Louisiana (Louisiana State University Medical Center) - Struma ovarii
Massachusetts (New England Medical Center) - Struma Ovarii
Michigan - Struma ovarii
Michigan (Oakwood Hospital) - Struma ovarii
Michigan (Pathology Services of West Michigan) - Monodermal teratoma, thyroid
Minnesota (Fairview Ridges Hospital) - Monodermal teratoma, struma ovarii
Minnesota (Fairview Southdale Hospital) - Struma ovarii
Nebraska (Creighton University School of Medicine Residents) - Struma ovarii
New York (Nassau University Hospital Residents) - Struma ovarii
Ohio (Medical College of Ohio) - Monodermal teratoma (struma ovarii)
Pennsylvania (Allegheny General Hospital) - Struma ovarii
Pennsylvania (Conemaugh Memorial Medical Center) - Struma ovarii
Pennsylvania (Drexel University College of Medicine) - Struma ovarii
Pennsylvania (Lehigh Valley Hospital) - Struma ovarii
Pennsylvania (Mt. Nittany Medical Center) - Struma ovarii (monodermal mature cystic teratoma)
New York (Long Island Jewish Medical Center) - Struma ovarii with infarction
Ohio (McCullough Hyde Memorial Hospital) - Struma ovarii
Pennsylvania (Magee Women's Hospital) - Struma ovarii
Pennsylvania (Pennsylvania Hospital Pathology Residents) - Struma ovarii
Puerto Rico (University of Puerto Rico) - Struma ovarii
Texas, Lubbock - Struma ovary
Texas (Scott & White Memorial Hospital) - Struma ovarii
West Virginia (Greenbrier Valley Medical Center) - Struma ovarii
Wisconsin (Bellin Hospital) - Struma ovarii
Australia, Sydney - Struma ovarii
Brazil (UNIFESP/EPM) - Struma ovarii
Canada (Foothills Medical Center) - Struma ovarii

Canada (Woodstock General Hospital) - Struma ovarii
Germany, Hamburg - Struma ovarii
Hong Kong (Hong Kong Baptist Hospital) - Struma ovarii
Jamaica (University Hospital of West Indies) - Struma ovarii
Netherlands, Amsterdam - Monodermal teratoma (struma ovarii)
Qatar (Hamad Medical Corporation) - Struma ovarii

Case 1 - Diagnosis:

Struma ovarii

T-87000, M-90900

Case 1 – References:

Robboy SJ and Scully RE. Strumal Carcinoid of the Ovary. An Analysis of 50 Cases of a Distinctive Tumor Composed of Thyroid Tissue and Carcinoid. *Cancer* 1980; 46(9):2019-2034.

Szybelbein WM, et al. Cystic Struma Ovarii. A Frequently Unrecognized Tumor. A Report of 20 Cases. *Am J Surg Pathol* 1994; 18(8):785-788.

Young RH. New and Unusual Aspects of Ovarian Germ Cell Tumors. *Am J of Surg Pathol* 1993; 17(12):1210-1224.

Matsuda K, Maehama T and Kanazawa K. Malignant Struma Ovarii With Thyrotoxicosis. *Gynecol Oncol* 2001; 82(3):575-577.

Hemli JM, Barakate MS, Appleberg M, et al. Papillary Carcinoma of the Thyroid Arising in Struma Ovari—Report of a Case and Review of Management Guidelines. *Gynecol Endocrinol* 2001; 15(3):243-247.

Case No. 2, Accession No. 29301 March 2005

Alameda (Alameda County Medical Center) - Immature teratoma vs. Setoli-Leydig tumor with heterologous elements
Baldwin Park (Kaiser Permanente) - Immature teratoma (3)
Fontana (Kaiser Permanente) - Immature teratoma
Fresno (St. Agnes Medical Center) - Malignant teratoma with endodermal sinus tumor
Glendale - Yolk sac tumor and mature teratoma
Hayward/Fremont - Immature teratoma
Irvine (UC Davis Medical Center) - Mixed germ cell tumor, teratoma and yolk sac
Irvine (University of California Irvine) - Mixed germ cell tumor (immature teratoma and yolk sac tumor)
Laguna (Laguna Pathology Medical Group) - Immature teratoma
Long Beach (Lakewood Regional Medical Center) - Immature teratoma (9)
Monterey (Community Hospital of the Monterey Peninsula) - Immature teratoma
Monterey (Garfield Medical Center) - Endodermal sinus tumor (embryonal carcinoma)
Mountain View (El Camino Pathology Group) - Mixed germ cell tumor, immature teratoma and yolk sac tumor
Orange (Orange County Medical Group) - Malignant mixed germ cell tumor
San Diego (Naval Medical Center) - Mixed germ cell tumor (teratoma (immature, yolk sac tumor, dysgerminoma)
San Francisco (San Francisco General Hospital) - Mixed germ cell tumor
Santa Barbara (Cottage Hospital) - Malignant mixed germ cell tumor (immature teratoma, dysgerminoma, yolk sac tumor)
Santa Rosa (Santa Rosa Memorial Hospital) - Mixed germ cell neoplasm (teratoma) with endodermal sinus tumor (yolk sac tumor) (3)
Ventura - Immature teratoma
Arizona, Phoenix - Immature teratoma
Colorada, Evergreen - Immature teratoma/yolk sac tumor
Florida (Baptist Hospital) - Immature teratoma (5)
Florida (Munroe Regional Medical Center) - Yolk sac tumor
Florida (Pathology Associates) - Immature teratoma
Florida (Winter Haven Hospital) - Immature teratoma
Illinois - Immature teratoma
Illinois (Northwestern Memorial Hospital) - Malignant teratoma consistent with germ cell terato-carcinoma
Illinois, Oak Brook - Mature solid teratoma
Indiana (Howard Community Hospital) - Mature teratoma
Maryland (Johns Hopkins Hospital Residents) - Mixed germ cell tumor with teratoma and yolk sac components (2)
Maryland (National Naval Medical Center) - Teratoma with malignant transformation (carcinosarcoma)
Maryland (University of Maryland) - Mixed germ cell tumor and yolk sac/embryonal with mature teratoma
New York (Long Island Jewish Medical Center) - Yolk sac tumor
New York (Stony Brook University Hospital Residents) - Sertoli-Leydig cell tumor
Louisiana (Louisiana State University Medical Center) - Yolk sac tumor with immature elements

Massachusetts (New England Medical Center) - Immature teratoma
Michigan - Immature teratoma
Michigan (Oakwood Hospital) - Immature teratoma with possible endodermal sinus tumor
Michigan (Pathology Services of West Michigan) - Immature teratoma
Minnesota (Fairview Ridges Hospital) - Mixed germ cell tumor/Immature teratoma, yolk sac tumor
Minnesota (Fairview Southdale Hospital) - Immature teratoma
Nebraska (Creighton University School of Medicine Residents) - Mixed germ cell tumor vs. yolk sac tumor
New York (Nassau University Hospital Residents) - Immature teratoma, grade 2
Ohio (Medical College of Ohio) - Mixed germ cell tumor (immature teratoma and yolk sac tumor)
Pennsylvania (Allegheny General Hospital) - Mixed germ cell/yolk sac with teratoma
Pennsylvania (Conemaugh Memorial Medical Center) - Malignant teratoma/endodermal sinus tumor
Pennsylvania (Drexel University College of Medicine) - Yolk sac tumor, microcystic type and teratoma
Pennsylvania (Lehigh Valley Hospital) - Immature teratoma
Pennsylvania (Mt. Nittany Medical Center) - Malignant mixed germ cell tumor with teratoma and choriocarcinoma
New York (Long Island Jewish Medical Center) - Yolk sac tumor
Ohio (McCullough Hyde Memorial Hospital) - Malignant teratoma
Pennsylvania (Magee Women's Hospital) - Immature teratoma
Pennsylvania (Pennsylvania Hospital Pathology Residents) - Immature teratoma
Puerto Rico (University of Puerto Rico) - Mixed germ cell tumor/Yolk sac tumor/Sarcoma/Mature teratoma
Texas, Lubbock - Malignant teratoma
Texas (Scott & White Memorial Hospital) - Mixed germ cell tumor with immature teratoma and yolk sac
West Virginia (Greenbrier Valley Medical Center) - Teratoma, immature
Wisconsin (Bellin Hospital) - Immature teratoma
Australia, Sydney - Mixed yolk sac tumour/immature teratoma
Brazil (UNIFESP/EPM) - Mixed malignant germ cell tumor (immature teratoma with yolk sac tumor and embryonal carcinoma
Canada (Foothills Medical Center) - Immature teratoma
Canada (Woodstock General Hospital) - Mixed germ cell tumor with immature teratomatous and yolk sac tumor elements, ovary
Germany, Hamburg - Mixed germ cell tumor
Hong Kong (Hong Kong Baptist Hospital) - Mixed germ cell tumor (yolk sac tumor and immature teratoma)
Jamaica (University Hospital of West Indies) - Yolk-sac tumour, polyvesticular vitelline pattern, left ovary
Netherlands, Amsterdam - Malignant immature teratoma
Qatar (Hamad Medical Corporation) - Mixed germ cell tumor

Case 2 - Diagnosis:

Mixed Germ Cell Tumor With Immature Teratoma, Ovary
T-87000, M-89400

Case 2 - References:

Itani Y, Kawa M, Toyoda S, et al. Growing Teratoma Syndrome After Chemotherapy for a Mixed Germ Cell Tumor of the Ovary. *J Obstet Gynaecol Res* 2002; 28(3):166-171.

Tewari K, Cappuccini F, Disaia PJ, Berman ML, et al. Malignant Germ Cell Tumors of the Ovary. *Obstet Gynecol* 2000; 95(1):128-133.

Ulbright TM. Gonadal Teratomas. A Review and Speculation. *Adv Anat Pathol* 2004; 11(1):10-23.

Ohara N and Teramoto K. Ovarian Mixed Germ Cell Tumor Composed of Endodermal Sinus Tumor and Immature Teratoma. Case Report. *Clin Exp Obstet Gynecol* 2000; 27(2):95-96.

Kusamura S, Teixeira LC, dos Santos MA, et al. Ovarian Germ Cell Cancer. Clinicopatholoogic Analysis and Outcome of 31 Cases. *Tumori* 2000; 86(6):450-454.

Case No. 3, Accession No. 29453 March 2005

Alameda (Alameda County Medical Center) - Dysgerminoma
Baldwin Park (Kaiser Permanente) - Germ cell tumor, mixed (dysgerminoma and yolk sac tumor) (3)
Fontana (Kaiser Permanente) - Dysgerminoma and yolk sac tumor
Fresno (St. Agnes Medical Center) - Malignant germ cell tumor (endodermal sinus tumor and dysgerminoma)
Glendale - Yolk sac tumor and dysgerminoma
Hayward/Fremont - Mixed germ cell tumor/yolk sac and dysgerminoma

Irvine (UC Davis Medical Center) - Dysgerminoma

Irvine (University of California Irvine) - Mixed germ cell tumor with dysgerminoma and yolk sac tumor

Laguna (Laguna Pathology Medical Group) - Malignant mixed germ cell tumor vs. embryonal carcinoma vs. endodermal sinus tumor

Long Beach (Lakewood Regional Medical Center) - Mixed germ cell tumor (dysgerminoma with the yolk sac tumor) (9)

Monterey (Community Hospital of the Monterey Peninsula) - Yolk sac tumor

Monterey (Garfield Medical Center) - Endodermal sinus tumor (embryonal carcinoma)

Mountain View (El Camino Pathology Group) - Dysgerminoma

Orange (Orange County Medical Group) - Malignant mixed germ cell tumor

San Diego (Naval Medical Center) - Mixed germ cell tumor (dysgerminoma, yolk sac)

San Francisco (San Francisco General Hospital) - Mixed germ cell tumor

Santa Barbara (Cottage Hospital) - Mixed germ cell tumor, 80% dysgerminoma/20% yolk sac

Santa Rosa (Santa Rosa Memorial Hospital) - Mixed germ cell tumor with dysgerminoma and endodermal sinus tumor (3)

Ventura - Yolk sac tumor

Arizona, Phoenix - Mixed germ cell tumor, dysgerminoma and yolk sac tumor

Colorada, Evergreen - Dysgerminoma/yolk sac tumor

Florida (Baptist Hospital) - Dysgerminoma (1); Dysgerminoma with yolk sac (mixed GCT) (1); Dysgerminoma and endodermal sinus tumor (mixed GCT) (1); Mixed germ cell tumor (dysgerminoma and yolk sac) (2)

Florida (Munroe Regional Medical Center) - Dysgerminoma

Florida (Pathology Associates) - Pheochromocytoma

Florida (Winter Haven Hospital) - Mixed germ cell tumor

Illinois - Dysgerminoma

Illinois (Northwestern Memorial Hospital) - Mixed germ cell tumor, seminoma and yolk sac

Illinois, Oak Brook - Malignant mixed germ cell tumor

Indiana (Howard Community Hospital) - Clear cell carcinoma

Maryland (Johns Hopkins Hospital Residents) - Mixed germ cell tumor with yolk sac and dysgerminoma components (1); Dysgerminoma (possible yolk sac tumor component need immunos)

Maryland (National Naval Medical Center) - Mixed germ cell tumor with yolk sac embryonal and dysgerminoma

Maryland (University of Maryland) - Mixed germ cell tumor with dysgerminoma and yolk sac

New York (Long Island Jewish Medical Center) - Dysgerminoma

New York (Stony Brook University Hospital Residents) - Dysgerminoma/yolk sac tumor

Louisiana (Louisiana State University Medical Center) - Combined dysgerminoma and yolk sac tumor

Massachusetts (New England Medical Center) - Mixed germ cell tumor (dysgerminoma and embryonal)

Michigan - Dysgerminoma

Michigan (Oakwood Hospital) - Mixed germ cell tumor (dysgerminoma/endodermal sinus tumor)

Michigan (Pathology Services of West Michigan) - Malignant, ?malignant JGCT

Minnesota (Fairview Ridges Hospital) - Mixed germ cell tumor, dysgerminoma/yolk sac tumor

Minnesota (Fairview Southdale Hospital) - Mixed germ cell tumor with (yolk sac and dysgerminoma elements)

Nebraska (Creighton University School of Medicine Residents) - Embryonal carcinoma

New York (Nassau University Hospital Residents) - Mixed germ cell tumor

Ohio (Medical College of Ohio) - Dysgerminoma

Pennsylvania (Allegheny General Hospital) - Mixed germ cell, dysgerminoma with yolk sac

Pennsylvania (Conemaugh Memorial Medical Center) - Yolk sac tumor

Pennsylvania (Drexel University College of Medicine) - Dysgerminoma

Pennsylvania (Lehigh Valley Hospital) - Mixed malignant germ cell tumor

Pennsylvania (Mt. Nittany Medical Center) - Yolk sac tumor (endodermal sinus tumor)

New York (Long Island Jewish Medical Center) - Dysgerminoma

Ohio (McCullough Hyde Memorial Hospital) - Dysgerminoma

Pennsylvania (Magee Women's Hospital) - Yolk sac tumor

Pennsylvania (Pennsylvania Hospital Pathology Residents) - Sertoli Leydig cell tumor

Puerto Rico (University of Puerto Rico) - Mixed germ cell tumor, dysgerminoma and yolk sac

Texas, Lubbock - Dysgerminoma

Texas (Scott & White Memorial Hospital) - Mixed germ cell tumor with yolk sac and embryonal

West Virginia (Greenbrier Valley Medical Center) - Yolk sac tumor
Wisconsin (Bellin Hospital) - Dysgerminoma
Australia, Sydney - Mixed yolk sac tumour/dysgerminoma
Brazil (UNIFESP/EPM) - Mixed malignant germ cell tumor (dysgerminoma with endodermal sinus tumor)
Canada (Foothills Medical Center) - Mixed yolk sac tumor and dysgerminoma
Canada (Woodstock General Hospital) - Mixed germ cell tumor with yolk sac tumor, dysgerminoma, and embryonal carcinomatous elements, ovary
Germany, Hamburg - Mixed germ cell tumor
Hong Kong (Hong Kong Baptist Hospital) - Mixed germ cell tumor (dysgerminoma & yolk sac tumor)
Netherlands, Amsterdam - Dysgerminoma and in my slide probably a yolk sac tumor component
Qatar (Hamad Medical Corporation) - Yolk sac tumor

Case 3 - Diagnosis:

Mixed Germ Cell Tumor (Yolk Sac and Dysgerminoma)
(Directors Note: A minority of slides also showed embryonal carcinoma.) (drc)
T-87000, M-86310

Case 3 - References:

Gershenson DM, Del Junco G, Copeland LJ, et al. Mixed Germ Cell Tumors of the Ovary. *Obstet Gynecol* 1984; 64(2):200-206.
Kurman RJ and Norris HJ. Malignant Mixed Germ Cell Tumors of the Ovary. A Clinical and Pathological Analysis of 30 Cases. *Obstet Gynecol* 1976; 48(5):579-589.
Schwartz PE, Chambers SK, Chambers JT, et al. Ovarian Germ Cell Malignancies. The Yale University Experience. *Gyncol Oncol* 1992; 45(1):26-31.

Case No. 4, Accession No. 30137 March 2005

Alameda (Alameda County Medical Center) - Clear cell adenocarcinoma
Baldwin Park (Kaiser Permanente) - Clear cell carcinoma (3)
Fontana (Kaiser Permanente) - Clear cell carcinoma
Fresno (St. Agnes Medical Center) - Clear cell carcinoma
Glendale - Clear cell carcinoma
Hayward/Fremont - Clear cell carcinoma
Irvine (UC Davis Medical Center) - Clear cell carcinoma
Irvine (University of California Irvine) - Clear cell carcinoma
Laguna (Laguna Pathology Medical Group) - Clear cell carcinoma
Long Beach (Lakewood Regional Medical Center) - Clear cell carcinoma (9)
Monterey (Community Hospital of the Monterey Peninsula) - Clear cell carcinoma
Monterey (Garfield Medical Center) - Clear cell adenocarcinoma
Mountain View (El Camino Pathology Group) - Clear cell carcinoma
Orange (Orange County Medical Group) - Clear cell carcinoma of endometrium
San Diego (Naval Medical Center) - Clear cell carcinoma
San Francisco (San Francisco General Hospital) - Clear cell carcinoma
Santa Barbara (Cottage Hospital) - Clear cell carcinoma
Santa Rosa (Santa Rosa Memorial Hospital) - Clear cell carcinoma (3)
Ventura - Papillary serous adenocarcinoma
Arizona, Phoenix - Yolk sac tumor
Colorada, Evergreen - Clear cell carcinoma
Florida (Baptist Hospital) - Adenocarcinoma with clear cell and papillary features (1); High grade clear cell carcinoma (1); Clear cell adenocarcinoma (3)
Florida (Munroe Regional Medical Center) - Papillary serous carcinoma
Florida (Pathology Associates) - Clear cell carcinoma
Florida (Winter Haven Hospital) - Clear cell adenocarcinoma
Illinois - Papillary serous carcinoma
Illinois (Northwestern Memorial Hospital) - Clear cell carcinoma
Illinois, Oak Brook - Clear cell carcinoma
Indiana (Howard Community Hospital) - Papillary serous carcinoma
Maryland (Johns Hopkins Hospital Residents) - Clear cell adenocarcinoma (1); Clear cell carcinoma (1)
Maryland (National Naval Medical Center) - Carcinoma with serous and clear cell features

Maryland (University of Maryland) - Clear cell adenocarcinoma
New York (Long Island Jewish Medical Center) - Clear cell adenocarcinoma
New York (Stony Brook University Hospital Residents) - Clear renal cell carcinoma
Louisiana (Louisiana State University Medical Center) - Clear cell carcinoma
Massachusetts (New England Medical Center) - Clear cell carcinoma
Michigan - Clear cell carcinoma
Michigan (Oakwood Hospital) - Clear cell carcinoma
Michigan (Pathology Services of West Michigan) - Papillary serous carcinoma
Minnesota (Fairview Ridges Hospital) - Clear cell carcinoma
Minnesota (Fairview Southdale Hospital) - Clear cell carcinoma
Nebraska (Creighton University School of Medicine Residents) - Clear cell tumor
New York (Nassau University Hospital Residents) - Clear cell carcinoma
Ohio (Medical College of Ohio) - Clear cell carcinoma
Pennsylvania (Allegheny General Hospital) - Clear cell carcinoma
Pennsylvania (Conemaugh Memorial Medical Center) - Embryonal carcinoma
Pennsylvania (Drexel University College of Medicine) - Endometrial adenocarcinoma, clear cell type
Pennsylvania (Lehigh Valley Hospital) - Clear cell adenocarcinoma
Pennsylvania (Mt. Nittany Medical Center) - Clear cell carcinoma
New York (Long Island Jewish Medical Center) - Clear cell adenocarcinoma
Ohio (McCullough Hyde Memorial Hospital) - Papillary serous adenocarcinoma endometrium with mets to ovary
Pennsylvania (Magee Women's Hospital) - Clear cell carcinoma
Pennsylvania (Pennsylvania Hospital Pathology Residents) - Clear cell carcinoma
Puerto Rico (University of Puerto Rico) - Clear cell carcinoma
Texas, Lubbock - Clear cell carcinoma
Texas (Scott & White Memorial Hospital) - Clear cell carcinoma
West Virginia (Greenbrier Valley Medical Center) - Clear cell adenocarcinoma
Wisconsin (Bellin Hospital) - Clear cell carcinoma
Australia, Sydney - Clear cell carcinoma, predominantly villoglandular type
Brazil (UNIFESP/EPM) - Clear cell carcinoma
Canada (Foothills Medical Center) - Clear cell carcinoma
Canada (Woodstock General Hospital) - Clear cell carcinoma, ovary
Germany, Hamburg - Clear cell adenocarcinoma
Hong Kong (Hong Kong Baptist Hospital) - Clear cell adenocarcinoma
Jamaica (University Hospital of West Indies) - Serous carcinoma of endometrium, metastatic
Netherlands, Amsterdam - Clear cell carcinoma
Qatar (Hamad Medical Corporation) - Clear cell carcinoma of ovary

Case 4 - Diagnosis:

Clear cell adenocarcinoma, ovary
T-86910, M-83103

Case 4 - References:

Hayes MC and Scully RE. Ovarian Steroid Cell Tumor (Not Otherwise Specified). A Clinicopathological Analysis of 63 Cases. *Am J Surg Pathol* 1987; 11(11):835-845.

Dent J, Hall GD, Wilkinson N, et al. Cytogenetic Alterations in Ovarian Clear Cell Carcinoma Detected By Comparative Genomic Hybridization. *Br J Cancer* 2003; 88(10):1578-1583.

Tsuchiya A, Sakamoto M, Yasuda J, et al. Expression Profiling in Ovarian Clear Cell Carcinoma. Identification of Hepatocyte Nuclear Factor-1 Beta as a Molecular Marker and a Possible Molecular Target for Therapy of Ovarian Clear Cell Carcinoma. *Am J Pathol* 2003; 163(6):2503-2512.

Jimenez-Heffernan JA, Vicandi B, Gonzalez-Peramato P, et al. Cytologic Features of Clear Cell Carcinoma of the Female Genital Tract. Diagnostic Value of the "Raspberry Body" in Nonexfoliative Cytologic Specimens. *Acta Cytol* 2004; 48(1):47-51.

Fujimura M, Hidaka T, Kataoka K, et al. Absence of Estrogen Receptor-Alpha Expression in Human Ovarian Clear Cell Adenocarcinoma Compared with Ovarian Serous, Endometrioid, and Mucinous Adenocarcinoma. *Am J Surg Pathol* 2001; 25(5):667-672.

Case No. 5, Accession No. 29397 March 2005

Alameda (Alameda County Medical Center) - Adult granulosa cell tumor
Baldwin Park (Kaiser Permanente) - Granulosa cell tumor (3)
Fontana (Kaiser Permanente) - Granulosa cell tumor

Fresno (St. Agnes Medical Center) - Granulosa cell tumor
Glendale - Granulosa cell tumor, adult type
Hayward/Fremont - Adult granulosa cell tumor
Irvine (UC Davis Medical Center) - Granulosa cell tumor
Irvine (University of California Irvine) - Adult granulosa cell tumor
Laguna (Laguna Pathology Medical Group) - Granulosa cell tumor
Long Beach (Lakewood Regional Medical Center) - Granulosa cell tumor (9)
Monterey (Community Hospital of the Monterey Peninsula) - Granulosa cell tumor
Monterey (Garfield Medical Center) - Granulosa, Theca cell tumor
Mountain View (El Camino Pathology Group) - Granulosa cell tumor
Orange (Orange County Medical Group) - Granulosa cell tumor
San Diego (Naval Medical Center) - Adult granulosa cell tumor
San Francisco (San Francisco General Hospital) - Granulosa cell tumor
Santa Barbara (Cottage Hospital) - Granulosa cell tumor
Santa Rosa (Santa Rosa Memorial Hospital) - Granulosa cell tumor (3)
Ventura - Granulosa cell tumor
Arizona, Phoenix - Juvenile granulosa cell tumor
Colorada, Evergreen - Adult granulosa cell tumor
Florida (Baptist Hospital) - Granulosa cell tumor (5)
Florida (Munroe Regional Medical Center) - Granulosa cell tumor
Florida (Pathology Associates) - Granular cell tumor
Florida (Winter Haven Hospital) - Granulosa cell tumor
Illinois - Granulosa cell tumor
Illinois (Northwestern Memorial Hospital) - Granulosa cell tumor
Illinois, Oak Brook - Granular cell tumor, malignant
Indiana (Howard Community Hospital) - Granulosa cell tumor
Maryland (Johns Hopkins Hospital Residents) - Juvenile granulosa cell tumor (1); Granulosa cell tumor (1)
Maryland (National Naval Medical Center) - Adult granulosa cell tumor
Maryland (University of Maryland) - Adult granulosa cell tumor (can not rule out low grade endometrial stromal tumor)
New York (Long Island Jewish Medical Center) - Granulosa cell tumor
New York (Stony Brook University Hospital Residents) - Granulosa cell tumor
Louisiana (Louisiana State University Medical Center) - Granulosa cell tumor, adult type
Massachusetts (New England Medical Center) - Adult granulosa cell tumor
Michigan - Granulosa cell tumor
Michigan (Oakwood Hospital) - Granulosa cell tumor
Michigan (Pathology Services of West Michigan) - Adult granulosa cell tumor
Minnesota (Fairview Ridges Hospital) - Endometrioid stromal sarcoma, low grade
Minnesota (Fairview Southdale Hospital) - Granulosa cell tumor
Nebraska (Creighton University School of Medicine Residents) - Granulosa cell tumor
New York (Nassau University Hospital Residents) - Granulosa cell tumor
Ohio (Medical College of Ohio) - Granulosa cell tumor
Pennsylvania (Allegheny General Hospital) - Granulosa cell tumor, adult type
Pennsylvania (Conemaugh Memorial Medical Center) - Granulosa cell tumor
Pennsylvania (Drexel University College of Medicine) - Granulosa cell tumor
Pennsylvania (Lehigh Valley Hospital) - Granulosa cell tumor
Pennsylvania (Mt. Nittany Medical Center) - Granulosa cell tumor
New York (Long Island Jewish Medical Center) - Granulosa cell tumor
Ohio (McCullough Hyde Memorial Hospital) - Granulosa cell tumor
Pennsylvania (Magee Women's Hospital) - Granulosa cell tumor
Pennsylvania (Pennsylvania Hospital Pathology Residents) - Granulosa cell tumor
Puerto Rico (University of Puerto Rico) - Granulosa cell tumor
Texas, Lubbock - Granulosa cell tumor
Texas (Scott & White Memorial Hospital) - Granulosa cell tumor
West Virginia (Greenbrier Valley Medical Center) - Granulosa cell carcinoma
Wisconsin (Bellin Hospital) - Adult granulosa cell tumor
Australia, Sydney - Adult granulosa cell tumour
Brazil (UNIFESP/EPM) - Adult type granulosa cell tumor, malignant
Canada (Foothills Medical Center) - Adult granulosa cell tumor
Canada (Woodstock General Hospital) - Adult granulose cell tumor, omentum/peritoneum
Germany, Hamburg - Granulosa cell tumor
Hong Kong (Hong Kong Baptist Hospital) - Adult granulose cell tumor
Jamaica (University Hospital of West Indies) - Granulosa cell tumour of malignant Brenner tumour
Netherlands, Amsterdam - Sex cord stroma cell tumor (granulosa cell tumor)

Qatar (Hamad Medical Corporation) - Granulosa cell tumor

Case 5 - Diagnosis:

Granulosa cell tumor
T-63850, T-68000, M-95803

Case 5 - References:

Flemming P, Wellmann A, Maschek H, et al. Monoclonal Antibodies Against Inhibin Represent Key Markers of Adult Granulosa Cell Tumors of the Ovary Even in Their Metastases. A Report of Three Cases with Late Metastasis, Being Previously Misinterpreted as Hemangiopericytoma. *Am J Surg Pathol* 1995; 19(8):927-933.

Ayhan A, Tuncer ZS, Tuncer R, et al. Granulosa Cell Tumor of the Ovary. A Clinicopathological Evaluation of 60 Cases. *Eur J Gynaecol Oncol* 1994; 15(4):320-324.

Staibano S, Franco R, Mezza E, et al. Loss of Oestrogen Receptor Besa, High PCNA and p53 Expression and Aneuploidy as Markers of Worse Prognosis in Ovarian Granulosa Cell Tumors. *Histopathol* 2003; 43(3):254-262.

Robson M, Hensley M, Barakat R, et al. Quality of Life at Risk in Women for Ovarian Cancer Who Have Undergone Risk-Reducing Oophorectomy. *Gynecol Oncol* 2003; 89(2):281-287.

Case No. 6, Accession No. 29396 March 2005

Alameda (Alameda County Medical Center) - Sclerosing stromal tumor
Baldwin Park (Kaiser Permanente) - Leydig cell tumor (1); Sclerosing stromal tumor (2)
Fontana (Kaiser Permanente) - Sertoli-Leydig cell tumor
Fresno (St. Agnes Medical Center) - Sclerosing stromal tumor
Glendale - Sclerosing stromal tumor
Hayward/Fremont - Sertoli-Leydig cell tumor
Irvine (UC Davis Medical Center) - Embryonal carcinoma
Irvine (University of California Irvine) - Sex cord stroma tumor, NOS
Laguna (Laguna Pathology Medical Group) - Thecoma vs. Leydig cell tumor
Long Beach (Lakewood Regional Medical Center) - Sclerosing stromal tumor (9)
Monterey (Community Hospital of the Monterey Peninsula) - Sclerosing stromal tumor
Monterey (Garfield Medical Center) - Thecoma (Theca cell tumor)
Mountain View (El Camino Pathology Group) - Fibrothecoma
Orange (Orange County Medical Group) - Lipid cell tumor
San Diego (Naval Medical Center) - Sclerosing stromal tumor
San Francisco (San Francisco General Hospital) - Sclerosing stromal tumor
Santa Barbara (Cottage Hospital) - Juvenile granulosa cell tumor
Santa Rosa (Santa Rosa Memorial Hospital) - Sclerosing stromal tumor (3)
Ventura - Steroid cell tumor
Arizona, Phoenix - Sclerosing stromal tumor
Colorada, Evergreen - Juvenile granulosa cell tumor
Florida (Baptist Hospital) - Sclerosing stromal tumor (4); Sertolid cell tumor vs. sclerosing stromal tumor (would do inhibin) (1)
Florida (Munroe Regional Medical Center) - Thecoma
Florida (Pathology Associates) - Sclerosing stromal tumor
Florida (Winter Haven Hospital) - Sertoli cell tumor
Illinois - Granulosa-theca cell tumor
Illinois (Northwestern Memorial Hospital) - Sclerosing stromal tumor
Illinois, Oak Brook - Sclerosing stromal tumor
Indiana (Howard Community Hospital) - Sclerosing stromal tumor
Maryland (Johns Hopkins Hospital Residents) - Fibrothecoma (2)
Maryland (National Naval Medical Center) - Sclerosing stromal tumor
Maryland (University of Maryland) - Sex cord stromal tumor, unclassified
New York (Long Island Jewish Medical Center) - Malignant Sertoli-Leydig cell tumor
New York (Stony Brook University Hospital Residents) - Sclerosing stromal tumor
Louisiana (Louisiana State University Medical Center) - Sclerosing stromal tumor
Massachusetts (New England Medical Center) - Sclerosing stromal tumor (fibrothecoma)
Michigan - Thecoma
Michigan (Oakwood Hospital) - Sclerosing stromal tumor
Michigan (Pathology Services of West Michigan) - Sclerosing stromal tumor

Minnesota (Fairview Ridges Hospital) - Sclerosing stromal tumor
Minnesota (Fairview Southdale Hospital) - Sclerosing stromal tumor
Nebraska (Creighton University School of Medicine Residents) - Sclerosing stromal tumor
New York (Nassau University Hospital Residents) - Sclerosing stromal tumor
Ohio (Medical College of Ohio) - Sclerosing stromal tumor
Pennsylvania (Allegheny General Hospital) - Thecoma
Pennsylvania (Conemaugh Memorial Medical Center) - Sclerosing stromal tumor
Pennsylvania (Drexel University College of Medicine) - Juvenile granulosa cell tumor
Pennsylvania (Lehigh Valley Hospital) - Sclerosing stromal tumor
Pennsylvania (Mt. Nittany Medical Center) - Sclerosing stromal tumor
New York (Long Island Jewish Medical Center) - Malignant Sertoli-Leydig cell tumor
Ohio (McCullough Hyde Memorial Hospital) - Sertoli-Leydig cell tumor
Pennsylvania (Magee Women's Hospital) - Mixed sex cord stromal tumor
Pennsylvania (Pennsylvania Hospital Pathology Residents) - Stromal hyperthecosis
Puerto Rico (University of Puerto Rico) - Sclerosing stromal tumor of ovary
Texas, Lubbock - Steroid cell tumor
Texas (Scott & White Memorial Hospital) - Luteinized thecoma
West Virginia (Greenbrier Valley Medical Center) - Sclerosing stromal tumor
Wisconsin (Bellin Hospital) - Sclerosing stromal tumor
Australia, Sydney - Sclerosing stromal tumour
Brazil (UNIFESP/EPM) - Sclerosing stromal tumor
Canada (Foothills Medical Center) - Sclerosing stromal tumor
Canada (Woodstock General Hospital) - Sclerosing stroma tumor, ovary
Germany, Hamburg - Sclerosing stromal tumor
Hong Kong (Hong Kong Baptist Hospital) - Sclerosing stromal tumor
Jamaica (University Hospital of West Indies) - Benign clear cell adenofibroma
Netherlands, Amsterdam - Sex cord stroma cell tumor (steroid cell tumor)
Qatar (Hamad Medical Corporation) - Sclerosing stromal tumor

Case 6 - Diagnosis:

Sclerosing stromal tumor, ovary
T-87000, M-85901

Case 6 - References:

Tiltman AJ and Haffajee Z. Sclerosing Stromal Tumors, Thecomas, and Fibromas of the Ovary. An Immunohistochemical Profile. *Int J Gynecol Pathol* 1999; 18(3):254-258.

Stylianidou A, Varras M, Akrivis C, et al. Sclerosing Stromal Tumor of the Ovary. A Case Report and Review of the Literature. *Eur J Gynaecol Oncol* 2001; 22(4):300-304.

Mikami M, Kukuchi T, Takehara K, et al. Tumor Imprint Cytology of Sclerosing Stromal Tumor of the Ovary. *Diagn Cytopathol* 2003; 28(1):54-57.

Kawauchi S, Tsuji T, Kaku T, et al. Sclerosing Stromal Tumor of the Ovary. A Clinicopathologic, Immunohistochemical, Ultrastructural, and Cytogenetic Analysis with Special Reference to its Vasculature. *Am J Surg Pathol* 1998; 22(1):83-92.

Duska LR, Flynn C, and Goodman A. Masculinizing Sclerosing Stromal Cell Tumor in Pregnancy. Report of a Case and Review of the Literature. *Eur J Gynaecol Oncol* 1998; 19(5):441-443.

Case No. 7, Accession No. 29815 March 2005

Alameda (Alameda County Medical Center) - Sertoli-Leydig cell tumor
Baldwin Park (Kaiser Permanente) - Granulosa cell tumor (1); Sertoli-Leydig cell tumor (2)
Fontana (Kaiser Permanente) - Granulosa cell tumor
Fresno (St. Agnes Medical Center) - Granulosa cell tumor
Glendale - Poorly differentiated Sertoli-Leydig cell tumor
Hayward/Fremont - Sex cord stromal tumor
Irvine (UC Davis Medical Center) - Malignant sex cord stromal tumor
Irvine (University of California Irvine) - Sex cord stromal tumor, Sertoli-Leydig cell tumor
Laguna (Laguna Pathology Medical Group) - Granulosa cell tumor vs. Sertoli tumor (sex cord stromal tumor)
Long Beach (Lakewood Regional Medical Center) - Sertoli cell tumor (9)
Monterey (Community Hospital of the Monterey Peninsula) - Granulosa cell tumor
Monterey (Garfield Medical Center) - Granulosa cell tumor

Mountain View (El Camino Pathology Group) - Sertoli-Leydig cell tumor
Orange (Orange County Medical Group) - Sertoli-Leydig cell tumor, intermediate grade
San Diego (Naval Medical Center) - Adult granulosa cell tumor
San Francisco (San Francisco General Hospital) - Mixed granulosa and thecoma tumor
Santa Barbara (Cottage Hospital) - Sertoli-Leydig cell tumor
Santa Rosa (Santa Rosa Memorial Hospital) - Stromal tumor, unclassified (1); Poorly differentiated sex cord stromal tumor (1); Sex cord stromal tumor, unclassified type (1);
Ventura - Granulosa cell tumor
Arizona, Phoenix - Adult granulosa cell tumor
Colorada, Evergreen - Thecoma
Florida (Baptist Hospital) - Malignant sex cord tumor, NOS (1); Sex cord stromal tumor, NOS (3); Sertoli-Leydig cell tumor, intermediate grade (1)
Florida (Munroe Regional Medical Center) - Granulosa cell tumor
Florida (Pathology Associates) - Sertoli-Leydig cell tumor
Florida (Winter Haven Hospital) - Granulosa cell tumor
Illinois - Sertoli-Leydig tumor
Illinois (Northwestern Memorial Hospital) - Sertoli-Leydig cell tumor
Illinois, Oak Brook - Granular cell tumor
Indiana (Howard Community Hospital) - Granulosa cell tumor
Maryland (Johns Hopkins Hospital Residents) - Adult granulosa cell tumor (1); Intermediate differentiated Sertoli-Leydig cell tumor (1)
Maryland (National Naval Medical Center) - Sertoli-Leydig cell tumor, poorly differentiated
Maryland (University of Maryland) - Sertoli-Leydig cell tumor
New York (Long Island Jewish Medical Center) - Granulosa cell tumor
New York (Stony Brook University Hospital Residents) - Granulosa cell tumor
Louisiana (Louisiana State University Medical Center) - Sertoli-Leydig tumor (sarcomatoid type)
Massachusetts (New England Medical Center) - Sex cord stromal tumor
Michigan - Sertoli-Leydig cell tumor
Michigan (Oakwood Hospital) - Sertoli-Leydig cell tumor, moderate to poorly differentiated
Michigan (Pathology Services of West Michigan) - Thecoma
Minnesota (Fairview Ridges Hospital) - Sertoli-Leydig cell tumor
Minnesota (Fairview Southdale Hospital) - Sex cord tumor (favor granulosa cell type)
Nebraska (Creighton University School of Medicine Residents) - Sertoli cell tumor
New York (Nassau University Hospital Residents) - Sertoli-Leydig cell tumor
Ohio (Medical College of Ohio) - Poorly differentiated Sertoli-Leydig cell tumor
Pennsylvania (Allegheny General Hospital) - Sertoli-Leydig cell tumor
Pennsylvania (Conemaugh Memorial Medical Center) - Granulosa cell tumor
Pennsylvania (Drexel University College of Medicine) - Granulosa cell tumor
Pennsylvania (Lehigh Valley Hospital) - Granulosa cell tumor
Pennsylvania (Mt. Nittany Medical Center) - Granulosa cell tumor
New York (Long Island Jewish Medical Center) - Granulosa cell tumor
Ohio (McCullough Hyde Memorial Hospital) - Sertoli-Leydig cell tumor
Pennsylvania (Magee Women's Hospital) - Poorly differentiated Sertoli cell tumor
Pennsylvania (Pennsylvania Hospital Pathology Residents) - Low grade stromal sarcoma
Puerto Rico (University of Puerto Rico) - Sex cord tumor
Texas, Lubbock - Poorly differentiated Sertoli cell tumor
Texas (Scott & White Memorial Hospital) - Luteinized granulosa cell tumor
West Virginia (Greenbrier Valley Medical Center) - Poorly differentiated Sertoli cell tumor
Wisconsin (Bellin Hospital) - Sertoli-Leydig cell tumor
Australia, Sydney - Poorly differentiated Sertoli-Leydig cell tumour
Brazil (UNIFESP/EPM) - Poorly differentiated Sertoli-Leydig cell tumor
Canada (Foothills Medical Center) - Adult granulosa cell tumor
Canada (Woodstock General Hospital) - Sertoli-Leydig cell tumor of intermediate differentiated, ovary
Germany, Hamburg - Sertoli cell tumor
Hong Kong (Hong Kong Baptist Hospital) - Adult granulosa cell tumor
Jamaica (University Hospital of West Indies) - Granulosa cell tumour
Netherlands, Amsterdam - Lutinized thecoma with minor sex cord elements
Qatar (Hamad Medical Corporation) - Sertoli cell tumor

Case 7 - Diagnosis:

Sertoli-Leydig cell tumor, ovary
T-86922, M-86310

Case 7 - References:

De Santis M, Caruso LA, Rivasi F, et al. Poorly Differentiated Sertoli-Leydig Cell Tumor of the Ovary. Imaging with Pathologic Correlations. *Radiol Med* 2001; 102(3):192-194.

Kriplani A, Agarwal N, Roy KK, et al. Laparoscopic Management of Sertoli-Leydig Cell Tumors of the Ovary. A Report of Two Cases. *J Reprod Med* 2001; 46(5):493-496.

Sawetawan C, Rainey WE, Word RA, et al. Immunohistochemical and Biochemical Analysis of Human Sertoli-Leydig Cell Tumor. Autonomous Steroid Production Characteristic of Ovarian Theca Cells. *J Soc Gynecol Investig* 1995; 2(1):30-37.

Chao HT, Wang PH and Lin HD. Gonadotropin-Releasing Hormone-Agonist as a Neoadjuvant Therapy for Sertoli-Leydig Cell Tumors of the Ovary. *Int J Gynaecol Obstet* 1999; 66(2):189-190.

Case No. 8, Accession No. 29780 March 2005

Alameda (Alameda County Medical Center) - Endometrioid adenocarcinoma
Baldwin Park (Kaiser Permanente) - Endometrioid adenocarcinoma, ovary (2); Invasive endometrioid adenocarcinoma (1)
Fontana (Kaiser Permanente) - Endometrioid adenocarcinoma
Fresno (St. Agnes Medical Center) - Endometrioid carcinoma
Glendale - Endometrioid carcinoma with squamous differentiation
Hayward/Fremont - Endometrioid carcinoma
Irvine (UC Davis Medical Center) - Endometrioid carcinoma
Irvine (University of California Irvine) - Endometrioid adenocarcinoma
Laguna (Laguna Pathology Medical Group) - Endometrioid carcinoma
Long Beach (Lakewood Regional Medical Center) - Endometrioid carcinoma (9)
Monterey (Community Hospital of the Monterey Peninsula) - Endometrioid carcinoma
Monterey (Garfield Medical Center) - Low grade endometrioid carcinoma with low malignant potential
Mountain View (El Camino Pathology Group) - Endometrioid adenocarcinoma
Orange (Orange County Medical Group) - Well-differentiated endometrioid adenocarcinoma
San Diego (Naval Medical Center) - Endometrioid carcinoma
San Francisco (San Francisco General Hospital) - Endometrioid adenocarcinoma
Santa Barbara (Cottage Hospital) - Endometrioid carcinoma in endometrioid adenofibroma
Santa Rosa (Santa Rosa Memorial Hospital) - Endometrioid adenocarcinoma (3)
Ventura - Papillary serous adenocarcinoma
Arizona, Phoenix - Endometrioid carcinoma
Colorada, Evergreen - Atypical proliferative endometrioid tumor with squamous morules
Florida (Baptist Hospital) - Endometrioid carcinoma (3); Endometrioid adenocarcinoma (2)
Florida (Munroe Regional Medical Center) - Sex cord stromal tumor, Sertoli-Leydig
Florida (Pathology Associates) - Endometrioid adenocarcinoma
Florida (Winter Haven Hospital) - Sertoli-Leydig cell tumor
Illinois - Endometrioid carcinoma
Illinois (Northwestern Memorial Hospital) - Endometrioid adenocarcinoma
Illinois, Oak Brook - Endometrioid carcinoma, grade II
Indiana (Howard Community Hospital) - Endometrioid carcinoma
Maryland (Johns Hopkins Hospital Residents) - Endometrioid carcinoma, well-differentiated (1); Endometrioid adenocarcinoma (1)
Maryland (National Naval Medical Center) - Endometrioid adenocarcinoma
Maryland (University of Maryland) - Endometrioid carcinoma
New York (Long Island Jewish Medical Center) - Endometrioid adenocarcinoma
New York (Stony Brook University Hospital Residents) - Endometrioid carcinoma
Louisiana (Louisiana State University Medical Center) - Endometrioid carcinoma
Massachusetts (New England Medical Center) - Endometrioid carcinoma
Michigan - Endometrioid adenocarcinoma
Michigan (Oakwood Hospital) - Endometrioid carcinoma
Michigan (Pathology Services of West Michigan) - Endometrioid carcinoma
Minnesota (Fairview Ridges Hospital) - Endometrioid adenocarcinoma
Minnesota (Fairview Southdale Hospital) - Endometrioid carcinoma
Nebraska (Creighton University School of Medicine Residents) - Endometrioid adenocarcinoma

New York (Nassau University Hospital Residents) - Endometrioid carcinoma
Ohio (Medical College of Ohio) - Endometrioid carcinoma
Pennsylvania (Allegheny General Hospital) - Endometrioid carcinoma
Pennsylvania (Conemaugh Memorial Medical Center) - Mucinous cystadenocarcinoma
Pennsylvania (Drexel University College of Medicine) - Endometrioid carcinoma
Pennsylvania (Lehigh Valley Hospital) - Endometrioid adenocarcinoma
Pennsylvania (Mt. Nittany Medical Center) - Endometrioid carcinoma arising in an endometriotic cyst
New York (Long Island Jewish Medical Center) - Endometrioid adenocarcinoma
Ohio (McCullough Hyde Memorial Hospital) - Endometrioid adenocarcinoma
Pennsylvania (Magee Women's Hospital) - Endometrioid adenocarcinoma
Pennsylvania (Pennsylvania Hospital Pathology Residents) - Endometrioid adenocarcinoma
Puerto Rico (University of Puerto Rico) - Endometrioid carcinoma
Texas, Lubbock - Endometrioid carcinoma
Texas (Scott & White Memorial Hospital) - Endometrioid adenocarcinoma
West Virginia (Greenbrier Valley Medical Center) - Ovarian endometrioid adenocarcinoma
Wisconsin (Bellin Hospital) - Endometrioid carcinoma
Australia, Sydney - Well-differentiated endometrioid carcinoma of ovary with squamous differentiation
Brazil (UNIFESP/EPM) - Well-differentiated endometrioid adenocarcinoma with squamous differentiation
Canada (Foothills Medical Center) - Endometrioid adenocarcinoma
Canada (Woodstock General Hospital) - Endometrioid adenocarcinoma, ovary
Germany, Hamburg - Well-differentiated endometrioid adenocarcinoma
Hong Kong (Hong Kong Baptist Hospital) - Well-differentiated endometrioid adenocarcinoma and borderline endometrioid tumor
Jamaica (University Hospital of West Indies) - Endometrioid carcinoma, ovary
Netherlands, Amsterdam - Moderately differentiated endometrioid adenocarcinoma
Qatar (Hamad Medical Corporation) - Endometrioid adenocarcinoma of ovary

Case 8 - Diagnosis:

Endometrioid carcinoma, low grade, ovary
T-87000, M-83803

Case 8 – References:

Roth LM, Emerson RE and Ulbright TM. Ovarian Endometrioid Tumors of Low Malignant Potential. A Clinicopathologic Study of 30 Cases with Comparison to Well-Differentiated Endometrioid Adenocarcinoma. *Am J Surg Pathol* 2003; 27(9):1253-1259.

Ness RB. Endometriosis and Ovarian Cancer. Thoughts On Shared Pathophysiology. *Am J Obstet Gynecol* 2003; 189(1):280-294.

Hilders CG, Baranski AG, Peters L, et al. Successful Human Ovarian Autotransplantation to the Upper Arm. *Cancer* 2004; 101(12): 2771-2778.

Maida Y, Kyo S, Takakura M, et al. Ovarian Endometrioid Adenocarcinoma With Ectopic Production of Alpha-Fetoprotein. *Gynecol Oncol* 1998; 71(1):133-136.

Young RH and Hart WR. Metastatic Intestinal Carcinomas Simulating Primary Ovarian Clear Cell Carcinoma and Secretory Endometrioid Carcinoma. A Clinicopathologic and Immunohistochemical Study of Five Cases. *Am J Surg Pathol* 1998; 22(7):805-815.

Yonescu R, Currie JL, Hedrick L, et al. Chromosome Abnormalities In Primary Endometrioid Ovarian Carcinoma. *Cancer Genet Cytogenet* 1996; 87(2):167-171.

Case No. 9, Accession No. 29879 March 2005

Alameda (Alameda County Medical Center) - Mucinous cystic tumor, intestinal type, borderline
Baldwin Park (Kaiser Permanente) - Serous borderline tumor (3)
Fontana (Kaiser Permanente) - Borderline serous tumor
Fresno (St. Agnes Medical Center) - Borderline papillary serous carcinoma
Glendale - Mucinous tumor LMP
Hayward/Fremont - LMP serous carcinoma
Irvine (UC Davis Medical Center) - Mucinous borderline tumor
Irvine (University of California Irvine) - Papillary serous cystadenoma of LMP
Laguna (Laguna Pathology Medical Group) - Serous borderline tumor vs. mucinous LMP tumor, intestinal type
Long Beach (Lakewood Regional Medical Center) - Papillary serous tumor of low malignant potential (9)
Monterey (Community Hospital of the Monterey Peninsula) - Borderline tumor, mucinous vs. papillary serous
Monterey (Garfield Medical Center) - Low grade papillary serous cystic adenocarcinoma with low malignant potential
Mountain View (El Camino Pathology Group) - Serous borderline tumor

Orange (Orange County Medical Group) - Mixed mullerian epithelial tumor of LMP
San Diego (Naval Medical Center) - Mucinous tumor of low malignant potential (LMP)
San Francisco (San Francisco General Hospital) - Borderline papillary serous tumor
Santa Barbara (Cottage Hospital) - Mixed Mullerian borderline tumor with focal intra-epithelial carcinoma
Santa Rosa (Santa Rosa Memorial Hospital) - Borderline malignancy, papillary mucinous tumor (3)
Ventura - Papillary serous cystic tumor of borderline malignancy
Arizona, Phoenix - Borderline mucinous tumor
Colorada, Evergreen - Atypical proliferative mucinous tumor, seromucinous type
Florida (Baptist Hospital) - Atypical proliferative mucinous tumor (2); Borderline papillary serous tumor (3)
Florida (Munroe Regional Medical Center) - Borderline papillary tumor
Florida (Pathology Associates) - Borderline mucinous ovarian neoplasm
Florida (Winter Haven Hospital) - Mucinous papillary tumor of borderline malignant potential
Illinois - Borderline serous neoplasm
Illinois (Northwestern Memorial Hospital) - Borderline serous tumor
Illinois, Oak Brook - Borderline endometrioid tumor
Indiana (Howard Community Hospital) - Borderline papillary serous tumor
Maryland (Johns Hopkins Hospital Residents) - Atypical proliferative serous tumor (so-called borderline mucinous tumor) (1); Borderline tumor, mixed type (serous, mucinous, endometrioid) (1)
Maryland (National Naval Medical Center) - Serous tumor of unknown malignant potential
Maryland (University of Maryland) - Mixed sero-mucinous borderline tumor
New York (Long Island Jewish Medical Center) - Mucinous borderline tumor (Mullerian type)
New York (Stony Brook University Hospital Residents) - Borderline serous/mucinous mixed tumor
Louisiana (Louisiana State University Medical Center) - Borderline serous-mucinous tumor of ovary
Massachusetts (New England Medical Center) - Serous cystadenocarcinoma, borderline
Michigan - Papillary serous borderline tumor
Michigan (Oakwood Hospital) - Seromucinous borderline tumor (mucinous borderline tumor, endocervical type)
Michigan (Pathology Services of West Michigan) - Serous borderline tumor
Minnesota (Fairview Ridges Hospital) - Papillary serous tumor, borderline malignancy; Diff Dx: Mixed serous-mucinous tumor
Minnesota (Fairview Southdale Hospital) - Atypical proliferating mucinous tumor (borderline)
Nebraska (Creighton University School of Medicine Residents) - Borderline mucinous cystadenocarcinoma
New York (Nassau University Hospital Residents) - Borderline papillary serous tumor
Ohio (Medical College of Ohio) - Atypical proliferative serous tumor (borderline)
Pennsylvania (Allegheny General Hospital) - Papillary serous borderline tumor
Pennsylvania (Conemaugh Memorial Medical Center) - Borderline serous cystadenoma
Pennsylvania (Drexel University College of Medicine) - Atypical proliferative mucinous tumor with intraepithelial carcinoma
Pennsylvania (Lehigh Valley Hospital) - Mucinous neoplasm of low malignant potential
Pennsylvania (Mt. Nittany Medical Center) - Proliferating (borderline) serous tumor
New York (Long Island Jewish Medical Center) - Mucinous borderline tumor (Mullerian type)
Ohio (McCullough Hyde Memorial Hospital) - Borderline tumor
Pennsylvania (Magee Women's Hospital) - Borderline serous tumor
Pennsylvania (Pennsylvania Hospital Pathology Residents) - Serous papillary tumor, borderline
Puerto Rico (University of Puerto Rico) - Papillary serous cystadenoma, borderline
Texas, Lubbock - Serous cystadenoma of low malignant potential
Texas (Scott & White Memorial Hospital) - Borderline mucinous cystic tumor, endocervical type
West Virginia (Greenbrier Valley Medical Center) - Borderline mucinous tumor
Wisconsin (Bellin Hospital) - Serous papillary cystadenoma of borderline malignancy
Australia, Sydney - Mixed mucinous (endocervical type) and serous low-grade proliferative cystadenoma
Brazil (UNIFESP/EPM) - Atypical proliferative mucinous tumor, mullerian/endocervical type (seromucinous)
Canada (Foothills Medical Center) - Endocervical type mucinous borderline tumor
Canada (Woodstock General Hospital) - Seromucinous borderline tumor, ovary
Germany, Hamburg - Seromucinous atypical proliferative tumor (borderline)
Hong Kong (Hong Kong Baptist Hospital) - Mucinous borderline tumor, endocervical-like type
Jamaica (University Hospital of West Indies) - Atypical proliferative serous tumour, ovary
Netherlands, Amsterdam - Serous borderline tumor with some clear cell changes or focally mucinous change
Qatar (Hamad Medical Corporation) - Borderline serous cystadenoma

Case 9 - Diagnosis:

Borderline papillary seromucinous tumor, ovary
T-87000, M-33740

Case 9 – References:

Idotta R, Scopelliti P, Polimeni C, et al. Serous Papillary Cystic Ovarian Borderline Tumor. Case Report. *Clin Exp Obstet Gynecol* 2002; 29(4):293-296.

Siriaunkgul S, Robbins KM, Mc Gowan L, et al. Ovarian Mucinous Tumors of Low Malignant Potential. A Clinicopathologic Study of 54 Tumors of Intestinal and Mullerian Type. *Int J Gynecol Pathol* 1995; 14(3):198-208.

Lee KR and Young RH. The Distinction Between Primary and Metastatic Mucinous Carcinomas of the Ovary. Gross and Histologic Findings in 50 Cases. *Am J Surg Pathol* 2003; 27(3):281-292.

Kohlberger P, Muller-Klingspor V, Heinzl H, et al. Prognostic Value of Laminin-5 in Serous Adenocarcinomas of the Ovary. *Anticancer Res* 2002; 22(6B):3541-3544.

Mink PJ, Sherman ME and Devesa SS. Incidence Patterns of Invasive and Borderline Ovarian Tumors Among White Women and Black Women in the United States. Results from the SEER Program 1978-1998. *Cancer* 2002; 95(11):2380-2389.

Case No. 10, Accession No. 29794 March 2005

Alameda (Alameda County Medical Center) - Mucinous cystic tumor, endocervical type borderline
Baldwin Park (Kaiser Permanente) - Mucinous borderline tumor (2); Mucinous cystadenoma (1)
Fontana (Kaiser Permanente) - Borderline mucinous tumor
Fresno (St. Agnes Medical Center) - Borderline mucinous tumor
Glendale - Mucinous tumor LMP
Hayward/Fremont - LMP mucinous carcinoma, intestinal type
Irvine (UC Davis Medical Center) - Mucinous borderline tumor
Irvine (University of California Irvine) - Mucinous cystadenoma of LMP, intestinal type
Laguna (Laguna Pathology Medical Group) - Mucinous adenocarcinoma
Long Beach (Lakewood Regional Medical Center) - Papillary mucinous tumor of low malignant potential (9)
Monterey (Community Hospital of the Monterey Peninsula) - Mucinous tumor (primary vs. metastatic)
Monterey (Garfield Medical Center) - Low grade papillary mucinous cystadenocarcinoma with low malignant potential
Mountain View (El Camino Pathology Group) - Mucinous borderline tumor
Orange (Orange County Medical Group) - Mucinous tumor of LMP, endocervical type
San Diego (Naval Medical Center) - Mucinous LMP vs. mucinous LMP with intra-epithelial carcinoma
San Francisco (San Francisco General Hospital) - Borderline multiloculated mucinus tumor
Santa Barbara (Cottage Hospital) - Mucinous borderline neoplasm, intestinal type
Santa Rosa (Santa Rosa Memorial Hospital) - Low-grade mucinous cystadenoma vs. borderline mucinous papillary tumor (1); Low-grade mucinous cystadenocarcinoma (1); Well-differentiated mucinous cystadenocarcinoma, intestinal type (1)
Ventura - Mucinous cystic tumor of borderline malignancy
Arizona, Phoenix - Mucinous carcinoma
Colorada, Evergreen - Mucinous carcinoma
Florida (Baptist Hospital) - Mucinous ovarian carcinoma (1); Atypically proliferating mucinous tumor, borderline carcinoma (1); Borderline mucinous tumor (3)
Florida (Munroe Regional Medical Center) - Borderline mucinous tumor with intraepithelial carcinoma
Florida (Pathology Associates) - Mucinous carcinoma
Florida (Winter Haven Hospital) - Well-differentiated mucinous cystadenocarcinoma
Illinois - Mucinous cystadenocarcinoma
Illinois (Northwestern Memorial Hospital) - Borderline mucinous tumor
Illinois, Oak Brook - Mucinous borderline tumor
Indiana (Howard Community Hospital) - Borderline mucinous tumor
Maryland (Johns Hopkins Hospital Residents) - Atypical proliferative mucinous tumor (so-called borderline mucinous tumor) (1); Mucinous borderline cystadenoma (rule out metastasis) (1)
Maryland (National Naval Medical Center) - Mucinous cystadenocarcinoma
Maryland (University of Maryland) - Mucinous borderline tumor, intestinal type
New York (Long Island Jewish Medical Center) - Mucinous adenocarcinoma in-situ, borderline
New York (Stony Brook University Hospital Residents) - Borderline mucinous tumor, intestinal type, with focal intraepithelial carcinoma
Louisiana (Louisiana State University Medical Center) - Borderline mucinous tumor of ovary
Massachusetts (New England Medical Center) - Mucinous adenocarcinoma
Michigan - Mucinous borderline tumor
Michigan (Oakwood Hospital) - Mucinous borderline tumor, intestinal type
Michigan (Pathology Services of West Michigan) - Mucinous cystadenocarcinoma
Minnesota (Fairview Ridges Hospital) - Mucinous cystic tumor, borderline malignancy
Minnesota (Fairview Southdale Hospital) - Borderline mucinous tumor