1171

CALIFORNIA
TUMOR TISSUE REGISTRY

"GENERAL PATHOLOGY"

Study Cases, Subscription A

September, 2003

California Tumor Tissue Registry
c/o: Department of Pathology and Human Anatomy
Loma Linda University School of Medicine
11021 Campus Avenue, AH 335
Loma Linda, California 92350
(909) 558-4788
FAX: (909) 558-0188
E-mail: cttr@linkline.com
Web page: www.cttr.org
Web site & Case of the Month: www.cttr.org

Target audience:

Practicing pathologists and pathology residents.

Goal:

To acquaint the participant with the histologic features of a variety of benign and malignant neoplasms and tumor-like conditions.

Objectives:

The participant will be able to recognize morphologic features of a variety of benign and malignant neoplasms and tumor-like conditions and relate those processes to pertinent references in the medical literature.

Educational methods and media:

Review of representative glass slides with associated histories.
Feedback on consensus diagnoses from participating pathologists.
Listing of selected references from the medical literature.

Principal faculty:

Weldon K. Bullock, MD
Donald R. Chase, MD

CME Credit:

Loma Linda University School of Medicine designates this continuing medical education activity for up to 2 hours of Category I of the Physician's Recognition Award of the American Medical Association.

CME credit is offered for the subscription year only.

Accreditation:

Loma Linda University School of Medicine is accredited by the Accreditation Council for Continuing Medical Education (ACCME) to sponsor continuing medical education for physicians.

Contributor: LLUMC Pathology Group (md)
Loma Linda, CA

Case No. 1 - September 2003

Tissue from: Small bowel

Accession #28766

Clinical Abstract:

After three months of increasing left-sided scrotal swelling, this 55-year-old male presented for examination. A 5.5 cm left testicular mass was found on ultrasound and an orchiectomy was performed. Work-up showed evidence of metastatic disease in the bone marrow, stomach, small bowel and mesentery, and supraclavicular soft tissue. Portions of perforated small bowel was resected.

Gross Pathology:

The 92 gram segment of small bowel included a 5.0 x 4.0 x 2.5 cm mass within the mesentery. The cut surface showed yellow-tan homogeneous parenchyma that eroded into the small bowel mucosa.

Contributor: Kenneth Frankel, M.D.
Glendale, CA

Case No. 2 - September 2003

Tissue from: Left thyroid

Accession #29688

Clinical Abstract:

This 53-year-old female had an enlarging left thyroid mass.

Gross Pathology:

The 30.5 gram thyroid gland was 6.1 x 3.5 x 2.9 cm. The parenchyma contained several nodules up to 1.2 cm in greatest diameter.

SPECIAL STUDIES:

Calcitonin negative

Contributor: Phillip C. Gordon, M.D.
Winter Haven, FL

Case No. 3 - September 2003

Tissue from: Mediastinum

Accession #29358

Clinical Abstract:

Because of vague chest discomfort, this 41-year-old female had a chest x-ray which revealed a mediastinal mass.

Gross Pathology:

The 12.0 x 8.0 cm specimen included a 4.0 cm encapsulated mass.

SPECIAL STUDIES:

Cytokeratin	epithelial cells positive
LCA	lymphoid cells positive

Contributor: Pamela Boswell, D.O.
San Diego, CA

Case No. 4 - September 2003

Tissue from: Right upper lobe of lung

Accession #29392

Clinical Abstract:

A 65-year-old male with a history of cigarette smoking presented with a right upper lobe lung mass.

Gross Pathology:

The 18.5 x 10.0 x 8.0 cm portion of lung, with attached sections of ribs, included an 8.0 x 5.0 x 5.0 cm necrotic tumor in the inferior portion of the right upper lobe.

Contributor: Philip Robinson, M.D.
Boynton Beach, FL

Case No. 5 - September 2003

Tissue from: Left lower lung

Accession #29053

Clinical Abstract:

This 87-year-old male was found to have a mass in his left lower lung.

Gross Pathology:

The 330 gram lung specimen was 19.5 x 11.5 x 4.5 cm. It contained a 7.0 x 6.0 x 2.0 cm pink, mucinous tumor infiltrating the visceral pleura.

Contributor: David Shimizu, M.D.
Honolulu, HI

Case No. 6 - September 2003

Tissue from: Left knee

Accession #29448

Clinical Abstract:

Following a two-year history of a mass in his left knee, this 68-year-old male had an MRI which showed a heterogeneous enhancing mass.

Gross Pathology:

A 6.4 x 6 x 3 cm ovoid lobulated myxoid mass was present within skeletal muscle.

SPECIAL STUDIES:

Vimentin	positive
Cytokeratin	negative
EMA	negative
S-100	negative

Contributor: Douglas G. Hoffman, M.D.
Atlanta, GA

Case No. 7 - September 2003

Tissue from: Falx cerebri

Accession #29469

Clinical Abstract:

After a long history of headaches, this 30-year-old female had a radiologic study showing a bifrontal neoplasm. At surgery, the mass was found to be attached to the falx cerebri and was very firm.

Gross Pathology:

The 7.0 cm mass consisted of glistening firm pink-white tissue.

Contributor: John McGill, M.D.
Pasadena, CA

Case No. 8 - September 2003

Tissue from: Left testis

Accession #29451

Clinical Abstract:

For two to three months this 41-year-old male noticed an enlarging firm mass in his left testicle.

Gross Pathology:

The 60 gram testis was largely replaced by a 5.5 x 3.5 x 2.8 cm homogeneous tan mass.

Contributor: Diane Rogers, M.D.
Lynwood, CA

Case No. 9 - September 2003

Tissue from: Left breast

Accession #29160

Clinical Abstract:

This 83-year-old female noted a rapid growing mass in her left breast. Mammogram showed abnormal calcifications, suspicious for malignancy.

Gross Pathology:

The 3.5 x 3.0 x 3.0 cm firm, tan-white mass was covered by a thin layer of fat.

SPECIAL STUDIES:

SMA	positive
Cytokeratin	negative

Contributor: W.P. Illig, M.D.
Tulsa, OK

Case No. 10 - September 2003

Tissue from: Left frontal fossa

Accession #29115

Clinical Abstract:

Three years earlier, this 59-year-old male had had a resection of a left frontal fossa tumor attached to the dura. The tumor recurred and was again excised. The study material is from the recurrence.

Gross Pathology:

The 70 gram mass was 9.0 x 8.0 x 2.0 cm.

SPECIAL STUDIES:

EMA	positive
S-100	negative
Keratin	negative
Mucin	weak positivity

CALIFORNIA
TUMOR TISSUE REGISTRY

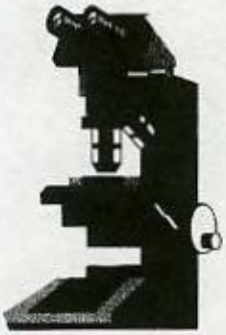

GENERAL PATHOLOGY

Minutes – Subscription A

September, 2003

SUGGESTED READING (General Topics from Recent Literature):

Stem Cell Research: Elephants in the Room. Theise ND. *Mayo Clin Proc* 2003;78(8):1004-1009.
Tumor-Busting Viruses. Nettelbeck DM and Curiel DT. *Scientific American* 2003; 289(4):68-75.
Bioinformatics Programmed for Success. Buckingham S. *Nature* 2003; 425(6954):209-215.
Cardiovascular Disease. Nabel, EG. *N Engl J Med* 2003; 349(1):60-72.
Welcome to the Genomic Era. Guttmacher AE and Collins FS. *N Eng J Med* 2003; 349(10):996-998.
Genomics as a Probe for Disease Biology. Burke W. *N Eng J Med* 2003; 349(10):969-974.

California Tumor Tissue Registry
c/o: Department of Pathology and Human Anatomy
Loma Linda University School of Medicine
11021 Campus Avenue, AH 335
Loma Linda, California 92350
(909) 558-4788
FAX: (909) 558-0188
E-mail: cttr@linkline.com
Web site & Case of the Month: www.cttr.org

FILE DIAGNOSES

CTTR Subscription A **September 2003**

Case 1:

Diffuse high grade large cell lymphoma, small bowel
T-64000, M-95903

Case 2:

Poorly differentiated (insular) carcinoma, thyroid
T-96200, M-80103

Case 3:

Thymoma
T-Y2300, M-85800

Case 4:

Squamous cell carcinoma, lung
T-28000, M-80703

Case 5:

Mucinous bronchioloalveolar carcinoma, lung
T-28000, M-82503

Case 6:

Extraskeletal myxoid chondrosarcoma, knee
T-Y9200, M-92203

Case 7:

Chondroma, falx cerebri
T-X1140, M-92200

Case 8:

Seminoma, testis
T-78000, M-90613

Case 9:

Myofibroblastoma, breast
T-04000, M-95800

Case 10:

Chordoid meningioma, frontal fossa
T-Y0111, M-95300

Case No. 1, Accession No. 28766 **September 2003**

Alameda (Alameda County Medical Center) - Large cell lymphoma
Bakersfield - Metastatic seminoma
Baldwin Park (Kaiser Permanente) - Lymphoma (3)
Fontana (Kaiser Permanente) - Large cell lymphoma
Hayward/Fremont - Malignant lymphoma, diffuse large (B) cell type
Laguna Beach (South Coast Medical Center) - High grade germ cell tumor (embryonal carcinoma, solid pattern) versus other poorly differentiated neoplasm (lymphoma)
Loma Linda (Loma Linda University Residents) - Metastatic anaplastic carcinoma, favor seminoma
Long Beach - Diffuse large cell lymphoma (8)
Mountain View (El Camino Pathology Group) - Diffuse large cell lymphoma
Orange (Orange County Pathology Medical Group) - Non-Hodgkins lymphoma
Orange (UCI Medical Center Residents) - Diffuse large cell lymphoma
Sacramento (UC Davis Medical Center) - Large cell lymphoma
San Diego (Naval Medical Center) - Large cell lymphoma
San Francisco (San Francisco General Hospital) - Lymphoma, anaplastic
Santa Barbara (Cottage Hospital) - Large cell lymphoma
Santa Rosa (Santa Rosa Memorial Hospital) - Diffuse large cell malignant lymphoma (3)
Ventura - Seminoma
Alaska (Alaska Native Medical Center) - Embryonal carcinoma (2); High grade large B-cell lymphoma (1)
Arizona (Maryvale Medical Center) - Seminoma, metastatic from left testicle
Arizona (St. Josephs Hospital Residents) - Large cell non-Hodgkin's lymphoma/anaplastic large cell lymphoma
Florida (Baptist Hospital) - Choriocarcinoma (1); Metastatic anaplastic seminoma (rule out melanoma) (1)
Florida (Munroe Regional Medical Center) - Large cell lymphoma
Florida (Pathology Associates) - Large cell lymphoma
Florida (Winter Haven Hospital) - Large cell lymphoma
Illinois (Northwestern Memorial Hospital) - Embryonal carcinoma
Louisiana (Louisiana State University Medical Center) - Malignant lymphoma, large cell
Maryland (National Naval Medical Center) - Malignant lymphoma (11)
Massachusetts (Berkshire Medical Center) - Seminoma (8); vs. Lymphoma (1)
Massachusetts (New England Medical Center Residents) - Diffuse large cell lymphoma
Michigan (Oakwood Hospital) - B-cell non-Hodgkin's lymphoma, diffuse vs. follicular large
Michigan (St. Joseph Mercy Hospital) - Follicular lymphoma, grade III
Minnesota (Fairview Southdale Hospital) - Large cell lymphoma
Mississippi (University of Mississippi Medical Center) - Malignant lymphoma
Nebraska (Creighton University School of Medicine Residents) - Large cell lymphoma
Nevada (Western Pathology Associates) - Large cell lymphoma
New Jersey (Overlook Hospital) - Large cell lymphoma, diffuse
New York (Long Island Jewish Medical Center) - Diffuse large cell lymphoma
New York (Nassau University Medical Center) - Diffuse large cell lymphoma
New York (New York Presbyterian Hospital Residents) - Diffuse large cell lymphoma
New York (Stony Brook University Hospital Residents) - Diffuse large cell lymphoma
North Carolina (Duke University Medical Center Residents) - Seminoma
Ohio (Medical College of Ohio Residents) - Non-Hodgkin's lymphoma, large cell type
Oklahoma (Tulsa) - Malignant large cell lymphoma
Oklahoma (University of Oklahoma HSC Residents) - Malignant lymphoma
Pennsylvania (Allegheny General Hospital) - Large cell lymphoma
Pennsylvania (Centre Community Hospital) - Diffuse large B-cell lymphoma
Pennsylvania (Conemaugh Memorial Medical Center) - Lymphoma
Pennsylvania (Drexel University College of Medicine) - Anaplastic large cell lymphoma
Pennsylvania (Lehigh Valley Hospital) - Large cell lymphoma vs. seminoma
Pennsylvania (York Hospital) - Malignant neoplasm: Diffuse B-cell lymphoma vs. seminoma

Puerto Rico (University of Puerto Rico) - Germ cell tumor, anaplastic seminoma/embryonal carcinoma
Rhode Island (RI Hospital Residents) - Diffuse large cell lymphoma
Texas (Lackland AFB) - Metastatic germ cell tumor, seminoma (less likely lymphoma)
Texas (Propath Associates) - Large cell lymphoma (2)
Texas (Scott & White Memorial Hospital) - Large cell lymphoma
Utah (University of Utah Residents) - Mixed germ cell tumor with seminomatous embryonal component
West Virginia (Greenbrier Valley Medical Center) - Seminoma, spermatocytic, metastatic
Australia (North Queensland Pathology Group) - Large B-cell lymphoma
Australia (Royal Prince Alfred Hospital) - Diffuse large cell malignant lymphoma
Canada (Foothills Medical Center) - Diffuse large cell lymphoma
Hong Kong (Hong Kong Baptist Hospital) - Diffuse large cell lymphoma
Jamaica (The University of the West Indies) - Diffuse large cell non-Hodgkin's lymphoma
Japan (Yamanashi Medical University) - Malignant lymphoma (3); Seminoma (1)
Qatar (Hamad Medical Corporation) - Disseminated malignant germ cell tumor (4); Seminoma (1)

Case 1 - Diagnosis:

Diffuse high grade large cell lymphoma, small bowel
T-64000, M-95903

Hematopathology consultation: Milton Drachenberg, M.D.: "Diffuse high grade large cell lymphoma."

Case 1 – References:

Al-Bahrani Zr, Al-Mondhiry H, Bakir F, Al-Saleem T. Clinical and Pathologic Subtypes of Primary intestinal Lymphoma. Experience with 132 Patients Over a 14-Year Period. *Cancer* 1983; 52(9):1666-1672.
Grody WW, Magidson JG, Weiss LM, et al. Gastrointestinal Lymphomas. Immunohistochemical Studies on the Cell of Origin. *Am J Surg Pathol* 1984; 9(5):328-337.

Case No. 2, Accession No. 29688 September 2003

Alameda (Alameda County Medical Center) - Insular carcinoma
Bakersfield - Hurthle cell carcinoma
Baldwin Park (Kaiser Permanente) - Poorly differentiated (insular) carcinoma (2); Carcinoid tumor (1)
Fontana (Kaiser Permanente) - Poorly differentiated carcinoma
Hayward/Fremont - Carcinoma with thymus-like elements (Castle tumor)
Laguna Beach (South Coast Medical Center) - Medullary carcinoma
Loma Linda (Loma Linda University Residents) - Neuroendocrine tumor, Calcitonin poor medullary carcinoma
Long Beach - Neuroendocrine carcinoma (8)
Mountain View (El Camino Pathology Group) - Medullary carcinoma
Orange (Orange County Pathology Medical Group) - Poorly differentiated (insular) carcinoma
Orange (UCI Medical Center Residents) - Poorly differentiated insular carcinoma
Sacramento (UC Davis Medical Center) - Insular carcinoma (poorly differentiated carcinoma)
San Diego (Naval Medical Center) - Insular carcinoma (13/19), 2nd choice, medullary thyroid carcinoma (6/19)
San Francisco (San Francisco General Hospital) - Follicular carcinoma
Santa Barbara (Cottage Hospital) - Medullary carcinoma consistent with small cell features
Santa Rosa (Santa Rosa Memorial Hospital) - Follicular carcinoma with oncocytic features (2); Poorly differentiated carcinoma with oncocytic features (1)
Ventura - Follicular carcinoma
Alaska (Alaska Native Medical Center) - Poorly differentiated (insular) carcinoma
Arizona (Maryvale Medical Center) - Insular carcinoma (poorly differentiated thyroid carcinoma)
Arizona (St. Josephs Hospital Residents) - Insular carcinoma of thyroid
Florida (Baptist Hospital) - Hurthle cell carcinoma (2)
Florida (Munroe Regional Medical Center) - Insular carcinoma

Florida (Pathology Associates) - Medullary carcinoma (do chromogranin), insular thyroid carcinoma
Florida (Winter Haven Hospital) - Carcinoid tumor
Illinois (Northwestern Memorial Hospital) - Poorly differentiated carcinoma, insular type (thyroid)
Louisiana (Louisiana State University Medical Center) - Poorly differentiated follicular carcinoma, thyroid
Maryland (National Naval Medical Center) - Insular/poorly differentiated carcinoma (11)
Massachusetts (Berkshire Medical Center) - Insular carcinoma (9)
Massachusetts (New England Medical Center Residents) - Poorly differentiated (insular) carcinoma of thyroid
Michigan (Oakwood Hospital) - Insular carcinoma
Michigan (St. Joseph Mercy Hospital) - High grade carcinoma, uncertain type
Minnesota (Fairview Southdale Hospital) - Insular carcinoma
Mississippi (University of Mississippi Medical Center) - Poorly differentiated carcinoma (insular carcinoma)
Nebraska (Creighton University School of Medicine Residents) - Follicular carcinoma, hurthle cell type
Nevada (Western Pathology Associates) - Insular carcinoma
New Jersey (Overlook Hospital) - Insular carcinoma
New York (Long Island Jewish Medical Center) - Insular carcinoma
New York (Nassau University Medical Center) - Undifferentiated carcinoma of thyroid
New York (New York Presbyterian Hospital Residents) - Insular carcinoma
New York (Stony Brook University Hospital Residents) - Insular carcinoma
North Carolina (Duke University Medical Center Residents) - Insular (poorly differentiated) carcinoma of the thyroid
Ohio (Medical College of Ohio Residents) - Poorly differentiated carcinoma with neuroendocrine features
Oklahoma (Tulsa) - Poorly differentiated carcinoma, insular type
Oklahoma (University of Oklahoma HSC Residents) - Medullary carcinoma, small cell variant
Pennsylvania (Allegheny General Hospital) - Medullary carcinoma
Pennsylvania (Centre Community Hospital) - Poorly differentiated carcinoma (insular carcinoma) of the thyroid gland
Pennsylvania (Conemaugh Memorial Medical Center) - Follicular carcinoma
Pennsylvania (Drexel University College of Medicine) - Insular carcinoma (poorly differentiated carcinoma of thyroid)
Pennsylvania (Lehigh Valley Hospital) - Medullary carcinoma
Pennsylvania (York Hospital) - Insular carcinoma (3); Poorly differentiated (insular) carcinoma (3); Thymoma (2)
Puerto Rico (University of Puerto Rico) - Insular carcinoma
Rhode Island (RI Hospital Residents) - Poorly differentiated thyroid carcinoma (insular carcinoma)
Texas (Lackland AFB) - Poorly differentiated (insular) carcinoma of the thyroid
Texas (Propath Associates) - Malignant carcinoid tumor (1); Malignant carcinoid tumor with dedifferential area
Texas (Scott & White Memorial Hospital) - Poorly differentiated carcinoma (favor neuroendocrine)
Utah (University of Utah Residents) - Insular carcinoma
West Virginia (Greenbrier Valley Medical Center) - Papillary carcinoma, follicular variant
Australia (North Queensland Pathology Group) - Insular carcinoma
Australia (Royal Prince Alfred Hospital) - Poorly differentiated carcinoma ?, medullary? insular
Canada (Foothills Medical Center) - Poorly differentiated (insular) thyroid carcinoma
Hong Kong (Hong Kong Baptist Hospital) - Insular carcinoma
Jamaica (The University of the West Indies) - Hyalinizing trabecular adenoma
Japan (Yamanashi Medical University) - Follicular carcinoma (insular carcinoma) (1); Medullary carcinoma (3)
Qatar (Hamad Medical Corporation) - Insular carcinoma of the thyroid

Case 2 - Diagnosis:

Poorly differentiated (insular) carcinoma, thyroid
T-96200, M-80103

Case 2 - References:

Papotti M, Volante M, Komminoth P, et al. Thyroid Carcinomas with Mixed Follicular and C-Cell Differentiation Patterns. *Semin Diagn Pathol* 2000; 17(2):109-119.
Decaussin M, Bernard MH, Adeleine P, et al. Thyroid Carcinomas with Distant Metastases. A Review of 111 Cases with Emphasis on the Prognostic Significance of an Insular Component. *Am J Surg Pathol* 2002; 26(8):1007-1015.
Nguyen GK and Akin MR. Cytopathology of Insular Carcinoma of the Thyroid. *Diagn Cytopathol* 2001; 25(5):325-330.

Rodriguez JM, Parrilla P, Moreno A, et al. Insular Carcinoma. An Infrequent Subtype of Thyroid Cancer. *J Am Coll Surg* 1998; 187(5):503-508.

Case No. 3, Accession No. 29358 **September 2003**

Alameda (Alameda County Medical Center) - Thymoma
Bakersfield - Thymoma
Baldwin Park (Kaiser Permanente) - Spindle cell thymoma (3)
Fontana (Kaiser Permanente) - Thymoma
Hayward/Fremont - Mixed cortical and medullary thymoma (type AB)
Laguna Beach (South Coast Medical Center) - Thymoma
Loma Linda (Loma Linda University Residents) - Type B, thymoma
Long Beach - Thymoma (8)
Mountain View (El Camino Pathology Group) - Thymoma
Orange (Orange County Pathology Medical Group) - Thymoma
Orange (UCI Medical Center Residents) - Thymoma
Sacramento (UC Davis Medical Center) - Thymoma, type B2
San Diego (Naval Medical Center) - Thymoma (13/19); Second choice, invasive thymoma (6/19)
San Francisco (San Francisco General Hospital) - Thymoma
Santa Barbara (Cottage Hospital) - Thymoma
Santa Rosa (Santa Rosa Memorial Hospital) - Thymoma (3)
Ventura - Thymoma
Alaska (Alaska Native Medical Center) - Thymic carcinoma (lymphoepithelioma-like)
Arizona (Maryvale Medical Center) - Thymoma, minimally invasive
Arizona (St. Josephs Hospital Residents) - Non-invasive thymoma
Florida (Baptist Hospital) - Spindle cell thymoma (1); Thymoma, spindle cell type (1)
Florida (Munroe Regional Medical Center) - Thymoma
Florida (Pathology Associates) - Thymoma
Florida (Winter Haven Hospital) - Thymoma
Illinois (Northwestern Memorial Hospital) - Thymoma, B-type (mixed)
Louisiana (Louisiana State University Medical Center) - Thymoma
Maryland (National Naval Medical Center) - Thymoma, minimally invasive (11)
Massachusetts (Berkshire Medical Center) - Thymoma (9)
Massachusetts (New England Medical Center Residents) - Mixed thymoma
Michigan (Oakwood Hospital) - Thymoma, WHO B2
Michigan (St. Joseph Mercy Hospital) - Thymoma
Minnesota (Fairview Southdale Hospital) - Thymoma
Mississippi (University of Mississippi Medical Center) - Thymoma
Nebraska (Creighton University School of Medicine Residents) - Thymoma
Nevada (Western Pathology Associates) - Thymoma
New Jersey (Overlook Hospital) - Thymoma
New York (Long Island Jewish Medical Center) - Spindle type/medullary thymoma
New York (Nassau University Medical Center) - Thymoma, medullary
New York (New York Presbyterian Hospital Residents) - Thymoma, predominantly mixed
New York (Stony Brook University Hospital Residents) - Thymoma
North Carolina (Duke University Medical Center Residents) - Thymoma
Ohio (Medical College of Ohio Residents) - Thymoma, mixed lymphocytic and epithelial type
Oklahoma (Tulsa) - Thymoma, type A, medullary
Oklahoma (University of Oklahoma HSC Residents) - Thymoma
Pennsylvania (Allegheny General Hospital) - Thymoma
Pennsylvania (Centre Community Hospital) - Thymic carcinoma
Pennsylvania (Conemaugh Memorial Medical Center) - Thymoma

Pennsylvania (Drexel University College of Medicine) - Invasive (malignant) thymoma
Pennsylvania (Lehigh Valley Hospital) - Thymoma
Pennsylvania (York Hospital) - Thymoma (8)
Puerto Rico (University of Puerto Rico) - Benign thymoma
Rhode Island (RI Hospital Residents) - Type A (medullary thymoma (WHO classification)
Texas (Lackland AFB) - Thymoma, encapsulated (type B1)
Texas (Propath Associates) - Thymoma, mixed type (2)
Texas (Scott & White Memorial Hospital) - Thymoma
Utah (University of Utah Residents) - Mixed pattern thymoma
West Virginia (Greenbrier Valley Medical Center) - Thymoma
Australia (North Queensland Pathology Group) - Lymphoepithelial thymoma
Australia (Royal Prince Alfred Hospital) - Thymoma (type AB)
Canada (Foothills Medical Center) - Type AB thymoma
Hong Kong (Hong Kong Baptist Hospital) - Malignant thymoma
Jamaica (The University of the West Indies) - Thymoma, mixed type
Japan (Yamanashi Medical University) - Thymoma (4)
Qatar (Hamad Medical Corporation) - Thymoma

Case 3 - Diagnosis:

Thymoma

T-Y2300, M-85800

Case 3 - References:

Tomiyama N, Johkoh T, Mihara N, et al. Using the World Health Organization Classification of Thymic Epithelial Neoplasms to Describe CT Findings. *AJR Am Roentgenol* 2002; 179(4):881-886.

Okumura M, Ohta M, Tateyama H, et al. The World Heath Organization Histologic Classification System Reflects the Oncologic Behavior of Thymoma. A Clinical Study of 273 Patients. *Cancer* 2002; 94(3):624-632.

Kuo TT. Classification of Thymic Epithelial Neoplasms. A Controversial Issue Coming to an End? *J Cell Mol Med* 2001; 5(4):442-448.

Mehran R, Ghosh R, Maziak D, et al. Surgical Treatment of Thymoma. *Can J Surg* 2002; 45(1):25-30.

Chen G, Marx A, Wen-Hu C, et al. New WHO Histologic Classification Predicts Prognosis of Thymic Epithelial Tumors. A Clinicopathologic Study of 200 Thymoma Cases from China. *Cancer* 2002; 95(2):420-429.

Case No. 4, Accession No. 29392 September 2003

Alameda (Alameda County Medical Center) - Squamous cell carcinoma
Bakersfield - Poorly differentiated squamous cell carcinoma
Baldwin Park (Kaiser Permanente) - Poorly differentiated squamous cell carcinoma (1); Squamous carcinoma (2)
Fontana (Kaiser Permanente) - Squamous cell carcinoma
Hayward/Fremont - Squamous carcinoma, lung
Laguna Beach (South Coast Medical Center) - Squamous cell carcinoma (basaloid)
Loma Linda (Loma Linda University Residents) - Poorly differentiated bronchogenic carcinoma, large non-keratinizing squamous cell carcinoma
Long Beach - Squamous cell carcinoma (8)
Mountain View (El Camino Pathology Group) - Squamous cell carcinoma
Orange (Orange County Pathology Medical Group) - Squamous cell carcinoma
Orange (UCI Medical Center Residents) - Poorly differentiated squamous cell carcinoma, non-keratinizing
Sacramento (UC Davis Medical Center) - Squamous cell carcinoma (basaloid type)
San Diego (Naval Medical Center) - Large cell carcinoma with neuroendocrine morphology
San Francisco (San Francisco General Hospital) - Squamous cell carcinoma with metaplastic cartilage
Santa Barbara (Cottage Hospital) - Pleomorphic squamous cell carcinoma
Santa Rosa (Santa Rosa Memorial Hospital) - Squamous cell carcinoma (2); Poorly differentiated squamous cell carcinoma (1)
Ventura - Squamous cell carcinoma

Alaska (Alaska Native Medical Center) - Poorly differentiated large cell carcinoma (2); Large cell neuroendocrine carcinoma (1)
Arizona (Maryvale Medical Center) - Large cell carcinoma
Arizona (St. Josephs Hospital Residents) - Basaloid carcinoma of lung
Florida (Baptist Hospital) - Squamous carcinoma with some glandular differentiation (1); Adenosquamous carcinoma (1)
Florida (Munroe Regional Medical Center) - Poorly differentiated adenocarcinoma
Florida (Pathology Associates) - Squamous carcinoma
Florida (Winter Haven Hospital) - Bronchioalveolar adenocarcinoma
Illinois (Northwestern Memorial Hospital) - Squamous cell carcinoma
Louisiana (Louisiana State University Medical Center) - Poorly differentiated squamous cell carcinoma
Maryland (National Naval Medical Center) - Basaloid squamous cell carcinoma (6); Poorly differentiated carcinoma (5)
Massachusetts (Berkshire Medical Center) - Squamous cell carcinoma (9)
Massachusetts (New England Medical Center Residents) - High grade squamous cell carcinoma of the lung (squamous cell carcinoma)
Michigan (Oakwood Hospital) - Large cell carcinoma, possibly neuroendocrine
Michigan (St. Joseph Mercy Hospital) - Squamous cell carcinoma
Minnesota (Fairview Southdale Hospital) - Poorly differentiated non-small cell carcinoma (basosquamous/basaloid squamous)
Mississippi (University of Mississippi Medical Center) - Squamous cell carcinoma
Nebraska (Creighton University School of Medicine Residents) - Squamous cell carcinoma
Nevada (Western Pathology Associates) - Poorly differentiated squamous cell carcinoma
New Jersey (Overlook Hospital) - Poorly differentiated squamous cell carcinoma
New York (Long Island Jewish Medical Center) - Basaloid squamous cell carcinoma
New York (Nassau University Medical Center) - Squamous cell carcinoma
New York (New York Presbyterian Hospital Residents) - Non-small cell carcinoma, favor squamous cell carcinoma
New York (Stony Brook University Hospital Residents) - Salivary duct carcinoma
North Carolina (Duke University Medical Center Residents) - Squamous cell carcinoma
Ohio (Medical College of Ohio Residents) - Poorly differentiated non-small cell carcinoma with transitional cell features
Oklahoma (Tulsa) - Poorly differentiated squamous carcinoma
Oklahoma (University of Oklahoma HSC Residents) - Poorly differentiated squamous cell carcinoma
Pennsylvania (Allegheny General Hospital) - Poorly differentiated squamous cell carcinoma
Pennsylvania (Centre Community Hospital) - Large cell carcinoma of the lung
Pennsylvania (Conemaugh Memorial Medical Center) - Squamous cell carcinoma
Pennsylvania (Drexel University College of Medicine) - Squamous cell carcinoma
Pennsylvania (Lehigh Valley Hospital) - Squamous cell carcinoma
Pennsylvania (York Hospital) - Basaloid squamous cell carcinoma (8)
Puerto Rico (University of Puerto Rico) - Large cell carcinoma/non-keratinizing squamous cell carcinoma, moderately differentiated
Rhode Island (RI Hospital Residents) - Basaloid carcinoma
Texas (Lackland AFB) - Poorly differentiated carcinoma (large cell neuroendocrine carcinoma vs. non-keratinizing squamous cell carcinoma)
Texas (Propath Associates) - Epidermoid carcinoma (1); Poorly differentiated epidermoid type carcinoma (1)
Texas (Scott & White Memorial Hospital) - Squamous cell carcinoma
Utah (University of Utah Residents) - Squamous cell carcinoma
West Virginia (Greenbrier Valley Medical Center) - Large cell neuroendocrine carcinoma
Australia (North Queensland Pathology Group) - Atypical carcinoid
Australia (Royal Prince Alfred Hospital) - Squamous cell carcinoma
Canada (Foothills Medical Center) - Poorly differentiated squamous carcinoma of lung
Hong Kong (Hong Kong Baptist Hospital) - Moderately differentiated non-keratinizing squamous cell carcinoma
Jamaica (The University of the West Indies) - Squamous cell carcinoma, moderately differentiated
Japan (Yamanashi Medical University) - Squamous cell carcinoma (4)
Qatar (Hamad Medical Corporation) - Moderately differentiated squamous carcinoma

Case 4 - Diagnosis:

Squamous cell carcinoma, lung
T-28000, M-80703

Case 4 - References:

Kreuzer M, Heinrich J, Kreienbrock L, et al. Risk Factors for Lung Cancer Among Nonsmoking Women. *Int J Cancer* 2002; 100(6):706-713.

Mountain CF, Lukeman JM, Hammer SP, et al. Lung Cancer Classification. The Relationship of Disease Extent and Cell Type to Survival in a Clinical Trials Population. *J Surg Oncol* 1987; 35(3):147-156.

Devesa SS, Shaw GL, Blot WJ. Changing Patterns of Lung Cancer Incidence by Histologic Type. *Cancer Epidermiol Biomarkers Prev* 1991; 1(1):29-34.

Ogino S, Franks TJ, Yong M, et al. Extensive Squamous Metaplasia with Cytologic Atypia in Diffuse Alveolar Damage Mimicking Squamous Cell Carcinoma. A Report of 2 Cases. *Hum Pathol* 2002; 33(10):1052-1054.

Wang BY, Gil J, Kaufman D, et al. P63 in Pulmonary Epithelium, Pulmonary Squamous Neoplasms, and Other Pulmonary Tumors. *Hum Pathol* 2002; 33(9):921-926.

Case No. 5, Accession No. 29053 September 2003

Alameda (Alameda County Medical Center) - Mucinous bronchioloalveolar carcinoma
Bakersfield - Bronchioloalveolar carcinoma, mucinous type
Baldwin Park (Kaiser Permenente) - Mucinous type bronchioloalveolar carcinoma (3)
Fontana (Kaiser Permanente) - Bronchoalveolar carcinoma
Hayward/Fremont - Mucinous adenocarcinoma with bronchoalveolar growth pattern
Laguna Beach (South Coast Medical Center) - Bronchioloalveolar carcinoma
Loma Linda (Loma Linda University Residents) - Mucinous (colloid) carcinoma with bronchoalveolar features
Long Beach - Bronchioloalveolar cell carcinoma (8)
Mountain View (El Camino Pathology Group) - Bronchoalveolar carcinoma, mucinous type
Orange (Orange County Pathology Medical Group) - Adenocarcinoma, bronchoalveolar
Orange (UCI Medical Center Residents) - Bronchioloalveolar carcinoma
Sacramento (UC Davis Medical Center) - Bronchioloalveolar carcinoma, mucinous type
San Diego (Naval Medical Center) - Mucin producing adenocarcinoma
San Francisco (San Francisco General Hospital) - Mucinous bronchoalveolar adenocarcinoma
Santa Barbara (Cottage Hospital) - Bronchioloalveolar carcinoma, mucinous type
Santa Rosa (Santa Rosa Memorial Hospital) - Bronchoalveolar carcinoma (2); Adenocarcinoma, mucin producing
Ventura - Mucinous bronchioloalveolar carcinoma
Alaska (Alaska Native Medical Center) - Well-differentiated invasive adenocarcinoma (papillary with goblet cells and abundant mucin) bronchioalveolar features?
Arizona (Maryvale Medical Center) - Bronchioloalveolar carcinoma, mucinous type
Arizona (St. Josephs Hospital Residents) - Mucinous/colloid carcinoma of lung
Florida (Baptist Hospital) - Mucinous bronchoalveolar carcinoma (2)
Florida (Munroe Regional Medical Center) - Well-differentiated adenocarcinoma
Florida (Pathology Associates) - Mucinous bronchoalveolar tumor, mucinous carcinoma
Florida (Winter Haven Hospital) - Bronchoalveolar adenocarcinoma
Illinois (Northwestern Memorial Hospital) - Bronchoalveolar carcinoma, secondary-type
Louisiana (Louisiana State University Medical Center) - Adenocarcinoma with bronchoalveolar features
Maryland (National Naval Medical Center) - Bronchioloalveolar carcinoma, mucinous (6); Mucinous cystadenocarcinoma (5)
Massachusetts (Berkshire Medical Center) - Bronchioloalveolar carcinoma, mucinous type (9)
Massachusetts (New England Medical Center Residents) - Bronchoalveolar carcinoma, mucinous type
Michigan (Oakwood Hospital) - Adenocarcinoma, bronchioloalveolar, mucinous type
Michigan (St. Joseph Mercy Hospital) - Mucinous bronchioloalveolar carcinoma
Minnesota (Fairview Southdale Hospital) - Bronchoalveolar carcinoma, mucinous type
Mississippi (University of Mississippi Medical Center) - Bronchoalveolar carcinoma, mucinous type
Nebraska (Creighton University School of Medicine Residents) - Bronchoalveolar carcinoma, mucinous type
Nevada (Western Pathology Associates) - Mucinous bronchioloalveolar carcinoma

New Jersey (Overlook Hospital) - Alveolar bronchiolar cell carcinoma, mucinous type
New York (Long Island Jewish Medical Center) - Bronchioloalveolar carcinoma
New York (Nassau University Medical Center) - Bronchoalveolar carcinoma, mucinous type
New York (New York Presbyterian Hospital Residents) - Mucinous adenocarcinoma
New York (Stony Brook University Hospital Residents) - Bronchioloalveolar carcinoma
North Carolina (Duke University Medical Center Residents) - Bronchioloalveolar carcinoma, mucinous type
Ohio (Medical College of Ohio Residents) - Bronchioloalveolar carcinoma, mucinous type
Oklahoma (Tulsa) - Bronchioloalveolar carcinoma, mucinous type
Oklahoma (University of Oklahoma HSC Residents) - Mucinous carcinoma (so-called colloid carcinoma)
Pennsylvania (Allegheny General Hospital) - Bronchoalveolar carcinoma, mucinous type
Pennsylvania (Centre Community Hospital) - Mucinous adenocarcinoma (related to bronchioloalveolar carcinoma, of the lung)
Pennsylvania (Conemaugh Memorial Medical Center) - Papillary carcinoma/bronchioloalveolar carcinoma
Pennsylvania (Drexel University College of Medicine) - Papillary adenocarcinoma
Pennsylvania (Lehigh Valley Hospital) - Bronchoalveolar carcinoma
Pennsylvania (York Hospital) - Bronchioloalveolar carcinoma vs. metastatic adenocarcinoma
Puerto Rico (University of Puerto Rico) - Adenocarcinoma,-bronchioloalveolar type
Rhode Island (RI Hospital Residents) - Mucinous bronchioloalveolar carcinoma
Texas (Lackland AFB) - Bronchioloalveolar carcinoma
Texas (Propath Associates) - Bronchoalveolar carcinoma, mucoid type (2)
Texas (Scott & White Memorial Hospital) - Mucinous bronchioloalveolar carcinoma
Utah (University of Utah Residents) - Mucinous papillary adenocarcinoma
West Virginia (Greenbrier Valley Medical Center) - Papillary adenocarcinoma
Australia (North Queensland Pathology Group) - Mucin producing bronchoalveolar carcinoma
Australia (Royal Prince Alfred Hospital) - Mucinous adenocarcinoma (bronchoalveolar pattern)
Canada (Foothills Medical Center) - Adenocarcinoma, mixed type, with predominant bronchioloalveolar pattern (mucinous type)
Hong Kong (Hong Kong Baptist Hospital) - Bronchioloalveolar carcinoma, goblet cell type
Jamaica (The University of the West Indies) - Bronchoalveolar carcinoma, mucin producing type
Japan (Yamanashi Medical University) - Adenocarcinoma papillary (1); Bronchoalveolar (2); Muco-nodular (1)
Qatar (Hamad Medical Corporation) - Bronchioloalveolar carcinoma

Case 5 - Diagnosis:

Mucinous bronchioloalveolar carcinoma, lung
T-28000, M-82503

Case 5 - References:

Clayton F. Broncoalveolar Carcinomas. Cell Types, Patterns of Growth and Prognostic Correlates. *Cancer* 1986; 57(8):1555-1560.

Dumont P, Gasser B, Rouge C, et al. Bronchoalveolar Carcinoma. Histopathologic Study of Evolution in a Series of 105 Surgically Treated Patients. *Chest* 1998; 113(2):391-395.

Lau SK, Desrochers MJ, Luthringer DJ. Expression of Thyroid Transcription Factor-1, Cytokeratin 7 and Cytokeratin 20 in Bronchioloalveolar Carcinomas. An Immunohistochemical Evaluation of 67 Cases. *Mod Pathol* 2002; 15(5):538-542.

Clayton F. The Spectrum and Significance of Bronchioloalveolar Carcinomas. *Pathol Annu* 1988; 23 Pt 2:361-394.

Goldstein NS, Thomas M. Mucinous and Nonmucinous Bronchioloalveolar Adenocarcinomas Have Distinct Staining Patterns with Thyroid Transcription Factor and Cytokeratin 20 Antibodies. *Am J Clin Pathol* 2001; 116(3):319-325.

Case No. 6, Accession No. 29448 September 2003

Alameda (Alameda County Medical Center) - Myxoid chondrosarcoma
Baldwin Park (Kaiser Permanente) - Cannot interpret (2); Chondrosarcoma (1)
Fontana (Kaiser Permanente) - Chondrosarcoma
Hayward/Fremont - Chondrosarcoma arising in proliferative synovitis
Laguna Beach (South Coast Medical Center) - Extraskeletal chondrosarcoma
Loma Linda (Loma Linda University Residents) - Myxoid chondrosarcoma, grade II

Long Beach - Extraskeletal myxoid chondrosarcoma (8)
Mountain View (El Camino Pathology Group) - Extraskeletal myxoid chondrosarcoma
Orange (UCI Medical Center Residents) - Extraskeletal myxoid chondrosarcoma
Sacramento (UC Davis Medical Center) - Hemangioendothelioma vs. pigmented villonodular synovitis
San Diego (Naval Medical Center) - High grade chondrosarcoma
San Francisco (San Francisco General Hospital) - Myxoid chondrosarcoma
Santa Barbara (Cottage Hospital) - Myxofibrosarcoma
Santa Rosa (Santa Rosa Memorial Hospital) - Chondrosarcoma (2); Myxoid chondrosarcoma (1)
Ventura - Chondrosarcoma
Alaska (Alaska Native Medical Center) - Myxoid chondrosarcoma (2); Chondrosarcoma , high grade, conventional (1)
Arizona (Maryvale Medical Center) - Extraskeletal chondrosarcoma
Arizona (St. Josephs Hospital Residents) - Extraskeletal myxoid chondrosarcoma
Florida (Baptist Hospital) - Chondrosarcoma, extraskeletal type (1); Extraskeletal myxoid chondrosarcoma (1)
Florida (Munroe Regional Medical Center) - Extraskeletal myxoid chondrosarcoma
Florida (Pathology Associates) - Myxoid chondrosarcoma
Florida (Winter Haven Hospital) - Extraskeletal myxoid chondrosarcoma
Illinois (Northwestern Memorial Hospital) - Myxoid chondrosarcoma
Louisiana (Louisiana State University Medical Center) - Pigmented villonodular synovitis
Maryland (National Naval Medical Center) - Chondrosarcoma (11)
Massachusetts (Berkshire Medical Center) - Chondrosarcoma, Grade II (9)
Massachusetts (New England Medical Center Residents) - Extraskeletal myxoid chondrosarcoma
Michigan (Oakwood Hospital) - Myxoid chondrosarcoma
Michigan (St. Joseph Mercy Hospital) - Pigmented villonodular tenosynovitis
Minnesota (Fairview Southdale Hospital) - Synovial chondromatosis
Mississippi (University of Mississippi Medical Center) - Myxoid chondrosarcoma
Nebraska (Creighton University School of Medicine Residents) - Myxofibrosarcoma vs. myxoid epithelial hemangioepithelioma
Nevada (Western Pathology Associates) - Extraskeletal chondrosarcoma
New Jersey (Overlook Hospital) - Extraskeletal myxoid chondrosarcoma
New York (Long Island Jewish Medical Center) - Extraskeletal myxoid chondrosarcoma
New York (Nassau University Medical Center) - Myxoid mesenchymal chondrosarcoma
New York (New York Presbyterian Hospital Residents) - Extraskeletal myxochondrosarcoma
New York (Stony Brook University Hospital Residents) - Synovial chondromatosis
North Carolina (Duke University Medical Center Residents) - Epithelioid hemangioendothelioma vs. myxoid chondrosarcoma
Ohio (Medical College of Ohio Residents) - Extraskeletal myxoid chondrosarcoma
Oklahoma (Tulsa) - Pigmented villonodular synovitis
Oklahoma (University of Oklahoma HSC Residents) - Pigmented villonodular synovitis
Pennsylvania (Allegheny General Hospital) - Extraskeletal myxoid chondrosarcoma
Pennsylvania (Centre Community Hospital) - Epithelioid hemangioendothelioma
Pennsylvania (Conemaugh Memorial Medical Center) - Dedifferentiated liposarcoma
Pennsylvania (Drexel University College of Medicine) - Hemosiderotic synovitis
Pennsylvania (Lehigh Valley Hospital) - Chondrosarcoma
Pennsylvania (York Hospital) - Myxoid chondrosarcoma (8)
Puerto Rico (University of Puerto Rico) - Pigmented villonodular tenosynovitis
Rhode Island (RI Hospital Residents) - Myxoid chondrosarcoma
Texas (Lackland AFB) - Extraskeletal myxoid chondrosarcoma
Texas (Propath Associates) - Epithelioid angiosarcoma (2)
Texas (Scott & White Memorial Hospital) - Extraskeletal myxoid chondrosarcoma
Utah (University of Utah Residents) - PVNS/localized hemosiderotic tenosynovitis
West Virginia (Greenbrier Valley Medical Center) - Chondroma, extra osseous
Australia (North Queensland Pathology Group) - Myxoid chondrosarcoma
Australia (Royal Prince Alfred Hospital) - Extraskeletal myxoid chondrosarcoma with hemorrhage
Canada (Foothills Medical Center) - Giant cell tumor of tendon sheath
Hong Kong (Hong Kong Baptist Hospital) - Angiomatoid malignant fibrous histiocytoma

Japan (Yamanashi Medical University) - Extraskeletal myxoid chondrosarcoma (2); Synovial sarcoma (1); Pigmented villonodular synovitis (1)

Qatar (Hamad Medical Corporation) - Chondrosarcoma, moderately differentiated, grade II

Case 6 - Diagnosis:

Extraskeletal myxoid chondrosarcoma, knee
T-Y9200, M-92203

Case 6 - References:

Gephardt MC, Parekh SG, Rosenberg AE, et al. Extraskeletal Myxoid Chondrosarcoma of the Knee. *Skeletal Radiol* 1999; 28(6):354-358.

Takeda A, Tsuchiya H, Mori Y, et al. Extraskeletal Myxoid Chondrosarcoma with Multiple Skeletal Metastases. *J Orthop Sci* 2000; 5(2):171-174.

Rubin BP, Fletcher JA. Skeletal and Extraskeletal Myxoid Chondrosarcoma. Related or Distinct Tumors? *Adv Anat Pathol* 1999; 6(4):204-212.

Oliveira AM, Nascimento AG. Phenotypic Plasticity and Prognostic Factors in Extraskeletal Myxoid Chondrosarcoma. *Adv Anat Pathol* 2000; 7(2):73-78.

Whitten CG, el-Khoury GY, Benda JA, et al. Case Report 829. Intramuscular Myxoid Chondrosarcoma. *Skeletal Radiol* 1994; 23(2):153-156.

Case No. 7, Accession No. 29469 September 2003

Alameda (Alameda County Medical Center) - Chondroma, atypical

Bakersfield - Enchondroma

Baldwin Park (Kaiser Permanente) - Enchondroma (1); Chondroma (1); Chondroma/enchondroma (1)

Fontana (Kaiser Permanente) - Chondroma

Hayward/Fremont - Chondroma

Laguna Beach (South Coast Medical Center) - Chondroma

Loma Linda (Loma Linda University Residents) - Low grade chondrosarcoma, chondroid chondroma vs. low grade chondrosarcoma

Long Beach - Chondroma (8)

Mountain View (El Camino Pathology Group) - Chondroma

Orange (Orange County Pathology Medical Group) - Chondroma

Orange (UCI Medical Center Residents) - Chondroma

Sacramento (UC Davis Medical Center) - Chondroma

San Diego (Naval Medical Center) - Chondroma

San Francisco (San Francisco General Hospital) - Chondrosarcoma

Santa Barbara (Cottage Hospital) - Chondroma of falx

Santa Rosa (Santa Rosa Memorial Hospital) - Chondroma (3)

Ventura - Chondroma

Alaska (Alaska Native Medical Center) - Chondrosarcoma, intracranial, low grade (2); Chondroma (1)

Arizona (Maryvale Medical Center) - Chondroma, dural

Arizona (St. Josephs Hospital Residents) - Well-differentiated chondrosarcoma

Florida (Baptist Hospital) - Chordoma (2)

Florida (Munroe Regional Medical Center) - Chondrosarcoma

Florida (Pathology Associates) - Chondroma

Florida (Winter Haven Hospital) - Chondroma

Illinois (Northwestern Memorial Hospital) - Chondrosarcoma, low grade

Louisiana (Louisiana State University Medical Center) - Chondroma

Maryland (National Naval Medical Center) - Chondroma (11)

Massachusetts (Berkshire Medical Center) - Chondrosarcoma, low grade (9)

Massachusetts (New England Medical Center Residents) - Low grade chondrosarcoma

Michigan (Oakwood Hospital) - Chondrosarcoma, low grade

Michigan (St. Joseph Mercy Hospital) - Grade I, chondrosarcoma

Minnesota (Fairview Southdale Hospital) - Low grade chondrosarcoma
Mississippi (University of Mississippi Medical Center) - Dural chondroma
Nebraska (Creighton University School of Medicine Residents) - Choroloma
Nevada (Western Pathology Associates) - Chondroma
New Jersey (Overlook Hospital) - Chondroma
New York (Long Island Jewish Medical Center) - Chondroma
New York (Nassau University Medical Center) - Chondrosarcoma, well-differentiated
New York (New York Presbyterian Hospital Residents) - Soft tissue chondroma
New York (Stony Brook University Hospital Residents) - Chondroma
North Carolina (Duke University Medical Center Residents) - Dural chondroma
Ohio (Medical College of Ohio Residents) - Meningeal chondroma
Oklahoma (Tulsa) - Chondroma
Oklahoma (University of Oklahoma HSC Residents) - Extraskeletal chondroma
Pennsylvania (Allegheny General Hospital) - Low grade chondrosarcoma
Pennsylvania (Centre Community Hospital) - Chondrosarcoma
Pennsylvania (Conemaugh Memorial Medical Center) - Chondrosarcoma
Pennsylvania (Drexel University College of Medicine) - Meningeal well-differentiated chondrosarcoma
Pennsylvania (Lehigh Valley Hospital) - Chondroma
Pennsylvania (York Hospital) - Low grade chondrosarcoma (8)
Puerto Rico (University of Puerto Rico) - Chondroma
Rhode Island (RI Hospital Residents) - Chondroma
Texas (Lackland AFB) - Chondrosarcoma (doubt chondroma or meningioma with marked chondroid differentiation)
Texas (Propath Associates) - Chondroid chordoma (2)
Texas (Scott & White Memorial Hospital) - Chondroma
Utah (University of Utah Residents) - Chondrosarcoma, low grade
West Virginia (Greenbrier Valley Medical Center) - Chondroma
Australia (North Queensland Pathology Group) - Chondroma
Australia (Royal Prince Alfred Hospital) - Low grade cartilage tumor probably chondromà
Canada (Foothills Medical Center) - Chondrosarcoma
Hong Kong (Hong Kong Baptist Hospital) - Low grade chondrosarcoma, DDx: Chondroid chordoma
Jamaica (The University of the West Indies) - Chondrosarcoma
Japan (Yamanashi Medical University) - Chondrosarcoma (3); Chondroma (1)
Qatar (Hamad Medical Corporation) - Chondroid chordoma

Case 7 - Diagnosis:

Chondroma, falx cerebri
T-X1140, M-92200

Case 7 - References:

Ozgen T, Pamar MN, Akalan N, et al. Intracranial Solitary Chondroma. Case Report. *J Neurosurg* 1984; 61(2):399-401.
Fenyes G, Slowik F and Deak G. On a Surgically Removed Intracranial Chondroma. *Zentralbl Neurochir* 1965; 26(1):22-28. (German)
Lin WC, Lirng JF, Ho DM, et al. A Rare Giant Intracranial Osteochondroma. *Zhonghua Yi Xue Za Zhi* 2002; 65(5):235-238.
Ishibashi H, Matsuno H, Nagata S, et al. Posterior Fossa Chondroma Arising from the Tentorium. A Case Report. *Surg Neurol* 1999; 52(6):604-606.

Case No. 8, Accession No. 29451 September 2003

Alameda (Alameda County Medical Center) - Seminoma
Bakersfield - Seminoma
Baldwin Park (Kaiser Permanente) - Seminoma (3)
Fontana (Kaiser Permanente) - Seminoma
Hayward/Fremont - Seminoma

Laguna Beach (South Coast Medical Center) - Classic seminoma
Loma Linda (Loma Linda University Residents) - Seminoma
Long Beach - Seminoma (8)
Mountain View (El Camino Pathology Group) - Seminoma
Orange (Orange County Pathology Medical Group) - Seminoma, classic
Orange (UCI Medical Center Residents) - Seminoma
Sacramento (UC Davis Medical Center) - Spermatocytic seminoma
San Diego (Naval Medical Center) - Seminoma
San Francisco (San Francisco General Hospital) - Seminoma
Santa Barbara (Cottage Hospital) - Seminoma
Santa Rosa (Santa Rosa Memorial Hospital) - Seminoma (3)
Ventura - Seminoma
Alaska (Alaska Native Medical Center) - Seminoma (anaplastic) (2); Spermatocytic seminoma (anaplastic) (1)
Arizona (Maryvale Medical Center) - Seminoma, testicle
Arizona (St. Josephs Hospital Residents) - Seminoma
Florida (Baptist Hospital) - Seminoma (2)
Florida (Munroe Regional Medical Center) - Seminoma
Florida (Pathology Associates) - Seminoma
Florida (Winter Haven Hospital) - Seminoma
Illinois (Northwestern Memorial Hospital) - Seminoma
Louisiana (Louisiana State University Medical Center) - Seminoma
Maryland (National Naval Medical Center) - Seminoma, classic (11)
Massachusetts (Berkshire Medical Center) - Seminoma (9)
Massachusetts (New England Medical Center Residents) - Seminoma, classic
Michigan (Oakwood Hospital) - Seminoma
Michigan (St. Joseph Mercy Hospital) - Seminoma, classic type
Minnesota (Fairview Southdale Hospital) - Seminoma
Mississippi (University of Mississippi Medical Center) - Seminoma, typical
Nebraska (Creighton University School of Medicine Residents) - Seminoma
Nevada (Western Pathology Associates) - Classical seminoma
New Jersey (Overlook Hospital) - Seminoma
New York (Long Island Jewish Medical Center) - Seminoma, classical type
New York (Nassau University Medical Center) - Classical seminoma
New York (New York Presbyterian Hospital Residents) - Seminoma
New York (Stony Brook University Hospital Residents) - Seminoma
North Carolina (Duke University Medical Center Residents) - Seminoma
Ohio (Medical College of Ohio Residents) - Seminoma, classic type
Oklahoma (Tulsa) - Seminoma
Oklahoma (University of Oklahoma HSC Residents) - Anaplastic seminoma
Pennsylvania (Allegheny General Hospital) - Seminoma
Pennsylvania (Centre Community Hospital) - Spermatocytic seminoma
Pennsylvania (Conemaugh Memorial Medical Center) - Classic seminoma
Pennsylvania (Drexel University College of Medicine) - Seminoma
Pennsylvania (Lehigh Valley Hospital) - Classic seminoma
Pennsylvania (York Hospital) - Seminoma (8)
Puerto Rico (University of Puerto Rico) - Classic seminoma
Rhode Island (RI Hospital Residents) - Seminoma
Texas (Lackland AFB) - Seminoma
Texas (Propath Associates) - Seminoma (2)
Texas (Scott & White Memorial Hospital) - Seminoma
Utah (University of Utah Residents) - Seminoma
West Virginia (Greenbrier Valley Medical Center) - Seminoma
Australia (North Queensland Pathology Group) - Classical seminoma

Australia (Royal Prince Alfred Hospital) - Granulomatous seminoma
Canada (Foothills Medical Center) - Seminoma
Hong Kong (Hong Kong Baptist Hospital) - Seminoma
Jamaica (The University of the West Indies) - Seminoma
Japan (Yamanashi Medical University) - Seminoma (3); Spermatocytic seminoma (1)
Qatar (Hamad Medical Corporation) - Seminoma

Case 8 - Diagnosis:

Seminoma, testis
T-78000, M-90613

Case 8 – References:

Zablow A, Erba P and Sanfilippo LJ. Early Stage Pure Seminoma Testis. *N J Med* 1989; 86(10):800-803.
Suzuki K, Orikasa S, Hoshi S, Yoshibawa K, et al. Surveillance Study for Clinical Stage I Testicular Seminomas and Nonseminomatous Germ Cell Tumors. *Int J Urol* 1998; 5(6):568-574.
Narayana AS, Loening S, Weimar G, et al. Serum Markers in Testicular Tumors. *J Urol* 1979; 121(1):51-53.
Lightner DJ and Lange PH. Testicular Tumors. *Immunol Ser* 1990; 53:397-401.
Shahidi M, Norman AR, Dearnaley DP, et al. Late Recurrence in 1263 Men with Testicular Germ Cell Tumors. Multivariate Analysis of Risk Factors and Implications for Management. *Cancer* 2002; 95(3):520-530.

Case No. 9, Accession No. 29160 September 2003

Alameda (Alameda County Medical Center) - Inflammatory myofibroblastic tumor
Bakersfield - Leiomyosarcoma
Baldwin Park (Kaiser Permanente) - Leiomyosarcoma (3)
Fontana (Kaiser Permanente) - Sarcoma, probably leiomyosarcoma
Hayward/Fremont - Spindle cell tumor, metaplastic carcinoma vs. myofibroblastoma (need CD34)
Laguna Beach (South Coast Medical Center) - Myofibroblastoma
Loma Linda (Loma Linda University Residents) - Myofibroblastoma
Long Beach - Leiomyosarcoma (8)
Mountain View (El Camino Pathology Group) - Spindle cell carcinoma
Orange (Orange County Pathology Medical Group) - Nodular fasciitis
Orange (UCI Medical Center Residents) - Malignant Phyllodes tumor, high grade
Sacramento (UC Davis Medical Center) - Inflammatory myofibroblastic tumor
San Diego (Naval Medical Center) - Inflammatory myofibroblastic tumor (12/19); Sarcoma, NOS (7/19)
San Francisco (San Francisco General Hospital) - Leiomyosarcoma
Santa Barbara (Cottage Hospital) - Sarcoma (leiomyosarcoma)
Santa Rosa (Santa Rosa Memorial Hospital) - Leiomyosarcoma (3)
Ventura - Leiomyosarcoma
Alaska (Alaska Native Medical Center) - Malignant myoepithelioma/myoepithelial carcinoma, spindle cell type (2); Spindle cell sarcoma (1)
Arizona (Maryvale Medical Center) - Leiomyosarcoma
Arizona (St. Josephs Hospital Residents) - Inflammatory pseudotumor
Florida (Baptist Hospital) - Epithelioid leiomyosarcoma (1); Spindle cell sarcoma, favor leiomyosarcoma (1)
Florida (Munroe Regional Medical Center) - Leiomyosarcoma
Florida (Pathology Associates) - Metaplastic carcinoma
Florida (Winter Haven Hospital) - Leiomyosarcoma
Illinois (Northwestern Memorial Hospital) - Malignant Phyllodes tumor of breast
Louisiana (Louisiana State University Medical Center) - Metaplastic breast carcinoma
Maryland (National Naval Medical Center) - Leiomyosarcoma (11)
Massachusetts (Berkshire Medical Center) - Myofibroblastoma (2); Fibromatosis (7)
Massachusetts (New England Medical Center Residents) - Leiomyosarcoma
Michigan (Oakwood Hospital) - Metaplastic carcinoma

Michigan (St. Joseph Mercy Hospital) - Leiomyosarcoma
Minnesota (Fairview Southdale Hospital) - Leiomyosarcoma
Mississippi (University of Mississippi Medical Center) - Myoepithelioma vs. leiomyosarcoma
Nebraska (Creighton University School of Medicine Residents) - Malignant sarcoma
Nevada (Western Pathology Associates) - Nodular fasciitis
New Jersey (Overlook Hospital) - Soft tissue osteogenic sarcoma
New York (Long Island Jewish Medical Center) - Pseudotumor/nodular fasciitis
New York (Nassau University Medical Center) - Phyllodes sarcoma, high grade
New York (New York Presbyterian Hospital Residents) - Myofibroblastic sarcoma
New York (Stony Brook University Hospital Residents) - Leiomyosarcoma
North Carolina (Duke University Medical Center Residents) - Nodular fasciitis vs. sarcoma
Ohio (Medical College of Ohio Residents) - Inflammatory myofibroblastic tumor
Oklahoma (Tulsa) - Leiomyosarcoma
Oklahoma (University of Oklahoma HSC Residents) - Spindle cell carcinoma
Pennsylvania (Allegheny General Hospital) - Leiomyosarcoma
Pennsylvania (Centre Community Hospital) - Malignant myoepithelioma
Pennsylvania (Conemaugh Memorial Medical Center) - Leiomyosarcoma
Pennsylvania (Drexel University College of Medicine) - Inflammatory fibroblastic disease (inflammatory pseudoma)
Pennsylvania (Lehigh Valley Hospital) - Inflammatory myofibroblastic tumor
Pennsylvania (York Hospital) - Leiomyosarcoma (8)
Puerto Rico (University of Puerto Rico) - Inflammatory pseudotumor
Rhode Island (RI Hospital Residents) - Myofibroblastoma
Texas (Lackland AFB) - Spindle cell carcinoma (doubt leiomyosarcoma, I would do several more keratins)
Texas (Propath Associates) - Leiomyosarcoma (2)
Texas (Scott & White Memorial Hospital) - Spindle cell sarcoma
Utah (University of Utah Residents) - Leiomyosarcoma
West Virginia (Greenbrier Valley Medical Center) - Inflammatory myofibroblastic tumor
Australia (North Queensland Pathology Group) - Spindle cell myoepithelial tumor/differential diagnosis, leiomyosarcoma
Australia (Royal Prince Alfred Hospital) - Myofibroblastic sarcoma
Canada (Foothills Medical Center) - Leiomyosarcoma
Hong Kong (Hong Kong Baptist Hospital) - Myofibroblastoma
Jamaica (The University of the West Indies) - Fibrosarcoma
Japan (Yamanashi Medical University) - Stromal sarcoma (3); Leiomyosarcoma (1)
Qatar (Hamad Medical Corporation) - Nodular fasciitis (4); Inflammatory pseudotumor (2)

Case 9 - Diagnosis:

Myofibroblastoma, breast
T-04000, M-95800

Case 9 – References:

Powari M, Srinivasan R and Radotra BD. Myofibroblastoma of the Male Breast. A Diagnostic Problem on Fine-Needle Aspiration Cytology. *Diagn Cytopathol* 2002; 26(5):290-293.
Alam FM, Samarasinghe DS and Pillai RG. Myofibroblastoma of the Breast in an Adolescent. *Saudi Med J* 2002; 23(2):232-233.
Magro G, Bisceglia M, Michal M, et al. Spindle Cell Lipoma-Like tumor, Solitary Fibrous Tumor and Myofibroblastoma of the Breast. A Clinicopathological Analysis of 13 Cases in Favor of a Unifying Histogenetic Concept. *Virchows Arch* 2002; 440(3):249-260.
McMenamin ME, DeSchryver K and Fletcher CD. Fibrous Lesions of the Breast. A Review. *Int J Surg Pathol* 2000; 8(2):99-108.
McMenamin ME and Fletcher CD. Mammary-Type Myofibroblastoma of Soft Tissue. A Tumor Closely Related to Spindle Cell Lipoma. *Am J Surg Pathol* 2001; 25(8):1022-1029.
Dockery WD, Singh HR and Wilentz RE. Myofibroblastoma of the Male Breast. Imaging Appearance and Ultrasound-Guided Core Biopsy Diagnosis. *Breast J* 2001; 7(3):192-194.

Case No. 10, Accession No. 29115 **September 2003**

Alameda (Alameda County Medical Center) - Meningioma, atypical
Bakersfield - Meningioma
Baldwin Park (Kaiser Permanente) - Meningioma (3)
Fontana (Kaiser Permanente) - Meningioma
Hayward/Fremont - Meningioma (rhabdoid)
Laguna Beach (South Coast Medical Center) - Meningothelial meningioma
Loma Linda (Loma Linda University Residents) - Meningioma
Long Beach - Meningioma (8)
Mountain View (El Camino Pathology Group) - Rhabdoid meningioma
Orange (Orange County Pathology Medical Group) - Meningioma
Orange (UCI Medical Center Residents) - Secretory meningioma
Sacramento (UC Davis Medical Center) - Meningioma, oncocytic
San Diego (Naval Medical Center) - Meningioma, grade I
San Francisco (San Francisco General Hospital) - Metastatic renal cell vs. meningioma
Santa Barbara (Cottage Hospital) - Chordoid meningioma
Santa Rosa (Santa Rosa Memorial Hospital) - Atypical meningioma (2); Meningioma (1)
Ventura - Meningioma
Alaska (Alaska Native Medical Center) - Atypical meningioma
Arizona (Maryvale Medical Center) - Atypical meningioma
Arizona (St. Josephs Hospital Residents) - Atypical meningioma
Florida (Baptist Hospital) - Meningioma (2)
Florida (Munroe Regional Medical Center) - Meningioma
Florida (Pathology Associates) - Meningioma
Florida (Winter Haven Hospital) - Meningioma
Illinois (Northwestern Memorial Hospital) - Atypical meningioma
Louisiana (Louisiana State University Medical Center) - Meningioma
Maryland (National Naval Medical Center) - Meningioma chordoid (11)
Massachusetts (Berkshire Medical Center) - Meningioma, chordoid type (9)
Massachusetts (New England Medical Center Residents) - Meningioma, oncocytic
Michigan (Oakwood Hospital) - Meningioma
Michigan (St. Joseph Mercy Hospital) - Meningioma
Minnesota (Fairview Southdale Hospital) - Meningioma
Mississippi (University of Mississippi Medical Center) - Atypical meningioma
Nebraska (Creighton University School of Medicine Residents) - Meningioma
Nevada (Western Pathology Associates) - Chordoid meningioma
New Jersey (Overlook Hospital) - Meningioma
New York (Long Island Jewish Medical Center) - Chordoid meningioma
New York (Nassau University Medical Center) - Meningioma, atypical
New York (New York Presbyterian Hospital Residents) - Meningioma with necrosis
New York (Stony Brook University Hospital Residents) - Oncocytic meningioma
North Carolina (Duke University Medical Center Residents) - Meningioma ?, atypical
Ohio (Medical College of Ohio Residents) - Extracranial meningioma
Oklahoma (Tulsa) - Chordoid meningioma
Oklahoma (University of Oklahoma HSC Residents) - Rhabdoid meningioma
Pennsylvania (Allegheny General Hospital) - Meningioma
Pennsylvania (Centre Community Hospital) - Meningothelial meningioma
Pennsylvania (Conemaugh Memorial Medical Center) - Angiomatous meningioma
Pennsylvania (Drexel University College of Medicine) - Meningioma
Pennsylvania (Lehigh Valley Hospital) - Meningioma
Pennsylvania (York Hospital) - Meningioma (8)
Puerto Rico (University of Puerto Rico) - Meningioma, rhabdoid type

Rhode Island (RI Hospital Residents) - Meningioma
Texas (Lackland AFB) - Meningioma
Texas (Propath Associates) - Aggressive meningioma (2)
Texas (Scott & White Memorial Hospital) - Meningioma
Utah (University of Utah Residents) - Meningioma
West Virginia (Greenbrier Valley Medical Center) - Meningioma, meningothelial
Australia (North Queensland Pathology Group) - Grade I, meningioma
Australia (Royal Prince Alfred Hospital) - (? secretory) meningioma
Canada (Foothills Medical Center) - Atypical meningioma
Hong Kong (Hong Kong Baptist Hospital) - Meningioma
Jamaica (The University of the West Indies) - Metastatic adenocarcinoma, poorly differentiated
Japan (Yamanashi Medical University) - Meningioma secretory (2); Rhabdoid (1); Ependymoma (1)
Qatar (Hamad Medical Corporation) - Rhabdoid meningioma, WHO, Grade III

Case 10 - Diagnosis:

Chordoid meningioma, frontal fossa
T-Y0111, M-95300

Neuropathology consultation: Boleslaw Liwnicz, M.D.: "Choroid meningioma."

Case 10 - References:

Ikeda K, Shoin K, Mohri M, et al. Surgical Indications and Microsurgical Anatomy of the Transchoroidal Fissure Approach for Lesions In and Around the Ambient Cistern. *Neurosurg* 2002; 50(5):1114-1119.
Chaskis C, Buisseret T, Michotte A, et al. Meningioma of the Fourth Ventricle Presenting with Intermittent Behavior Disorders. A Case Report and Review of the Literature. *J Clin Neurosci* 2001; 59-62.
Muller S, Zirkel D, Westphal M, et al. Genomic Imprinting of IGF2 and H19 in Human Meningiomas. *Eur J Cancer* 2000; 36(5):651-655.
Matsumoto S, Yamamoto T, Ban S, et al. A Case of Deep Sylvian Meningioma Presenting Temporal Lobe Epilepsy. *No To Shinkei* 1995; 47(5):503-508.