1163

CALIFORNIA
TUMOR TISSUE REGISTRY

"GENITOURINARY PATHOLOGY"

Study Cases, Subscription A

February 2003

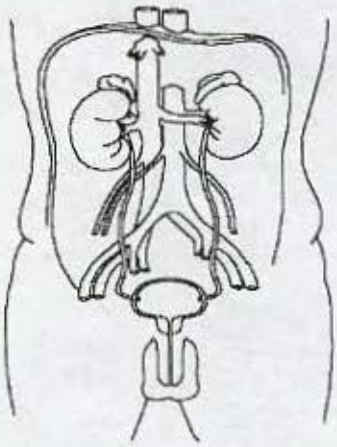

California Tumor Tissue Registry
c/o: Department of Pathology and Human Anatomy
Loma Linda University School of Medicine
11021 Campus Avenue, AH 335
Loma Linda, California 92350
(909) 558-4788
FAX: (909) 558-0188
E-mail: cttr@linkline.com
Web site & Case of the Month: www.cttr.org

Target audience:

Practicing pathologists and pathology residents.

Goal:

To acquaint the participant with the histologic features of a variety of benign and malignant neoplasms and tumor-like conditions.

Objectives:

The participant will be able to recognize morphologic features of a variety of benign and malignant neoplasms and tumor-like conditions and relate those processes to pertinent references in the medical literature.

Educational methods and media:

Review of representative glass slides with associated histories.
Feedback on consensus diagnoses from participating pathologists.
Listing of selected references from the medical literature.

Principal faculty:

Weldon K. Bullock, MD
Donald R. Chase, MD

CME Credit:

Loma Linda University School of Medicine designates this continuing medical education activity for up to 2 hours of Category I of the Physician's Recognition Award of the American Medical Association.

CME credit is offered for the subscription year only.

Accreditation:

Loma Linda University School of Medicine is accredited by the Accreditation Council for Continuing Medical Education (ACCME) to sponsor continuing medical education for physicians.

Contributor: Ellen C. Ko, M.D.
Birmingham, AL

Case No. 1 - February 2003

Tissue from: Bilateral kidneys

Accession #29385

Clinical Abstract:

A 52-year-old male with end stage renal disease, on dialysis, underwent bilateral nephrectomy.

Gross Pathology:

The 2055 gram left kidney was 29 x 17 x 12 cm. It had multiple fluid-filled cysts up to 5 cm in greatest diameter. The 2140 gram right kidney was 28 x 14 x 12 cm and contained numerous thin walled semitranslucent cysts to 4.0 cm in greatest diameter.

Contributor: LLUMC Pathology Group (cz)
Loma Linda, CA

Case No. 2 - February 2003

Tissue from: Right kidney

Accession #28925

Clinical Abstract:

This 68-year-old female was found to have a right renal mass.

Gross Pathology:

The 210 gram, 23.0 x 13.0 x 10.0 cm kidney had a 13.0 x 13.0 x 6.0 cm well-circumscribed, rounded, multilocular cystic mass in the lower pole. It was sharply demarcated from the adjacent renal parenchyma and bulged into, but did not invade, the renal pelvis.

Contributor: John McGill, M.D.
Pasadena, CA

Case No. 3 - February 2003

Tissue from: Right kidney

Accession #29425

Clinical Abstract:

Complaining of vague abdominal symptoms, this 57-year-old female underwent an ultrasound and CT scan, which showed a right renal mass. She had no renal or urinary tract complaints.

Gross Pathology:

The 114 gram, 10.0 x 5.8 x 3.5 cm kidney had a 3.0 x 3.0 x 2.0 cm bulging brown tumor in the upper pole. The cut surface showed a central stellate scar.

Contributor: LLUMC (Pathology Group) (wc)
Loma Linda, CA

Case No. 4 - February 2003

Tissue from: Left kidney

Accession #29557

Clinical Abstract:

This 54-year-old male was discovered to have a mass in his left kidney.

Gross Pathology:

The 1345 gram specimen included kidney, adrenal gland and perinephric fat. About 80% of the kidney was replaced by a 14 cm diameter tumor composed of yellow to pink-tan cords and nodules. The tumor filled the renal pelvis, invaded the renal vein and extended into perinephric fat and the accompanying adrenal gland.

Contributor: John McGill, M.D.
Pasadena, CA

Case No. 5 - February 2003

Tissue from: Right kidney

Accession #29529

Clinical Abstract:

At the time of an elective total body scan, this 52-year-old male was found to have a solid mass in the upper pole of his right kidney.

Gross Pathology:

The 172 gram kidney contained a 4.5 x 2.5 x 2.3 cm mass in the superior pole. The cut surface was variegated golden yellow and red-tan, solid, focally fibrous and hemorrhagic.

Contributor: John J. McGill, M.D.
Pasadena, CA

Case No. 6 - February 2003

Tissue from: Left kidney

Accession #29549

Clinical Abstract:

While being treated for recurrent urinary tract infections, this 57-year-old male was found, on ultrasound and CT scan, to have a large left renal mass.

Gross Pathology:

The 626 gram, 15.0 x 10.5 x 7.5 cm left kidney contained a well-circumscribed pink-tan firm neoplasm measuring 7.5 x 7.5 x 7.0 cm, which invaded through the renal capsule into surrounding fat. The cut surface was solid with areas of necrosis.

SPECIAL STUDIES (Outside Facility):

CD117	positive
CAM5.2	positive

Contributor: Tikoes A Blakenberg, M.D.
Redding, CA

Case No. 7 - February 2003

Tissue from: Right testicle

Accession #28804

Clinical Abstract:

On self examination, this 50-year-old male noted a mass in his right testicle.

Gross Pathology:

The 50 gram orchiectomy specimen included a 6 x 3.5 x 3 cm testis. The cut surface showed a 3.0 x 3.0 x 2.0 cm firm, yellow to white fibrous nodule.

Contributor: Jozef Kollin, M.D.
Lakewood, CA

Case No. 8 - February 2003

Tissue from: Left testicle

Accession #29564

Clinical Abstract:

Embarrassed by an enlarged left testicle, this 14-year-old male hide the problem from his family for a year and a half. Physical examination confirmed a mass in the left testicle. A chest x-ray probable bilateral pulmonary metastases.

Gross Pathology:

The 290 gram testis was 9.5 x 10.0 x 8.0 cm and was completely replaced by a yellow-gray, extensively necrotic tumor.

SPECIAL STUDIES (Outside Facility):

CAM5.2/AE1	positive
EMA	negative
PLAP	few positive cells
AFP	rare positive cells
HCG	negative

Contributor: Anthony Migler, M.D.
Camarillo, CA

Case No. 9 - February 2003

Tissue from: Right testicle

Accession #29393

Clinical Abstract:

This 11-month-old male was found to have a right testicular mass.

Gross Pathology:

The testicle was involved by a 4.0 x 3.5 x 2.5 cm well-defined lobulated mucinous gray-yellow and tan tumor.

Contributor: Richard Johnson, M.D.
Pasadena, CA

Case No. 10 - February 2003

Tissue from: Prostate

Accession #27249

Clinical Abstract:

During work-up for nocturia and painless hematuria, this 71-year-old male was noted to have an enlarged prostate and an elevated PSA. Following biopsy, a radical prostatectomy was performed.

Gross Pathology:

The 56 gram, 5.5 x 4.0 x 4.0 cm prostate specimen contained a 3.5 cm nodule of soft, tan tumor with scattered yellow flecks.

CALIFORNIA
TUMOR TISSUE REGISTRY

GENITOURINARY PATHOLOGY

Minutes – Subscription A

February, 2003

SUGGESTED READING (General Topics from Recent Literature):

Anal Gland Carcinoma. Hobbs CM, Lowry MA, Owen D and Sobin LH. *Cancer* 2001; 92(8):2045-2049.

Significance of Serum Amyloid A on the Prognosis in Patients with Renal Cell Carcinoma. Kimura M, Tomita Y, Imai T, et al. *Cancer* 2001; 92(8):2072-2075.

Mitoxantrone in Patients with Prostate Specific Antigen Progression After Local Therapy for Prostate Carcinoma. DiPaola RS, Chenven ER, Shih WJ, et al. *Cancer* 2001; 92(8):2065-2071.

Incidence Trends and Risk Factors of Carcinoid Tumors. A Nationwide Epidemiologic Study from Sweden. Hemminki K and Li X. *Cancer* 2001; 92(8):2204-2210.

Biased Methods for Estimating Local and Distant Failure Rates in Breast Carcinoma and "Commonsence" Approach. *Cancer* 2001; 92(8):2220-2227.

In Search of the Origins of Modern Surgical Pathology. Gal AA. *Adv Anat Pathol* 2001; 8(1):1-13.

California Tumor Tissue Registry
c/o: Department of Pathology and Human Anatomy
Loma Linda University School of Medicine
11021 Campus Avenue, AH 335
Loma Linda, California 92350
(909) 558-4788
FAX: (909) 558-0188
E-mail: cttr@linkline.com
Web site & Case of the Month: www.cttr.org

FILE DIAGNOSES

CTTR Subscription A February 2003

Case 1:

Adult polycystic kidney disease
T-71000, M-26730

Case 2:

Cystic nephroma, kidney
T-71000, M-83123

Case 3:

Oncocytoma, kidney
T-71000, M-82900

Case 4:

Papillary renal cell carcinoma, kidney
T-71000, M-83123

Case 5:

Conventional renal cell carcinoma, clear cell type, kidney
T-71000, M-83123

Case 6:

Sarcomatoid renal cell carcinoma, kidney
T-71000, M-83123

Case 7:

Spermatocytic seminoma, testis
T-78000, M-86501

Case 8:

Embryonal carcinoma, testis
T-78000, M-90703

Case 9:

Yolk sac tumor ("endodermal sinus tumor"), testis
T-78000, M-90713

Case 10:

Prostatic ductal adenocarcinoma ("endometrioid carcinoma"), prostate
T-77100, M-85003

Bakersfield - Adult polycystic kidney disease
Baldwin Park (Kaiser Permanente) - Adult polycystic kidney disease (3)
Bay Area - Polycystic kidney disease (3)
Fontana (Kaiser Permanente) - Polycystic kidney disease
Hayward/Fremont - Adult (autosomal dominant) polycystic kidney disease
Laguna Beach (South Coast Medical Center) - Adult polycystic kidney disease
Long Beach - Adult type polycystic kidneys with dialysis induced papillary tubular epithelial proliferation (7)
Monterey (Community Hospital of Monterey Peninsula) - Polycystic kidney disease
Mountain View (El Camino Pathology Group) - Adult polycystic kidney disease
Oakland (Kaiser Permenente) - Polycystic kidneys consistent with ESRD (6)
Orange (Orange County Medical Group) - Adult polycystic kidney disease
Orange (UCI Medical Center Residents) - Adult polycystic kidney disease
Sacramento (UC Davis Medical Center) - Acquired renal cystic disease due to dialysis
San Diego (Naval Medical Center) - Autosomal dominant polycystic kidney disease
Santa Barbara (Cottage Hospital) - Polycystic kidney disease
Santa Rosa (Santa Rosa Memorial Hospital) - Adult polycystic kidney disease (2); Autosomal dominant polycystic kidney disease (1)
Ventura - Adult-type polycystic disease
Alaska (Alaska Native Medical Center) - Polycystic kidney disease, adult onset
Alaska (Alaska Pathology Laboratory) - Polycystic kidney disease
Arizona (Phoenix Memorial Hospital) - Adult polycystic kidney
Florida (Baptist Hospital) - Polycystic kidneys
Florida (Munroe Regional Medical Center) - Polycystic kidney
Florida (Winter Haven Hospital) - Polycystic renal disease
Illinois (Evanston Northwestern Health Care) - Adult polycystic kidney disease
Indiana (Fort Wayne) - Adult polycystic kidney disease
Kansas (University of Kansas Medical Center) - Polycystic kidney disease
Louisiana (Louisiana State University Medical Center) - Polycystic kidney with focal papillary dysplasia
Maryland (Johns Hopkins Hospital Residents) - Cystic renal cell carcinoma arising in acquired renal cystic disease (1); Adult onset/autosomal dominant polycystic disease (1)
Maryland (National Naval Medical Center) - Adult-type polycystic kidney disease
Maryland (University of Maryland Residents) - Adult polycystic kidney disease
Massachusetts (Brigham & Women's Hospital) - Adult onset polycystic kidney disease
Massachusetts (New England Medical Center Residents) - Adult polycystic kidney disease
Michigan (Marquette General Hospital) - Autosomal dominant polycystic kidney disease
Michigan (Oakwood Hospital) - Autosomal dominant polycystic kidney disease
Michigan (St. Joseph Mercy Hospital) - Adult polycystic kidney
Mississippi (University of Mississippi Medical Center) - Adult-type polycystic kidney disease
Nebraska (Creighton University School of Medicine Residents) - Polycystic kidney disease
New Jersey (Overlook Hospital) - Autosomal dominant polycystic kidney disease (1); Acquired renal cystic disease (3)
New Mexico (University of New Mexico) - Adult polycystic kidney disease
New York (Stony Brook University Hospital Residents) - Adult polycystic kidney disease
New York (Long Island Jewish Medical Center) - Autosomal dominant polycystic kidney disease
New York (Nassau University Medical Center) - Acquired renal cystic disease, kidney bilateral
New York (Westchester Medical Center) - Adult polycystic kidney disease
North Carolina (Mountain Area Pathology) - Polycystic kidney disease (2); Autosomal dominant cystic kidney disease (2)
Oklahoma (Oklahoma University Pathology Residents) - Adult polycystic kidney disease
Oklahoma (Tulsa) - Acquired renal cystic kidney disease consistent with renal dialysis
Oklahoma (Veterans Affairs Medical Center) - Adult polycystic kidney disease
Pennsylvania (Centre Community Hospital) - Adult (autosomal dominant) polycystic kidney disease
Pennsylvania (Memorial Medical Center) - Adult polycystic kidney

Rhode Island (RI Hospital Pathology Residents) - Adult polycystic kidney disease
Texas (ProPath Services) - Polycystic kidney disease (2)
Texas (Scott & White Memorial Hospital) - Polycystic kidney disease
West Virginia (Greenbrier Valley Medical Center) - Acquired renal cystic disease of dialysis
Wisconsin (Meriter Health Services) - Papillary hyperplasia
Australia (North Queensland Pathology) - Adult polycystic kidney
Australia (Royal Prince Alfred Hospital) - Adult polycystic kidney disease
Canada (Foothills Medical Center) - Polycystic kidney
Hong Kong (Hong Kong Baptist Hospital) - Polycystic kidney disease (adult type)
Japan (Shimada City) - Polycystic kidney
Japan (Yamanashi Medical University) - Acquired multilocular cyst (3)
Qatar (Hamad Medical Corporation) - Acquired cystic disease of kidney

Case 1 - Diagnosis:

Adult polycystic kidney disease
T-71000, M-26730

Case 1 – References:

Churchill DN, Bear JC, Morgan J, et al. Prognosis of Adult Onset Polycystic Kidney Disease Re-Evaluated. *Kidney Int.* 1984; 26(2):190-193.
Dalgaard OZ and Norby S. Autosomal Dominent Polycystic Kidney Disease in the 1980. *Clin Genet* 1989; 36(5):320-325.
Dalaney VB, Adler S, Bruns FJ, et al. Autosomal Dominant Polycystic Kidney Disease. Presentation, Complications and Prognosis. *Kidney Dis* 1985; 5(2):104-111.
Koptides M and Deltas CC. Autosomal Dominant Polycystic Kidney Disease. Molecular Genetics and Molecular Pathogenesis. *Hum Genet* 2000; 107(2):115-126.
Zhou XJ and Kukes G. Pathogenesis of Autosomal Dominant Polycystic Kidney Disease. Role of Apoptosis. *Diagn Mol Pathol* 1998; 7(2):65-68.

Case No. 2, Accession No. 28925 February 2003

Bakersfield - Segmental cystic disease
Baldwin Park (Kaiser Permanente) - Cystic nephroma (multilocular cyst) (1); Multicystic renal cell carcinoma (1); Cystic nephroma (1)
Bay Area - Multicystic nephroma (multilocular cyst) (3)
Fontana (Kaiser Permanente) - Cystic nephroma
Hayward/Fremont - Multilocular cyst (cystic nephroma)
Laguna Beach (South Coast Medical Center) - Cystic nephroma
Long Beach - Multilocular renal cyst (7)
Monterey (Community Hospital of Monterey Peninsula) - Cystic nephroma
Mountain View (El Camino Pathology Group) - Multilocular cystic nephroma
Oakland (Kaiser Permanente) - Multilocular cyst (6)
Orange (Orange County Medical Group) - Multicystic nephroma
Orange (UCI Medical Center Residents) - Cystic nephroma
Sacramento (UC Davis Medical Center) - Adult polycystic disease
San Diego (Naval Medical Center) - Cystic nephroma
Santa Barbara (Cottage Hospital) - Multilocular renal cyst
Santa Rosa (Santa Rosa Memorial Hospital) - Multicystic nephroma (2); Multilocular renal cyst (multilocular cystic nephroma) (1)
Ventura - Multilocular cyst (2)
Alaska (Alaska Native Medical Center) - Cystic nephroma
Alaska (Alaska Pathology Laboratory) - Cystic nephroma
Arizona (Phoenix Memorial Hospital) - Multicystic kidney disease
Florida (Baptist Hospital) - Cystic renal cell carcinoma
Florida (Munroe Regional Medical Center) - Adult cystic nephroma
Florida (Winter Haven Hospital) - Microcystic adenoma

Illinois (Evanston Northwestern Health Care) - Cystic nephroma
Indiana (Fort Wayne) - Cystic nephroma (multilocular cyst), right kidney
Kansas (University of Kansas Medical Center) - Cystic nephroma
Louisiana (Louisiana State University Medical Center) - Cystic nephroma
Maryland (Johns Hopkins Hospital Residents) - Lymphangioma (1); Mixed epithelial, stromal tumor of the kidney disease (1)
Maryland (National Naval Medical Center) - Cystic nephroma
Maryland (University of Maryland Residents) - Cystic nephroma
Massachusetts (Brigham & Women's Hospital) - Adenomatoid tumor
Massachusetts (New England Medical Center Residents) - Cystic nephroma
Michigan (Marquette General Hospital) - Cystic nephroma
Michigan (Oakwood Hospital) - Mixed epithelial and stromal tumor of the kidney
Michigan (St. Joseph Mercy Hospital) - Cystic nephroma
Mississippi (University of Mississippi Medical Center) - Cystic nephroma
Nebraska (Creighton University School of Medicine Residents) - Cystic nephroma
New Jersey (Overlook Hospital) - Congenital cystic nephroma (4)
New Mexico (University of New Mexico) - Cystic nephroma
New York (Stony Brook University Hospital Residents) - Cystic nephroma, rule out cystic renal cell carcinoma
New York (Long Island Jewish Medical Center) - Cystic nephroma, kidney
New York (Nassau University Medical Center) - Renal multilocular cyst, right kidney
New York (Westchester Medical Center) - Cystic nephroma (multicystic kidney)
North Carolina (Mountain Area Pathology) - Cystic nephroma (4)
Oklahoma (Oklahoma University Pathology Residents) - Cystic nephroma
Oklahoma (Tulsa) - Cystic multilocular nephroma
Oklahoma (Veterans Affairs Medical Center) - Multicystic nephroma
Pennsylvania (Centre Community Hospital) - Cystic nephroma
Pennsylvania (Memorial Medical Center) - Cystic nephroma
Rhode Island (RI Hospital Pathology Residents) - Cystic nephroma
Texas (ProPath Services) - Lymphangioma (2)
Texas (Scott & White Memorial Hospital) - Lymphangioma
West Virginia (Greenbrier Valley Medical Center) - Polycystic kidney
Wisconsin (Meriter Health Services) - Cystic nephroma
Australia (North Queensland Pathology) - Multilocular cystic nephroma
Australia (Royal Prince Alfred Hospital) - Cystic nephroma
Canada (Foothills Medical Center) - Multicystic nephroma
Hong Kong (Hong Kong Baptist Hospital) - Medullary sponge kidney
Japan (Shimada City) - Cystic nephroma
Japan (Yamanashi Medical University) - Cystic nephroma (3)
Qatar (Hamad Medical Corporation) - Benign multicystic nephroma (multilocular cyst) or lymphangioma (2nd choice)

Case 2 - Diagnosis:

Cystic nephroma, kidney
T-71000, M-83123

Case 2 - References:

Skomra D, Korobowicz E, Bar K, et al. The Coexistence of Cystic Nephroma and Renal Cortical Adenoma. *Folia Histochem Cytobiol* 2001; 39 Suppl 2:144-145.
Beckwith JB. Revised SIOP Working Classification of Renal Tumors of Childhood. *Med Pediatr Oncol* 2002; 38(2):77-78.
Jenkner A, Camassei FD, Boldrini R, de Sio L, et al. 111 Renal Neoplasms of Childhood. A Clinicopathologic Study. *J Pediatr Surg* 2001 36(10): 1522-1527.
Eble JN and Bonsib SM. Extensively Cystic Renal Neoplasms. Cystic Nephroma, Cystic Partially Differentiated Nephroblastoma, Multilocular Cystic Renal Cell Carcinoma, and Cystic Hamartoma of Renal Pelvis. *Semin Diagn Pathol* 1998; 15(1):2-20.
Tamboli P, Ro JY, Amin MB, Ligato S, et al. Benign Tumors and Tumor-Like Lesions of the Adult Kidney. Part II. Benign Mesenchymal and Mixed Neoplasma, and Tumor-Like Lesions. *Adv Anat Pathol* 2000; 7(1):47-66.

Thibeau JF, Sourtzis S, Lufuma EM, et al. Multilocular Cystic Nephroma in Adults. Unusual Presentation and Review of the Literature. *Prog Urol* 2001; 11(3):507-511.

Case No. 3, Accession No. 29425 **February 2003**

Bakersfield - Oncocytoma
Baldwin Park (Kaiser Permanente) - Oncocytoma (3)
Bay Area - Oncocytoma (3)
Fontana (Kaiser Permanente) - Oncocytoma
Hayward/Fremont - Oncocytoma, kidney
Laguna Beach (South Coast Medical Center) - Oncocytoma
Long Beach - Oncocytoma (7)
Monterey (Community Hospital of Monterey Peninsula) - Oncocytoma
Mountain View (El Camino Pathology Group) - Oncocytoma
Oakland (Kaiser Permanente) - Oncocytoma
Orange (Orange County Medical Group) - Oncocytoma
Orange (UCI Medical Center Residents) - Oncocytoma
Sacramento (UC Davis Medical Center) - Renal oncocytoma
San Diego (Naval Medical Center) - Oncocytoma
Santa Barbara (Cottage Hospital) - Oncocytoma
Santa Rosa (Santa Rosa Memorial Hospital) - Renal oncocytoma (3)
Ventura - Oncocytoma (2)
Alaska (Alaska Native Medical Center) - Oncocytoma
Alaska (Alaska Pathology Laboratory) - Oncocytoma
Arizona (Phoenix Memorial Hospital) - Oncocytoma
Florida (Baptist Hospital) - Oncocytoma
Florida (Munroe Regional Medical Center) - Oncocytoma
Florida (Winter Haven Hospital) - Oncocytoma
Illinois (Evanston Northwestern Health Care) - Renal oncocytoma
Indiana (Fort Wayne) - Renal oncocytoma, right kidney
Kansas (University of Kansas Medical Center) - Oncocytoma
Louisiana (Louisiana State University Medical Center) - Oncocytoma
Maryland (Johns Hopkins Hospital Residents) - Oncocytoma (1); Renal oncocytoma (1)
Maryland (National Naval Medical Center) - Oncocytoma
Maryland (University of Maryland Residents) - Oncocytoma
Massachusetts (Brigham & Women's Hospital) - Oncocytoma
Massachusetts (New England Medical Center Residents) - Oncocytoma
Michigan (Marquette General Hospital) - Oncocytoma
Michigan (Oakwood Hospital) - Oncocytoma
Michigan (St. Joseph Mercy Hospital) - Oncocytoma
Mississippi (University of Mississippi Medical Center) - Oncocytoma
Nebraska (Creighton University School of Medicine Residents) - Renal oncocytoma
New Jersey (Overlook Hospital) - Oncocytoma (4)
New Mexico (University of New Mexico) - Oncocytoma
New York (Stony Brook University Hospital Residents) - Oncocytoma
New York (Long Island Jewish Medical Center) - Renal oncocytoma
New York (Nassau University Medical Center) - Oncocytoma, right kidney
New York (Westchester Medical Center) - Renal oncocytoma
North Carolina (Mountain Area Pathology) - Oncocytoma (4)
Oklahoma (Oklahoma University Pathology Residents) - Oncocytoma
Oklahoma (Tulsa) - Oncocytoma

Oklahoma (Veterans Affairs Medical Center) - Oncocytoma
Pennsylvania (Centre Community Hospital) - Renal oncocytoma
Pennsylvania (Memorial Medical Center) - Oncocytoma
Rhode Island (RI Hospital Pathology Residents) - Renal oncocytoma
Texas (ProPath Services) - Oncocytoma (2)
Texas (Scott & White Memorial Hospital) - Oncocytoma
West Virginia (Greenbrier Valley Medical Center) - Renal oncocytoma
Wisconsin (Meriter Health Services) - Oncocytoma
Australia (North Queensland Pathology) - Renal oncocytoma
Australia (Royal Prince Alfred Hospital) - Oncocytoma; DDx: eosinophilic variant chromophobe renal cell carcinoma
Canada (Foothills Medical Center) - Oncocytoma
Hong Kong (Hong Kong Baptist Hospital) - Oncocytoma
Japan (Shimada City) - Oncocytoma
Japan (Yamanashi Medical University) - Oncocytoma (3)
Qatar (Hamad Medical Corporation) - Oncocytoma

Case 3 - Diagnosis:

Oncocytoma, kidney
T-71000, M-82900

Case 3 - References:

Krishnan B, and Truong LD. Renal Epithelial Neoplasms. The Diagnostic Implications of Electron Microscopic Study in 55 Cases. *Hum Pathol* 2002; 33(1):68-79.

Hes O, Michal M, Boudova L, et al. Small Cell Variant of Renal Oncocytoma—a Rare and Misleading Type of Benign Renal Tumor. *Int J Surg Pathol* 2001; 9(3):215-222.

Karumanchi SA, Merchan J and Sukhatme VP. Renal Cancer. Molecular Mechanisms and Newer Therapeutic Options. *Curr Opin* Nephrol Hypertens 2002; 11(1):37-42.

Stopyra GA, Warhol MJ and Multhaupt HA. Cytokeratin 20 Immunoreactivity in Renal Oncocytomas. *J Histochem Cytochem* 2001; 49(7):919-920.

Phillips JL, Pavlovich CP, Walther M, et al. The Genetic Basis of Renal Epithelial Tumors. Advances in Research and its Impact on Prognosis and Therapy. *Curr Opin Urol* 2001; 11(5):463-469.

Amin MB, Crotty TB, Tickoo SK and Farrow GM. Renal Oncocytoma. A Reappraisal of Morphologic Features with Clinicopathologic Findings in 80 Cases. *Am J Surg Pathol* 1997; 21(1):1-12.

Case No. 4, Accession No. 29557 February 2003

Bakersfield - Chromophil renal cell carcinoma
Baldwin Park (Kaiser Permanente) - Renal cell carcinoma, papillary and clear cell features (3)
Bay Area - Renal cell carcinoma, clear cell type, papillary (3)
Fontana (Kaiser Permanente) - Chromophil renal cell carcinoma
Hayward/Fremont - Papillary renal cell carcinoma (clear cell type, unusual)
Laguna Beach (South Coast Medical Center) - Renal cell carcinoma
Long Beach - Papillary renal cell carcinoma (7)
Monterey (Community Hospital of Monterey Peninsula) - Renal cell carcinoma, favor papillary
Mountain View (El Camino Pathology Group) - Renal cell carcinoma, papillary and clear cell type
Oakland (Kaiser Permanente) - Papillary renal cell carcinoma (6)
Orange (Orange County Medical Group) - Carcinoma, papillary renal cell vs. transitional
Orange (UCI Medical Center Residents) - Renal cell carcinoma, papillary type
Sacramento (UC Davis Medical Center) - Papillary renal cell carcinoma
San Diego (Naval Medical Center) - Papillary renal cell carcinoma, grade II
Santa Barbara (Cottage Hospital) - Papillary renal cell carcinoma
Santa Rosa (Santa Rosa Memorial Hospital) - Renal cell carcinoma (2); Papillary renal cell carcinoma (1)
Ventura - Papillary renal cell carcinoma (2)

Alaska (Alaska Native Medical Center) - Renal cell carcinoma, papillary
Alaska (Alaska Pathology Laboratory) - Renal cell carcinoma, papillary type
Arizona (Phoenix Memorial Hospital) - Chromophobe renal cell carcinoma
Florida (Baptist Hospital) - Papillary renal cell carcinoma
Florida (Munroe Regional Medical Center) - Collecting duct carcinoma
Florida (Winter Haven Hospital) - Collecting duct carcinoma
Illinois (Evanston Northwestern Health Care) - Chromophil (papillary) renal cell carcinoma
Indiana (Fort Wayne) - Papillary chromophil renal cell carcinoma
Kansas (University of Kansas Medical Center) - Renal cell carcinoma, papillary type
Louisiana (Louisiana State University Medical Center) - Renal cell carcinoma, with papillary features
Maryland (Johns Hopkins Hospital Residents) - Papillary renal cell carcinoma (1); Renal cell carcinoma, papillary type, Fuhrman Grade III/IV (1)
Maryland (National Naval Medical Center) - Clear cell renal cell carcinoma (3); Renal cell carcinoma with clear cell and papillary features (7)
Maryland (University of Maryland Residents) - Chromophobe renal cell carcinoma
Massachusetts (Brigham & Women's Hospital) - Type 2, papillary renal cell carcinoma
Massachusetts (New England Medical Center Residents) - Papillary carcinoma
Michigan (Marquette General Hospital) - Renal cell carcinoma (with papillary architecture)
Michigan (Oakwood Hospital) - Papillary renal cell carcinoma
Michigan (St. Joseph Mercy Hospital) - Papillary renal cell carcinoma
Mississippi (University of Mississippi Medical Center) - Renal cell carcinoma, papillary type
Nebraska (Creighton University School of Medicine Residents) - Renal cell carcinoma, papillary type
New Jersey (Overlook Hospital) - Papillary renal cell carcinoma (4)
New Mexico (University of New Mexico) - Papillary renal cell carcinoma
New York (Stony Brook University Hospital Residents) - Papillary renal cell carcinoma
New York (Long Island Jewish Medical Center) - Conventional renal cell carcinoma with papillary features, high grade
New York (Nassau University Medical Center) - Papillary renal cell carcinoma, type 3-eosinophilic, left kidney
New York (Westchester Medical Center) - Papillary renal cell carcinoma
North Carolina (Mountain Area Pathology) - Renal cell carcinoma, clear cell type (3); Papillary renal cell carcinoma (1)
Oklahoma (Oklahoma University Pathology Residents) - Papillary renal cell carcinoma
Oklahoma (Tulsa) - Papillary renal cell carcinoma
Oklahoma (Veterans Affairs Medical Center) - Papillary renal cell carcinoma
Pennsylvania (Centre Community Hospital) - Chromophil renal cell carcinoma (papillary carcinoma)
Pennsylvania (Memorial Medical Center) - Papillary renal cell carcinoma
Rhode Island (RI Hospital Pathology Residents) - Papillary renal cell carcinoma
Texas (ProPath Services) - Renal cell carcinoma, clear cell type with papillary pattern (2)
Texas (Scott & White Memorial Hospital) - High grade renal cell carcinoma (? papillary)
West Virginia (Greenbrier Valley Medical Center) - Renal cell carcinoma, collecting duct
Wisconsin (Meriter Health Services) - Papillary clear cell carcinoma
Australia (North Queensland Pathology) - Chromophil or papillary renal cell carcinoma
Australia (Royal Prince Alfred Hospital) - Conventional (clear cell) renal cell carcinoma with papillary growth pattern (Furman 3)
Canada (Foothills Medical Center) - Papillary renal cell carcinoma
Hong Kong (Hong Kong Baptist Hospital) - Renal cell carcinoma
Japan (Shimada City) - Papillary renal cell carcinoma
Japan (Yamanashi Medical University) - Papillary renal cell carcinoma (2); Bellini duct carcinoma (1)
Qatar (Hamad Medical Corporation) - Papillary renal cell carcinoma (1); Renal pelvis adenocarcinoma (2nd choice)

Case 4 - Diagnosis:

Papillary renal cell carcinoma, kidney
T-71000, M-83123

Case 4 - References:

Kuroda N, Inoue K, Guo L, et al. Expression of CD9/Motility-Related Protein 1 (MRP-1) in Renal Parenchymal Neoplasms. Consistent Expression in Papillary and Chromophobe Renal Cell Carcinomas. *Hum Pathol* 2001; 32(10):1071-1077.

Morrissey C, Martinez A, Zatyka M, et al. Epigenetic Inactivation of the RASSFIA 3p21.3 Tumor Suppressor Gene in Both Clear Cell and Papillary Renal Cell Carcinoma. *Cancer Res* 2001; 61(19):7277-7281.
Delahunt B, Eble JN, McCredie MR, et al. Morphologic Typing of Papillary Renal Cell Carcinoma. Comparison of Growth Kinetics and Patient Survival in 66 Cases. *Hum Pathol* 2001 32(6):590-595.
Amin MB, Corless CL, Renshaw AA, et al. Papillary (Chromophil) Renal Cell Carcinoma. Histomorphologic Characteristics and Evaluation of Conventional Pathologic Prognostic Parameters in 62 Cases. *Am J Surg Pathol* 1997; 21(6):621-635.
Reuter VE. Renal Tumors Exhibiting Granular Cytoplasm. *Semin Diagn Pathol* 1999; 16(2):135-145.

Case No. 5, Accession No. 29529 February 2003

Bakersfield - Renal cell carcinoma, clear cell type
Baldwin Park (Kaiser Permanente) - Renal cell carcinoma, clear cell type (3)
Bay Area - Renal cell carcinoma, clear cell type, solid (3)
Fontana (Kaiser Permanente) - Clear cell, renal cell carcinoma
Hayward/Fremont - Renal cell carcinoma, Fuhrman, grade I-II (low grade)
Laguna Beach (South Coast Medical Center) - Renal cell carcinoma
Long Beach - Clear cell, renal cell carcinoma (7)
Monterey (Community Hospital of Monterey Peninsula) - Renal cell carcinoma, clear cell, grade II
Mountain View (El Camino Pathology Group) - Renal cell carcinoma, clear cell type
Oakland (Kaiser Permanente) - Clear cell renal cell carcinoma, grade I/IV (6)
Orange (Orange County Medical Group) - Renal cell carcinoma, clear cell type
Orange (UCI Medical Center Residents) - Renal cell carcinoma, clear cell type
Sacramento (UC Davis Medical Center) - Clear cell carcinoma, grade I
San Diego (Naval Medical Center) - Clear cell, renal cell carcinoma
Santa Barbara (Cottage Hospital) - Renal cell carcinoma, grade I, clear cell type
Santa Rosa (Santa Rosa Memorial Hospital) - Renal cell carcinoma (1); Renal cell carcinoma, clear cell type (1)
Ventura - Clear cell renal cell carcinoma (2)
Alaska (Alaska Native Medical Center) - Renal cell carcinoma, clear cell
Alaska (Alaska Pathology Laboratory) - Renal cell carcinoma, clear cell type
Arizona (Phoenix Memorial Hospital) - Renal cell carcinoma
Florida (Baptist Hospital) - Clear cell, renal cell carcinoma
Florida (Munroe Regional Medical Center) - Renal cell carcinoma, clear cell type
Florida (Winter Haven Hospital) - Clear cell carcinoma
Illinois (Evanston Northwestern Health Care) - Renal cell carcinoma, clear cell type
Indiana (Fort Wayne) - Clear cell, renal cell carcinoma, right kidney
Kansas (University of Kansas Medical Center) - Renal cell carcinoma, clear cell type
Louisiana (Louisiana State University Medical Center) - Clear cell carcinoma of kidney
Maryland (Johns Hopkins Hospital Residents) - Renal cell carcinoma, conventional (clear cell) type, Furhman grade II of IV (2)
Maryland (National Naval Medical Center) - Renal cell carcinoma, clear cell type
Maryland (University of Maryland Residents) - Renal cell carcinoma, clear cell
Massachusetts (Brigham & Women's Hospital) - Clear cell, renal cell carcinoma
Massachusetts (New England Medical Center Residents) - Conventional renal cell carcinoma
Michigan (Marquette General Hospital) - Renal cell carcinoma (classic clear cell type)
Michigan (Oakwood Hospital) - Conventional renal cell carcinoma
Michigan (St. Joseph Mercy Hospital) - Renal cell carcinoma, clear cell type
Mississippi (University of Mississippi Medical Center) - Renal cell carcinoma, clear cell (conventional) type
Nebraska (Creighton University School of Medicine Residents) - Renal cell carcinoma, clear cell type, (Fuhrman, grade I)
New Jersey (Overlook Hospital) - Clear cell renal cell carcinoma (4)
New Mexico (University of New Mexico) - Clear cell, renal cell carcinoma
New York (Stony Brook University Hospital Residents) - Renal cell carcinoma, conventional cell type, Furhman, grade I/IV
New York (Long Island Jewish Medical Center) - Conventional renal cell carcinoma, low grade I-II
New York (Nassau University Medical Center) - Clear cell, renal cell carcinoma, right kidney

New York (Westchester Medical Center) - Clear cell carcinoma, low nuclear grade
North Carolina (Mountain Area Pathology) - Renal cell carcinoma, clear cell type (4)
Oklahoma (Oklahoma University Pathology Residents) - Clear cell, renal cell carcinoma
Oklahoma (Tulsa) - Renal cell carcinoma, clear cell type
Oklahoma (Veterans Affairs Medical Center) - Conventional renal cell carcinoma, clear cell type
Pennsylvania (Centre Community Hospital) - Renal cell carcinoma, grade I/IV
Pennsylvania (Memorial Medical Center) - Clear cell carcinoma
Rhode Island (RI Hospital Pathology Residents) - Clear cell renal cell carcinoma
Texas (ProPath Services) - Renal cell carcinoma, clear cell type (2)
Texas (Scott & White Memorial Hospital) - Clear cell, renal cell carcinoma
West Virginia (Greenbrier Valley Medical Center) - Renal cell carcinoma, clear cell
Wisconsin (Meriter Health Services) - Clear cell carcinoma, grade II
Australia (North Queensland Pathology) - Clear cell renal cell carcinoma
Australia (Royal Prince Alfred Hospital) - Conventional (clear cell) renal cell carcinoma (Fuhrman I)
Canada (Foothills Medical Center) - Renal cell carcinoma, conventional type (clear cell)
Hong Kong (Hong Kong Baptist Hospital) - Renal cell carcinoma
Japan (Shimada City) - Renal cell carcinoma, clear cell type
Japan (Yamanashi Medical University) - Clear cell renal cell carcinoma (3)
Qatar (Hamad Medical Corporation) - Conventional renal cell carcinoma

Case 5 - Diagnosis:

Conventional renal cell carcinoma, clear cell type, kidney
T-71000, M-83123

Case 5 - References:

Presti JC Jr., Wilhelm M, Reuter V, et al. Allelic Loss on Chromosomes 8 and 9 Correlates with Clinical Outcome in Locally Advanced Clear Cell Carcinoma of the Kidney. *J Urol* 2002; 167(3):1464-1468.

Gunawan B, Huber W, Holtrup M, von Heydebreck A, et al. Prognostic Impacts of Cytogenetic Findings in Clear Cell Renal Cell Carcinoma. Gain of 5q31-qter Predicts a Distinct Clinical Phenotype with Favorable Prognosis. *Cancer Res* 2001; 61(21):7731-7738.

Haitel A, Wiener HG, Neudert B, et al. Expression of the Cell Cycle Proteins p21, p27, and pRb in clear Cell Renal Cell Carcinoma and their Prognostic Significance. *Urol* 2001; 58(3):477-481.

Ficarra V, Righetti R, Martignoni G, et al. Prognostic Value of Renal Cell Carcinoma Nuclear Grading. Multivariate Analysis of 333 Cases. *Urol Int* 2001; 67(2):130-134.

Takahashi M, Rhodes DR, Furge KA, et al. Gene Expression Profiling of Clear Cell Renal Cell Carcinoma. Gene Identification and Prognostic Classification. *Proc Natl Acad Sci* 2001; 98(17):9754-9759.

Case No. 6, Accession No. 29549 February 2003

Bakersfield - Sarcomatoid renal cell carcinoma
Baldwin Park (Kaiser Permanente) - Sarcomatoid renal cell carcinoma (3)
Bay Area - Sarcomatoid renal cell carcinoma (3)
Fontana (Kaiser Permanente) - Sarcomatoid renal cell carcinoma
Hayward/Fremont - Angiomyolipoma
Laguna Beach (South Coast Medical Center) - CD117 +, extra-GIST vs. sarcomatoid carcinoma
Long Beach - Pseudosarcomatous (spindle-cell) renal cell carcinoma (7)
Monterey (Community Hospital of Monterey Peninsula) - Sarcomatoid renal cell carcinoma
Mountain View (El Camino Pathology Group) - Sarcomatoid carcinoma
Oakland (Kaiser Permanente) - Sarcomatoid renal cell carcinoma (6)
Orange (Orange County Medical Group) - Renal cell carcinoma, sarcomatoid
Orange (UCI Medical Center Residents) - Sarcomatoid carcinoma
Sacramento (UC Davis Medical Center) - Sarcomatoid renal cell carcinoma
San Diego (Naval Medical Center) - Grade IV, renal cell carcinoma, unclassified (sarcomatoid)

Santa Barbara (Cottage Hospital) - Sarcomatoid renal cell carcinoma
Santa Rosa (Santa Rosa Memorial Hospital) - Sarcomatoid renal cell carcinoma
Ventura - Sarcomatoid renal cell carcinoma (2)
Alaska (Alaska Native Medical Center) - Renal cell carcinoma, sarcomatoid (2); Sarcomatoid transitional cell carcinoma (1)
Alaska (Alaska Pathology Laboratory) - Sarcomatoid renal cell carcinoma
Arizona (Phoenix Memorial Hospital) - Sarcomatoid renal cell carcinoma
Florida (Baptist Hospital) - Sarcomatoid renal cell carcinoma
Florida (Munroe Regional Medical Center) - Sarcomatoid renal carcinoma
Florida (Winter Haven Hospital) - Sarcomatoid renal cell carcinoma
Illinois (Evanston Northwestern Health Care) - Gastrointestinal stromal tumor
Indiana (Fort Wayne) - Sarcomatoid renal cell carcinoma, left kidney
Kansas (University of Kansas Medical Center) - Renal cell carcinoma, sarcomatoid type
Louisiana (Louisiana State University Medical Center) - Renal cell carcinoma (sarcomatoid variant)
Maryland (Johns Hopkins Hospital Residents) - Sarcomatous urothelial carcinoma (would search for CIS component in renal pelvis) (1); Sarcomatoid renal cell carcinoma (1)
Maryland (National Naval Medical Center) - Renal cell carcinoma , sarcomatoid
Maryland (University of Maryland Residents) - Sarcomatoid renal cell carcinoma
Massachusetts (Brigham & Women's Hospital) - Sarcomatoid renal cell carcinoma
Massachusetts (New England Medical Center Residents) - Sarcomatoid renal cell carcinoma
Michigan (Marquette General Hospital) - Sarcomatoid carcinoma
Michigan (Oakwood Hospital) - Sarcomatoid renal cell carcinoma
Michigan (St. Joseph Mercy Hospital) - Sarcomatoid renal cell carcinoma
Mississippi (University of Mississippi Medical Center) - Sarcomatoid renal cell carcinoma
Nebraska (Creighton University School of Medicine Residents) - Sarcomatoid renal cell carcinoma
New Jersey (Overlook Hospital) - Sarcomatoid renal cell carcinoma (4)
New Mexico (University of New Mexico) - Sarcomatoid renal cell carcinoma
New York (Stony Brook University Hospital Residents) - Sarcomatoid renal cell carcinoma
New York (Long Island Jewish Medical Center) - Sarcomatoid renal cell carcinoma
New York (Nassau University Medical Center) - Sarcomatoid renal cell carcinoma, left kidney
New York (Westchester Medical Center) - Sarcomatoid renal cell carcinoma
North Carolina (Mountain Area Pathology) - Renal cell carcinoma, sarcomatoid type (4)
Oklahoma (Oklahoma University Pathology Residents) - Sarcomatoid renal cell carcinoma
Oklahoma (Tulsa) - Sarcomatoid renal cell carcinoma
Oklahoma (Veterans Affairs Medical Center) - Renal cell carcinoma, unclassified ("sarcomatoid carcinoma")
Pennsylvania (Centre Community Hospital) - Sarcomatoid renal cell carcinoma
Pennsylvania (Memorial Medical Center) - Sarcomatoid renal cell carcinoma
Rhode Island (RI Hospital Pathology Residents) - Sarcomatoid renal cell carcinoma
Texas (ProPath Services) - Stromal sarcoma (2)
Texas (Scott & White Memorial Hospital) - Sarcomatoid renal cell carcinoma
West Virginia (Greenbrier Valley Medical Center) - Renal cell carcinoma, sarcomatoid
Wisconsin (Meriter Health Services) - Angiomyolipoma
Australia (North Queensland Pathology) - Sarcomatoid renal cell carcinoma
Australia (Royal Prince Alfred Hospital) - Sarcomatoid carcinoma
Canada (Foothills Medical Center) - Renal cell carcinoma, sarcomatoid
Hong Kong (Hong Kong Baptist Hospital) - Sarcomatoid renal cell carcinoma
Japan (Shimada City) - Sarcomatoid renal cell carcinoma
Japan (Yamanashi Medical University) - Sarcomatous renal cell carcinoma (2); Xanthogranulomatous pyelonephritis (1)
Qatar (Hamad Medical Corporation) - Sarcomatoid renal cell carcinoma (1); Metanephric adenocarcinoma (2nd choice)

Case 6 - Diagnosis:

Sarcomatoid renal cell carcinoma, kidney
T-71000, M-83123

Case 6 - References:

Mian BM, Bhadkamkar N, Slaton JW, et al. Prognostic Factors and Survival of Patients with Sarcomatoid Renal Cell Carcinoma. *J Urol* 2002; 167(1):65-70.

Leroy X, Wacrenier A, De la Taille A, et al. Immunohistochemical Detection of Fas and Fas Ligand in Sarcomatoid Renal Cell Carcinoma. *APMIS*; 2001; 109(6):469-473.

Kuroiwa K, Konomoto T, Kumazawa J, et al. Cell Proliferative Activity and Expression of Cell-Cell Adhesion Factors (E-Cadherin, Alpha-, Beta-, and Gamma-Catenin, and p120) in Sarcomatoid Renal Cell Carcinoma. *J Surg Oncol* 2001; 77(2):123-131.

de Peralta-Venturina M, Moch H, et al. Sarcomatoid Differentiation in Renal Cell Carcinoma. A Study of 101 Cases. *Am J Surg Pathol* 2001; 25(3):275-284.

Case No. 7, Accession No. 28804 February 2003

Bakersfield - Spermatocytic seminoma
Baldwin Park (Kaiser Permanente) - Spermatocytic seminoma (3)
Bay Area - Seminoma (3)
Fontana (Kaiser Permanente) - Spermatocytic seminoma
Hayward/Fremont - Spermatocytic seminoma
Laguna Beach (South Coast Medical Center) - Spermatocytic seminoma
Long Beach - Spermatocytic seminoma (7)
Monterey (Community Hospital of Monterey Peninsula) - Spermatocytic seminoma
Mountain View (El Camino Pathology Group) - Spermatocytic seminoma
Oakland (Kaiser Permanente) - Classic seminoma (5); Spermatocytic seminoma (1)
Orange (Orange County Medical Group) - Seminoma, spermatocytic
Orange (UCI Medical Center Residents) - Spermatocytic seminoma
Sacramento (UC Davis Medical Center) - Spermatocytic seminoma
San Diego (Naval Medical Center) - Spermatocytic seminoma
Santa Barbara (Cottage Hospital) - Seminoma
Santa Rosa (Santa Rosa Memorial Hospital) - Spermatocytic seminoma (3)
Ventura - Spermatocytic seminoma (2)
Alaska (Alaska Native Medical Center) - Spermatocytic seminoma
Alaska (Alaska Pathology Laboratory) - Spermatocytic seminoma
Arizona (Phoenix Memorial Hospital) - Spermatocytic seminoma
Florida (Baptist Hospital) - Seminoma
Florida (Munroe Regional Medical Center) - Spermatocytic seminoma
Florida (Winter Haven Hospital) - Seminoma
Illinois (Evanston Northwestern Health Care) - Spermatocytic seminoma
Indiana (Fort Wayne) - Spermatocytic seminoma, right testis
Kansas (University of Kansas Medical Center) - Seminoma
Louisiana (Louisiana State University Medical Center) - Spermatocytic seminoma
Maryland (Johns Hopkins Hospital Residents) - Spermatocytic seminoma (2)
Maryland (National Naval Medical Center) - Spermatocytic seminoma
Maryland (University of Maryland Residents) - Spermatocytic seminoma
Massachusetts (Brigham & Women's Hospital) - Spermatocytic seminoma
Massachusetts (New England Medical Center Residents) - Spermatocytic seminoma
Michigan (Marquette General Hospital) - Spermatocytic seminoma
Michigan (Oakwood Hospital) - Spermatocytic seminoma
Michigan (St. Joseph Mercy Hospital) - Spermatocytic seminoma
Mississippi (University of Mississippi Medical Center) - Spermatocytic seminoma
Nebraska (Creighton University School of Medicine Residents) - Spermatocytic seminoma
New Jersey (Overlook Hospital) - Seminoma (4)
New Mexico (University of New Mexico) - Spermatocytic seminoma
New York (Stony Brook University Hospital Residents) - Spermatocytic seminoma
New York (Long Island Jewish Medical Center) - Spermatocytic seminoma, testicle

New York (Nassau University Medical Center) - Spermatocytic seminoma, right testicle
New York (Westchester Medical Center) - Spermatocytic seminoma and IGCNU
North Carolina (Mountain Area Pathology) - Seminoma (4)
Oklahoma (Oklahoma University Pathology Residents) - Spermatocytic seminoma
Oklahoma (Tulsa) - Spermatocytic seminoma
Oklahoma (Veterans Affairs Medical Center) - Spermatocytic seminoma
Pennsylvania (Centre Community Hospital) - Spermatocytic seminoma
Pennsylvania (Memorial Medical Center) - Classic seminoma
Rhode Island (RI Hospital Pathology Residents) - Spermatocytic seminoma
Texas (ProPath Services) - Spermatocytic seminoma (2)
Texas (Scott & White Memorial Hospital) - Seminoma
West Virginia (Greenbrier Valley Medical Center) - Spermatocytic seminoma
Wisconsin (Meriter Health Services) - Seminoma
Australia (North Queensland Pathology) - Spermatocytic seminoma
Australia (Royal Prince Alfred Hospital) - Spermatocytic seminoma
Canada (Foothills Medical Center) - Spermatocytic seminoma
Hong Kong (Hong Kong Baptist Hospital) - Seminoma, classical type
Japan (Shimada City) - Spermatocytic seminoma
Japan (Yamanashi Medical University) - Spermatocytic seminoma (2); Seminoma (1)
Qatar (Hamad Medical Corporation) - Seminoma

Case 7 - Diagnosis:

Spermatocytic seminoma, testis
T-78000, M-86501

Case 7 - References:

Stoop H, van Gurp R, de Krijger R, Geurts van Kessel A, et al. Reactivity of Germ Cell Maturation Stage-Specific Markers in Spermatocytic Seminoma. Diagnostic and Etiological Implications. *Lab Invest* 2001; 81(7):919-928.
Saran RK, Banerjee AK, Gupta SK, et al. Spermatocytic Seminoma. A Cytology and Histology Case Report with Review of the Literature. *Diagn Cytopathol* 1999; 20(4):233-236.
Cummings OW, Ulbright TM, Eble JN, et al. Spermatocytic Seminoma. An Immunohistochemical Study. *Hum Pathol* 1994; 25(1):54-59.
Eble JN. Spermatocytic Seminoma. *Hum Pathol* 1994; 25(10):1035-1042.
Dekker I, Rozeboom T, Delemarre J, et al. Placental-Like Alkaline Phosphatase and DNA Flow Cytometry in Spermatocytic Seminoma. *Cancer* 19992; 69(4):993-996.

Case No. 8, Accession No. 29564 February 2003

Bakersfield - Embryonal carcinoma
Baldwin Park (Kaiser Permanente) - Embryonal carcinoma (3)
Bay Area - Mixed germ cell tumor (predominant embryonal/yolk sac) (3)
Fontana (Kaiser Permanente) - Embryonal carcinoma
Hayward/Fremont - Embryonal carcinoma (possible minor yolk sac component)
Laguna Beach (South Coast Medical Center) - Embryonal carcinoma
Long Beach - Embryonal carcinoma (7)
Monterey (Community Hospital of Monterey Peninsula) - Non-Seminomatous Germ Cell Tumor, embryonal vs. mixed (yolk sac and embryonal)
Mountain View (El Camino Pathology Group) - Embryonal carcinoma
Oakland (Kaiser Permanente) - Embryonal carcinoma (6)
Orange (Orange County Medical Group) - Embryonal carcinoma
Orange (UCI Medical Center Residents) - Embryonal carcinoma
Sacramento (UC Davis Medical Center) - Embryonal carcinoma
San Diego (Naval Medical Center) - Embryonal carcinoma
Santa Barbara (Cottage Hospital) - Mixed germ cell tumor, predominantly yolk sac with embryonal carcinoma

Santa Rosa (Santa Rosa Memorial Hospital) - Embryonal carcinoma (3)
Ventura - Yolk sac tumor (2)
Alaska (Alaska Native Medical Center) - Embryonal carcinoma (3); ? small focus of yolk sac (1)
Alaska (Alaska Pathology Laboratory) - Embryonal carcinoma
Arizona (Phoenix Memorial Hospital) - Mixed germ cell neoplasm, predominantly embryonal carcinoma with focal yolk sac tumor
Florida (Baptist Hospital) - Embryonal carcinoma
Florida (Munroe Regional Medical Center) - Embryonal carcinoma
Florida (Winter Haven Hospital) - Mixed germ cell tumor
Illinois (Evanston Northwestern Health Care) - Embryonal carcinoma
Indiana (Fort Wayne) - Embryonal carcinoma
Kansas (University of Kansas Medical Center) - Mixed germ cell tumor
Louisiana (Louisiana State University Medical Center) - Embryonal carcinoma
Maryland (Johns Hopkins Hospital Residents) - Embryonal carcinoma (1); Embryonal carcinoma with vascular invasion (1)
Maryland (National Naval Medical Center) - Mixed germ cell tumor with embryonal carcinoma and yolk sac tumor components (7); Embryonal carcinoma (3)
Maryland (University of Maryland Residents) - Mixed germ cell tumor, predominantly embryonal carcinoma, Yolk sac tumor (2nd choice)
Massachusetts (Brigham & Women's Hospital) - Embryonal carcinoma
Massachusetts (New England Medical Center Residents) - High grade mixed germ cell tumor
Michigan (Marquette General Hospital) - Embryonal carcinoma
Michigan (Oakwood Hospital) - Embryonal carcinoma, with small focus of yolk sac tumor
Michigan (St. Joseph Mercy Hospital) - Embryonal carcinoma
Mississippi (University of Mississippi Medical Center) - Embryonal carcinoma
Nebraska (Creighton University School of Medicine Residents) - Embryonal carcinoma
New Jersey (Overlook Hospital) - Embryonal carcinoma (4)
New Mexico (University of New Mexico) - Embryonal carcinoma
New York (Stony Brook University Hospital Residents) - Embryonal carcinoma
New York (Long Island Jewish Medical Center) - Embryonal carcinoma, testicle
New York (Nassau University Medical Center) - Embryonal carcinoma, left testicle
New York (Westchester Medical Center) - Embryonal carcinoma
North Carolina (Mountain Area Pathology) - Embryonal carcinoma (4)
Oklahoma (Oklahoma University Pathology Residents) - Mixed germ cell tumor with embryonal and yolk sac components
Oklahoma (Tulsa) - Embryonal carcinoma
Oklahoma (Veterans Affairs Medical Center) - Non-seminomatous germ cell tumor, predominantly embryonal carcinoma with minor yolk sac tumor component
Pennsylvania (Centre Community Hospital) - Embryonal carcinoma
Pennsylvania (Memorial Medical Center) - Malignant mixed germ cell tumor (embryonal, yolk sac tumor)
Rhode Island (RI Hospital Pathology Residents) - Embryonal carcinoma
Texas (ProPath Services) - Embryonal carcinoma (2)
Texas (Scott & White Memorial Hospital) - Embryonal carcinoma
West Virginia (Greenbrier Valley Medical Center) - Embryonal carcinoma
Wisconsin (Meriter Health Services) - Embryonal carcinoma
Australia (North Queensland Pathology) - Embryonal carcinoma
Australia (Royal Prince Alfred Hospital) - Embryonal carcinoma
Canada (Foothills Medical Center) - Embryonal carcinoma
Hong Kong (Hong Kong Baptist Hospital) - Embryonal carcinoma
Japan (Shimada City) - Embryonal carcinoma
Japan (Yamanashi Medical University) - Embryonal carcinoma and yolk sac tumor (2); Embryonal carcinoma (1)
Qatar (Hamad Medical Corporation) - Embryonal carcinoma

Case 8 - Diagnosis:

Embryonal carcinoma, testis
T-78000, M-90703

Case 8 – References:

Blough RI, Heerema NA, Albers P, et al. Fluorescence In-Situ Hybridization on Nuclei from Paraffin-Embedded Tissue in Low Stage Pure Embryonal Carcinoma of the Testis. *J Urol* 1998; 159(1):240-244.

Leroy X, Augusto D, Leteurtre E, et al. CD30 and CD117 (c-kit) Used in Combination Are Useful for Distinguishing Embryonal Carcinoma from Seminoma. *J Histochem Cytochem* 2002 50(2):283-285.

Hermans BP, Sweeney CJ, Foster RS, et al. Risk of Systemic Metastases in Clinical Stage I Nonseminoma Germ Cell Testis Tumor Managed by Retroperitoneal Lymph Node Dissection. *J Urol* 2000; 163(6):1721-1724.

Latza U, Foss HD, Durkop H, et al. CD30 Antigen in Embryonal Carcinoma and Embryogenesis and Release of the Soluble Molecule. *Am J Pathol* 1995; 146(2):463-471.

Berney DM, Shamash J, Pieroni K, et al. Loss of CD30 Expression in Metastatic Embryonal Carcinoma. The Effects of Chemotherapy? *Histopathol* 2001; 39(4):382-385.

Case No. 9, Accession No. 29393 February 2003

Bakersfield - Yolk sac tumor
Baldwin Park (Kaiser Permanente) - Yolk sac tumor (3)
Bay Area - Endodermal sinus (yolk sac) tumor (3)
Fontana (Kaiser Permanente) - Endodermal sinus tumor (yolk sac tumor)
Hayward/Fremont - Yolk sac carcinoma, juvenile type
Laguna Beach (South Coast Medical Center) - Yolk sac tumor
Long Beach - Endodermal sinus tumor (7)
Monterey (Community Hospital of Monterey Peninsula) - Yolk sac tumor vs. endodermal sinus tumor
Mountain View (El Camino Pathology Group) - Endodermal sinus tumor
Oakland (Kaiser Permanente) - Endodermal sinus tumor (6)
Orange (Orange County Medical Group) - Yolk sac tumor
Orange (UCI Medical Center Residents) - Yolk sac tumor
Sacramento (UC Davis Medical Center) - Yolk sac tumor
San Diego (Naval Medical Center) - Yolk sac tumor
Santa Barbara (Cottage Hospital) - Yolk sac tumor
Santa Rosa (Santa Rosa Memorial Hospital) - Endodermal sinus tumor (2); Yolk sac (endodermal sinus) tumor (1)
Ventura - Yolk sac tumor (2)
Alaska (Alaska Native Medical Center) - Yolk sac tumor (endodermal sinus and microcystic patterns)
Alaska (Alaska Pathology Laboratory) - Yolk sac tumor
Arizona (Phoenix Memorial Hospital) - Yolk sac tumor (endodermal sinus tumor)
Florida (Baptist Hospital) - Yolk sac tumor
Florida (Munroe Regional Medical Center) - Yolk sac carcinoma
Florida (Winter Haven Hospital) - Yolk sac tumor
Illinois (Evanston Northwestern Health Care) - Yolk sac tumor
Indiana (Fort Wayne) - Infantile yolk sac tumor, right testis
Kansas (University of Kansas Medical Center) - Yolk sac tumor
Louisiana (Louisiana State University Medical Center) - Endodermal sinus tumor
Maryland (Johns Hopkins Hospital Residents) - Yolk sac tumor (2)
Maryland (National Naval Medical Center) - Yolk sac tumor
Maryland (University of Maryland Residents) - Yolk sac tumor
Massachusetts (Brigham & Women's Hospital) - Yolk sac tumor
Massachusetts (New England Medical Center Residents) - Endodermal sinus tumor
Michigan (Marquette General Hospital) - Yolk sac tumor
Michigan (Oakwood Hospital) - Yolk sac tumor
Michigan (St. Joseph Mercy Hospital) - Yolk sac tumor
Mississippi (University of Mississippi Medical Center) - Yolk sac tumor
Nebraska (Creighton University School of Medicine Residents) - Yolk sac tumor
New Jersey (Overlook Hospital) - Yolk sac carcinoma (4)

New Mexico (University of New Mexico) - Yolk sac tumor
New York (Stony Brook University Hospital Residents) - Yolk sac tumor with angiofat invasion
New York (Long Island Jewish Medical Center) - Yolk sac tumor, testicle
New York (Nassau University Medical Center) - Yolk sac tumor, right testicle
New York (Westchester Medical Center) - Yolk sac tumor
North Carolina (Mountain Area Pathology) - Yolk sac tumor (4)
Oklahoma (Oklahoma University Pathology Residents) - Endodermal sinus (yolk sac) tumor
Oklahoma (Tulsa) - Yolk sac tumor (endodermal sinus tumor)
Oklahoma (Veterans Affairs Medical Center) - Yolk sac tumor
Pennsylvania (Centre Community Hospital) - Yolk sac tumor
Pennsylvania (Memorial Medical Center) - Yolk sac tumor
Rhode Island (RI Hospital Pathology Residents) - Yolk sac tumor
Texas (ProPath Services) - Yolk sac tumor (endodermal sinus tumor) (2)
Texas (Scott & White Memorial Hospital) - Yolk sac tumor
West Virginia (Greenbrier Valley Medical Center) - Yolk sac tumor
Wisconsin (Meriter Health Services) - Yolk sac tumor
Australia (North Queensland Pathology) - Yolk sac tumor
Australia (Royal Prince Alfred Hospital) - Yolk sac tumor
Canada (Foothills Medical Center) - Endodermal sinus tumor (yolk sac tumor)
Hong Kong (Hong Kong Baptist Hospital) - Yolk sac tumor
Japan (Shimada City) - Polyembryoma
Japan (Yamanashi Medical University) - Yolk sac tumor (3)
Qatar (Hamad Medical Corporation) - Yolk sac tumor

Case 9 - Diagnosis:

Yolk sac tumor ("endodermal sinus tumor"), testis
T-78000, M-90713

Case 9 – References:

Foster RS, Hermans B, Bihrle R, et al. Clinical Stage I Pure Yolk Sac Tumor of the Testis in Adults has Different Clinical Behavior Than Juvenile Yolk Sac Tumor. *J Urol* 2000; 164(6):1943-1944.

Cheville JC. Classification and Pathology of Testicular Germ Cell and Sex Cord-Stromal Tumors. *Urol Clin North Am* 1999; 26(3):595-609.

Liu HC, Liang DC, Chen SH, et al. The Stage I Yolk Sac Tumor of Testis in Children Younger Than 2 Years, Chemotherapy or Not? *Pediatr Hematol Oncol* 1998; 15(3):223-228.

Michael H, Lucia J, Foster RS, et al. The Pathology of Late Recurrence of Testicular Germ Cell Tumors. *Am J Surg Pathol* 2000; 24(2):257-273.

Billings SD, Roth LM and Ulbright TM. Microcystic Leydig Cell Tumors Mimicking Yolk Sac Tumor. A Report of Four Cases. *Am J Surg Pathol* 1999; 23(5):546-551.

Case No. 10, Accession No. 27249 February 2003

Bakersfield - Comedocarcinoma of prostate
Baldwin Park (Kaiser Permanente) - Adenocarcinoma prostate consistent with extra prostatic extension vs. prostatic ductal carcinoma (1); Prostate duct carcinoma (1); Prostatic duct carcinoma (with extraprostatic extension) (1)
Bay Area - Prostatic adenocarcinoma (3)
Fontana (Kaiser Permanente) - Prostatic duct adenocarcinoma
Hayward/Fremont - Ductal (endometrioid) carcinoma, prostate
Laguna Beach (South Coast Medical Center) - Comedocarcinoma
Long Beach - Adenocarcinoma of prostate duct origin (7)
Monterey (Community Hospital of Monterey Peninsula) - Prostate carcinoma, grade 3
Mountain View (El Camino Pathology Group) - Invasive adenocarcinoma, Gleason 4+5 (prostatic duct adenocarcinoma)
Oakland (Kaiser Permanente) - Ductal type adenocarcinoma (3); High grade prostate carcinoma (3)

Orange (Orange County Medical Group) - Adenocarcinoma
Orange (UCI Medical Center Residents) - Prostate ductal carcinoma
Sacramento (UC Davis Medical Center) - Prostatic duct adenocarcinoma
San Diego (Naval Medical Center) - Prostatic duct carcinoma, Gleason 5+5
Santa Barbara (Cottage Hospital) - Prostatic duct adenocarcinoma
Santa Rosa (Santa Rosa Memorial Hospital) - High-grade prostatic adenocarcinoma with comedonecrosis (2); High grade prostatic adenocarcinoma (1)
Ventura - Prostatic duct adenocarcinoma (2)
Alaska (Alaska Native Medical Center) - Prostate duct carcinoma (cribriform pattern)
Alaska (Alaska Pathology Laboratory) - Prostatic duct adenocarcinoma
Arizona (Phoenix Memorial Hospital) - Prostatic duct adenocarcinoma
Florida (Baptist Hospital) - Endometrioid carcinoma of prostate
Florida (Munroe Regional Medical Center) - Prostatic duct adenocarcinoma
Florida (Winter Haven Hospital) - Prostatic ductal adenocarcinoma
Illinois (Evanston Northwestern Health Care) - Adenocarcinoma of prostate with endometrioid features and necrosis
Indiana (Fort Wayne) - Gleason 8, infiltrating cribriform adenocarcinoma of prostate
Kansas (University of Kansas Medical Center) - Ductal prostatic adenocarcinoma, endometrioid type
Louisiana (Louisiana State University Medical Center) - Prostatic duct adenocarcinoma with endometrioid features
Maryland (Johns Hopkins Hospital Residents) - Prostatic duct carcinoma (1); Cribriform prostatic duct carcinoma, with extraprostatic extension and at the inked surgical margin (1)
Maryland (National Naval Medical Center) - Prostatic adenocarcinoma of large duct origin
Maryland (University of Maryland Residents) - Prostatic adenocarcinoma (comedocarcinoma, Gleason 5+5=10
Massachusetts (Brigham & Women's Hospital) - Prostatic ductal adenocarcinoma, endometrioid type
Massachusetts (New England Medical Center Residents) - Comedocarcinoma
Michigan (Marquette General Hospital) - Prostatic ductal ("endometrioid") carcinoma
Michigan (Oakwood Hospital) - Prostatic duct carcinoma
Michigan (St. Joseph Mercy Hospital) - Adenocarcinoma
Mississippi (University of Mississippi Medical Center) - Prostatic duct adenocarcinoma
Nebraska (Creighton University School of Medicine Residents) - Prostatic duct carcinoma
New Jersey (Overlook Hospital) - Prostatic duct carcinoma (4)
New Mexico (University of New Mexico) - Prostatic adenocarcinoma, duct variant
New York (Stony Brook University Hospital Residents) - Prostate adenocarcinoma, Gleason score 8 (5+3), with component
New York (Long Island Jewish Medical Center) - Prostatic ductal adenocarcinoma (comedocarcinoma of prostate)
New York (Nassau University Medical Center) - Comedoadenocarcinoma of prostate
New York (Westchester Medical Center) - Prostatic duct carcinoma
North Carolina (Mountain Area Pathology) - Prostatic duct carcinoma (3); Large duct carcinoma (prostatic duct carcinoma)
Oklahoma (Oklahoma University Pathology Residents) - Prostatic duct (endometrioid) carcinoma
Oklahoma (Tulsa) - Ductal "endometrioid" type B carcinoma
Oklahoma (Veterans Affairs Medical Center) - Ductal (endometrioid) carcinoma of prostate, type B
Pennsylvania (Centre Community Hospital) - Ductal adenocarcinoma with comedocarcinoma differentiation
Pennsylvania (Memorial Medical Center) - High grade adenocarcinoma (ductal type)
Rhode Island (RI Hospital Pathology Residents) - Prostate adenocarcinoma with comedo and cribriform features, Gleason score 8 (5+3)
Texas (ProPath Services) - Adenocarcinoma of prostate (1); Adenocarcinoma of prostate, cribriform type (1)
Texas (Scott & White Memorial Hospital) - Prostatic duct carcinoma
West Virginia (Greenbrier Valley Medical Center) - Prostatic duct carcinoma
Wisconsin (Meriter Health Services) - Prostatic duct adenocarcinoma
Australia (North Queensland Pathology) - Intraduct and invasive prostatic duct carcinoma
Australia (Royal Prince Alfred Hospital) - Prostatic ductal adenocarcinoma (endometrioid)
Canada (Foothills Medical Center) - High grade prostatic carcinoma with ductal features
Hong Kong (Hong Kong Baptist Hospital) - Prostatic duct adenocarcinoma
Japan (Shimada City) - Prostatic duct carcinoma
Japan (Yamanashi Medical University) - Prostatic ductal carcinoma (2); Adenocarcinoma (1)

Qatar (Hamad Medical Corporation) - Large duct adenocarcinoma (1); Endometrioid variant (2nd choice)

Case 10 - Diagnosis:

Prostatic ductal adenocarcinoma ("endometroid carcinoma"), prostate
T-77100, M-85003

Case 10 - References:

Christensen WN, Steinberg WN, Walsh PC, et al. Prostatic Duct Adenocarcinoma. Findings at Radical Prostatectomy. *Cancer* 1991; 67(8):2118-2124.

Brinker DA, Potter SR and Epstein JI. Ductal Adenocarcinoma of the Prostate Diagnosed on Needle Biopsy. Correlation with Clinical and Radical Prostatectomy Findings and Progression. *Am J Surg Pathol* 1999; 23(12):1471-1479.

Bock BJ and Bostwick DG. Does Prostatic Ductal Adenocarcinoma Exist. *Am J Surg Pathol* 1999; 23(7):781-785.

Vandersteen DP, Wiemerslage SJ and Cohen MB. Prostatic Duct Adenocarcinoma. A Cytologic and Histologic Case Report with Review of the Literature. *Diagn Cytopathol* 1997; 17(6):480-483.

Millar EK, Sharma NK and Lessells AM. Ductal (Endometrioid) Adenocarcinoma of the Prostate. A Clinicopathological Study of 16 Cases. *Histopathol* 1996; 29(1):11-19.