1163

CALIFORNIA
TUMOR TISSUE REGISTRY

"SURGICAL NEUROPATHOLOGY"

Study Cases, Subscription A

September 2002

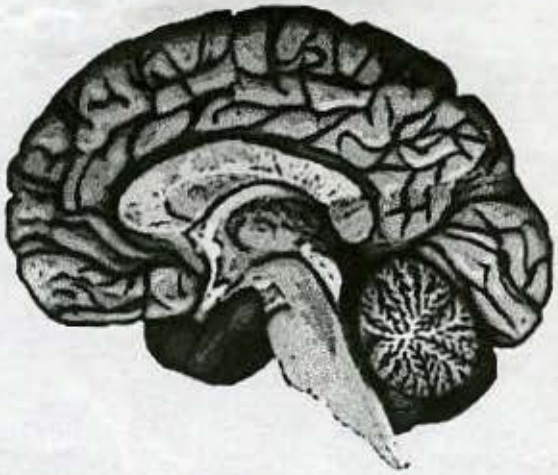

California Tumor Tissue Registry
c/o: Department of Pathology and Human Anatomy
Loma Linda University School of Medicine
11021 Campus Avenue, AH 335
Loma Linda, California 92350
(909) 558-4788
FAX: (909) 558-0188
E-mail: cttr@linkline.com
Web page: www.cttr.org
Web site & Case of the Month: www.cttr.org

Target audience:

Practicing pathologists and pathology residents.

Goal:

To acquaint the participant with the histologic features of a variety of benign and malignant neoplasms and tumor-like conditions.

Objectives:

The participant will be able to recognize morphologic features of a variety of benign and malignant neoplasms and tumor-like conditions and relate those processes to pertinent references in the medical literature.

Educational methods and media:

Review of representative glass slides with associated histories.
Feedback on consensus diagnoses from participating pathologists.
Listing of selected references from the medical literature.

Principal faculty:

Weldon K. Bullock, MD
Donald R. Chase, MD

CME Credit:

Loma Linda University School of Medicine designates this continuing medical education activity for up to 2 hours of Category I of the Physician's Recognition Award of the American Medical Association.

CME credit is offered for the subscription year only.

Accreditation:

Loma Linda University School of Medicine is accredited by the Accreditation Council for Continuing Medical Education (ACCME) to sponsor continuing medical education for physicians.

Contributor: James Ransdell, M.D.
Sacramento, CA

Case No. 1 - September 2002

Tissue from: Brain

Accession #15146

Clinical Abstract:

For 10 years after resection of a left temporal lobe tumor, this 16 year old girl had experienced convulsions. Following a grand mal seizure, she underwent another craniotomy for removal of recurrent tumor.

Gross Pathology:

The 15 gram specimen consisted of multiple fragments of gray-brown partially hemorrhagic, partially cystic tissue.

Contributor: Phillip C. Gordon, M.D.
Winter Haven, FL

Case No. 2 - September 2002

Tissue from: Brain

Accession #29357

Clinical Abstract:

A craniotomy was performed on this 67-year-old male, who had a previous history of resection of a brain tumor. The interval between surgeries and other clinical information is not available.

Gross Pathology:

Multiple fragments of pink-tan vaguely lobular soft tissue formed an 8 cm diameter aggregate.

SPECIAL STUDIES (Outside facility):

EMA	patchy membrane staining
GFAP	negative
S-100	negative
CAM5.2	negative

Contributor: Roger Terry, M.D.
Los Angeles, CA

Case No. 3 - September 2002

Tissue from: Cerebellum

Accession #24070

Clinical Abstract:

After six months of increased lethargy and mental deterioration, this 67-year-old female underwent a CT scan which showed a posterior fossa mass.

Gross Pathology:

The 3.2 cm irregular mass contained several vascular or cystic spaces surrounded by dark brown to hemorrhagic tissue.

Contributor: Richard Davis, M.D.
Los Angeles, CA

Case No. 4 - September 2002

Tissue from: Base of brain

Accession #18923

Clinical Abstract:

About 12 years prior to her last admission, this 48-year-old female presented with headaches and decreased vision. During the ensuing decade, she underwent four craniotomies for unresectable tumor at the base of the brain. She died shortly after her last craniotomy and an autopsy was performed.

Gross Pathology:

A 3.5 x 4.5 x 2.5 cm mass distorted the optic nerve and adjacent structures, extending back to the midpons area. The mass was focally cystic with areas which were variously hemorrhagic, firm or gelatinous.

Contributor: W.C. Herrick, M.D.
El Cajon, CA

Case No. 5 - September 2002

Tissue from: Spinal cord

Accession #22530

Clinical Abstract:

This extra-dural tumor was from the spinal cord of a 72-year-old male.

Gross Pathology:

A large mucinous appearing spinal cord mass was in an extra-dural position near T7.

Contributor: Jay L. Dickerson, M.D.
San Francisco, CA

Case No. 6 - September 2002

Tissue from: Cerebrum

Accession #13433

Clinical Abstract:

Recent headaches in the right frontal-temporal area and double vision brought this 16-year-old female to the hospital. Radiographs showed a large space-occupying lesion in the right cerebrum with extensive calcification to the right of the midline. A craniotomy was performed.

Gross Pathology:

The 18 grams of tumor tissue removed consisted of four separate pieces, the largest measuring 3.5 x 3.0 x 2.0 cm. The gray to yellow tissue was partially cystic, with areas of hemorrhage and focal calcification.

Contributor: Jozef Kollin, M.D.
Lakewood, CA

Case No. 7 - September 2002

Tissue from: Right cheek

Accession #29591

Clinical Abstract:

Eight months after undergoing surgery, chemo- and radiotherapy for adenocarcinoma of the head of the pancreas, this 61-year-old female presented with a hard mass in her right cheek. This was excised.

Gross Pathology:

The gray to red, rubbery-firm portion of tissue measured 4.5 x 3.0 x 2.5 cm and grossly appeared encapsulated.

SPECIAL STUDIES (Outside facility):

CAM5.2/AE1	negative
S-100	positive
Smooth Muscle Actin	negative
Desmin	negative
CD34	positive
Factor VIIIa	positive
HMB-45	negative

Contributor: John R. McGrath, M.D.
Redondo Beach, CA

Case No. 8 - September 2002

Tissue from: Cerebrum

Accession #12988

Clinical Abstract:

After a year of unrelenting headache pain, this 24-year-old female noticed numbness and pain in her left leg and thigh that was progressively getting worse. Radiographs showed a space occupying lesion in the right parietal area. A craniotomy was performed.

Gross Pathology:

The 43 gram, irregular creamy-tan mass measured 7.0 x 5.0 x 2.0 cm. The cut surface was a fairly uniform soft gray-white.

Contributor: Robert Cleland, M.D.
Los Angeles, CA

Case No. 9 - September 2002

Tissue from: Brain

Accession #8693

Clinical Abstract:

For three or four months, this 9-year-old male became increasingly lethargic and in the 3 weeks prior to admission experienced severe headaches. A posterior fossa exploration was performed with subtotal removal of a tumor from the floor of the 4th ventricle.

Gross Pathology:

The 2.0 x 2.0 x 2.0 cm mass consisted of firm white tissue.

Contributor: J.R. Phillips, M.D.
Fresno, CA

Case No. 10 - September 2002

Tissue from: Right temporal lobe

Accession #18994

Clinical Abstract:

Following sudden onset of headaches and double vision, this 20-year-old female underwent resection of a right temporal lobe mass and subsequent radiation therapy. Ten month later she was found to have recurrent tumor and again underwent resection.

Gross Pathology:

The 3.5 x 3.0 x 2.0 cm specimen consisted of multiple, irregular, gray tissue fragments with foci of necrosis.

SPECIAL STUDIES (Outside facility):

CAM5.2	positive
Mak 6	positive
GFAP	positive

CALIFORNIA
TUMOR TISSUE REGISTRY

"SURGICAL NEUROPATHOLOGY"

Minutes – Subscription A

September, 2002

SUGGESTED READING (General Topics from Recent Literature):

High Diagnostic Accuracy of Cytologic Smears of Central Nervous System Tumors. A 15-Year Experience Based on 4,172 Patients. *Acta Cytol* 2002; 46:667-674.

Gastric Stromal Tumors. A Clinicopathologic Study of 77 Cases with Correlation of Features with Nonaggressive and Aggressive Clinical Behaviors. Trupiano JK, Stewart RE, et al. *Am J Surg Pathol* 2002; 26:705-714.

New WHO Histologic Classification Predicts Prognosis of Thymic Epithelial Tumors. A Clinicopathologic Study of 200 Thymoma Cases from China. Chen G, Marx A, et al. *Cancer* 2002; 95:420-429.

Clonality Analysis in Synchronous or Metachronous Tumors of the Female Genital Tract. Matias-Guiu X, Lagarda H, Catasus E, et al. *Int J Gynecol Pathol* 2002; 21(3):205-211.

Dismantling the Germinal Center. Comparing the Processes of Transformation, Regression, and Fragmentation of the Lymphoid Follicle. Jones D. *Advan in Anat Pathol* 2002; 9(2):129-138.

California Tumor Tissue Registry
c/o: Department of Pathology and Human Anatomy
Loma Linda University School of Medicine
11021 Campus Avenue, AH 335
Loma Linda, California 92350
(909) 558-4788
FAX: (909) 558-0188
E-mail: cttr@linkline.com
Web site & Case of the Month: www.cttr.org

FILE DIAGNOSES

CTTR Subscription A September 20002

Case 1:

Clear cell ependymoma, left temporal lobe
T-X2500, M-93913

Case 2:

Atypical meningioma
T-X2000, M-95300

Case 3:

Hemangioblastoma, cerebellum
T-X6000, M-91611

Case 4:

Craniopharyngioma
T-X2000, M-93501

Case 5:

Chordoma, extra-dural, in region of T7
T-X7410, M-93703

Case 6:

Oligodendroglioma, right cerebrum
T-X2000, M-94503

Case 7:

Schwannoma with degenerative changes, cheek
T-Y0300, M-95600

Case 8:

Gemistocytic astrocytoma, right parietal cerebrum
T-X2000, M-94113

Case 9:

Medulloblastoma, floor of 4th ventricle
T-32400, M-94703

Case 10:

Grade 4 fibrillary astrocytoma ("glioblastoma") with epithelial metaplasia, right temporal lobe
T-X2500, M-94003

Bakersfield - Choroid plexus papilloma
Baldwin Park (Kaiser Permanente) - Astroblastoma vs. clear cell ependymoma (1); Ependymoma (2)
Bay Area - Oligiodendroglioma (3); Hemangiopericytoma (1)
Daly City (Seton Medical Center) - Dysembryonic neuroectodermal tumor
Fontana (Kaiser Permanente) - Anaplastic ependymoma
Hayward/Fremont - Grade III, oligodendroglioma
Loma Linda (Loma Linda University Residents) - Anaplastic oligodendroglioma, grade III
Long Beach - Oligodendroglioma (7)
Monterey (Community Hospital of Monterey Peninsula) - Oligodendroglioma
Moreno Valley - Ependymoma, rule out meningioma and astroblastoma
Mountain Area - Neurocytoma (2); Central neurocytoma (1); Extraventricular neurocytoma (1)
Mountain View (El Camino Pathology Group) - Ependymoma
Oakland (Kaiser Permanente) - Ependymoma (3)
Orange (Orange County Medical Group) - Ependymoma
Orange (UCI Medical Center Residents) - Oligodendroglioma, brain
San Diego (Naval Medical Center) - Ependymoma, clear cell type
San Francisco (UCSF Medical Center) - Anaplastic ependymoma
Santa Barbara (Santa Barbara Cottage Hospital) - Low grade oligodendroglioma
Santa Rosa (Santa Rosa Memorial Hospital) - Malignant ependymoma (2); Ependymoma (1)
Ventura (Unilab) - Oligodendroglioma (2); Ependymoma (1)
Alaska (Alaska Native Medical Center) - Meningioma (papillary) (1); Oligodendroglioma (1)
Arizona (Phoenix Memorial Hospital) - Oligodendroglioma
Florida (Munroe Regional Medical Center) - Oligodendroglioma
Florida (Pathology Associates) - Oligodendroglioma
Florida (Winter Haven Hospital) - Ependymoma
Indiana (Fort Wayne) - Astroblastoma, left temporal lobe
Louisiana (Louisiana State University Hospital) - Oligodendroglioma (ependymoma)
Maryland (Johns Hopkins Hospital Residents) - Ependymoma (1); Clear cell ependymoma (1)
Maryland (National Naval Medical Center) - High grade oligodendrogliomas (5); astroblastoma (2); High grade glioma (1)
Massachusetts (Brigham and Women's Hospital) - Clear cell ependymoma
Massachusetts (New England Medical Center Residents) - Oligodendroglioma
Michigan (Oakwood Hospital) - Dysembryoplastic neuroepithelial tumor
Missouri (Truman Medical Center) - Oligodendroglioma
Nebraska (Creighton University School of Medicine Residents) - Oligodendroglioma, favor anaplastic
Nebraska (University of Nebraska Pathology Residents) - Clear cell ependymoma
New Jersey (Overlook Hospital) - Pilocytic astrocytoma, recurrent (1); Mixed oligodendroglioma, astrocytoma (2)
New York (Cornell Pathology Residents) - Clear cell ependymoma
New York (Impath, Inc) - Neurocytoma (pending reactive synapto)
New York (Nassau University Medical Center) - Oligoastrocytoma, brain
New York (Stony Brook University Hospital Residents) - Anaplastic ependymoma
New York (Westchester Medical Center) - Ependymoma
North Carolina (Wake Forest Residents) - Ependymoma, clear cell type
Pennsylvania (Allegheny General Hospital) - Oligodendroglioma, grade II
Pennsylvania (Conemaugh Memorial Hospital) - Clear cell ependymoma/oligodendroglioma
Puerto Rico (University of Puerto Rico) - Clear cell ependymoma
Texas (Propath Services) - Oligodendroglioma (1); Oligodendroglioma, malignant (1)
Texas (Scott and White Memorial Hospital) - Oligodendroglioma
Washington (University of Washington) - Clear cell ependymoma vs. anaplastic oligodendroglioma
West Virginia (Greenbrier Valley Medical Center) - Cerebral neuroblastoma
Wisconsin (Meriter Health Services) - Anaplastic ependymoma, rule out astroblastoma
Australia (North Queensland Pathology) - Ependymoma

Australia (Royal Prince Alfred Hospital) - Ependymoma, clear cell type
Canada (Foothills Hospital) - Oligodendroglioma
Hong Kong (Hong Kong Baptist Hospital) - Ependymoma
Ireland (St. James Hospital) - Oligodendroglioma
Japan (Shimada City Hospital) - Astroblastoma
Japan (Yamanashi Medical University) - Anaplastic oligodendroglioma (1); Anaplastic ependymoma (1); Central neurocytoma (1); Medulloblastoma (1)

Case 1 - Diagnosis:

Clear cell ependymoma, left temporal lobe
T-X2500, M-93913

Case 1 – References:

Fobes EC, Jr. and Earl KM. Ependymomas. Clinical and Pathological Aspects. *J Neurosurg* 1969; 30(5):585-594.
Maruyama R, Koga K, Nakahara T, et al. Cerebral-Myxopapillary Ependymoma. *Hum Pathol* 1992; 23(8):960-962.
Nagashima T, Hoshino T, et al. The Proliferative Potential of Human Ependymomas Measured by In-situ Bromodeoxyuridine Labeling. *Cancer* 1988; 61(12): 2433-2438.
Min Kw and Scheithauer BW. Clear Cell Ependymoma. A Mimic of Oligodendroglioma. Clincopathologic and Ultrastructural Considerations. *Am J Surg Pathol* 1997; 21(7): 21(7):820-826.

Case No. 2, Accession No. 29357 September 2002

Bakersfield - Meningioma
Baldwin Park (Kaiser Permanente) - Atypical meningioma (1); Fibrous meningioma (1); Meningioma (1)
Bay Area - Atypical meningioma (4)
Daly City (Seton Medical Center) - Metastatic renal cell carcinoma
Fontana (Kaiser Permanente) - Atypical meningioma
Hayward/Fremont - Malignant meningioma
Loma Linda (Loma Linda University Residents) - Atypical meningioma
Long Beach - Meningioma (7)
Monterey (Community Hospital of Monterey Peninsula) - Atypical meningioma vs. astrocytoma
Moreno Valley - Atypical meningioma
Mountain Area - Meningioma (3); Meningioma (hemangioblastic variant) (1)
Mountain View (El Camino Pathology Group) - Anaplastic meningioma
Oakland (Kaiser Permanente) - Meningioma (3)
Orange (Orange County Medical Group) - Meningioma, atypical
Orange (UCI Medical Center Residents) - Meningioma, brain
San Diego (Naval Medical Center) - Atypical meningioma
San Francisco (UCSF Medical Center) - Atypical meningioma
Santa Barbara (Santa Barbara Cottage Hospital) - Anaplastic meningioma
Santa Rosa (Santa Rosa Memorial Hospital) - Atypical meningioma (3)
Ventura (Unilab) - Meningioma (3)
Alaska (Alaska Native Medical Center) - Meningioma (atypical) (1); Meningioma (1)
Arizona (Phoenix Memorial Hospital) - Anaplastic meningioma
Florida (Munroe Regional Medical Center) - Anaplastic meningioma
Florida (Pathology Associates) - Meningioma
Florida (Winter Haven Hospital) - Atypical meningioma
Indiana (Fort Wayne) - Recurrent anaplastic meningioma
Louisiana (Louisiana State University Hospital) - Secretory vs. rhabdoid meningioma
Maryland (Johns Hopkins Hospital Residents) - Atypical meningioma (WHO, grade II) (1); Favor malignant over atypical meningioma (1)
Maryland (National Naval Medical Center) - Meningioma, atypical (10)
Massachusetts (Brigham and Women's Hospital) - Atypical meningioma

Massachusetts (New England Medical Center Residents) - Secretory meningioma
Michigan (Oakwood Hospital) - Atypical meningioma
Missouri (Truman Medical Center) - Meningioma
Nebraska (Creighton University School of Medicine Residents) - Meningioma (meningotheliomatous)
Nebraska (University of Nebraska Pathology Residents) - Meningioma, WHO, grade II
New Jersey (Overlook Hospital) - Atypical meningioma (2); Malignant meningioma (1)
New York (Cornell Pathology Residents) - Meningioma
New York (Impath, Inc) - Meningioma (? secretory)
New York (Nassau University Medical Center) - Atypical meningioma, brain
New York (Stony Brook University Hospital Residents) - Atypical meningioma
New York (Westchester Medical Center) - Atypical meningioma
North Carolina (Wake Forest Residents) - Atypical meningioma
Pennsylvania (Allegheny General Hospital) - Atypical meningioma
Pennsylvania (Conemaugh Memorial Hospital) - Atypical meningioma
Puerto Rico (University of Puerto Rico) - Anaplastic meningioma
Texas (Propath Services) - Meningioma (1); Aggressive meningioma (1)
Texas (Scott and White Memorial Hospital) - Meningioma
Washington (University of Washington) - Malignant meningioma vs. anaplastic astrocytoma (a mixed glioma)
West Virginia (Greenbrier Valley Medical Center) - Cerebral infarct
Wisconsin (Meriter Health Services) - Atypical meningioma, meningiotheliomatous variant
Australia (North Queensland Pathology) - Rhabdoid meningioma, high grade 3
Australia (Royal Prince Alfred Hospital) - Atypical meningioma (WHO II)
Canada (Foothills Hospital) - Atypical meningioma
Hong Kong (Hong Kong Baptist Hospital) - Atypical meningioma
Ireland (St. James Hospital) - Meningioma, transitional
Japan (Shimada City Hospital) - Atypical meningioma
Japan (Yamanashi Medical University) - Malignant meningioma (1); Atypical meningioma (2); Ependymoma (1)

Case 2 - Diagnosis:

Atypical meningioma
T-X2000, M-95300

Consultation: Bernd W. Scheithauer, M.D., Mayo Clinic, Rochester, MI. "Atypical meningioma".

Case 2 - References:

Weisberg S, Ashkenazi E, Israel Z, et al. Anaplastic and Atypical Meningiomas Express High Levels of Fas and Undergo Apoptosis in Response to Fas Ligation. *Am J Pathol* 2001; 159(4):1193-1197.
Amatya VJ, Takeshima Y, Sugiyama K, et al. Immunohistochemical Study of Ki-67 (MIB1), p53 Protein, p21WAF1, and p27KIP1 Expression in Benign, Atypical and Anaplastic Meningiomas. *Hum Pathol* 2001; 32(9):970-975.
Palma L, Celli P, Franco C, et al. Long-Term Prognosis for Atypical and Malignant Meningiomas. A Study of 71 Surgical Cases. J *Neurosurg* 1997; 86(5):793-800.
Perry A, Stafford SL, Scheithauer BW, et al. Meningioma Grading. An Analysis of Histologic Parameters. *Am J Surg Pathol* 1997; 21(12):1455-1465.

Case No. 3, Accession No. 24070 September 2002

Bakersfield - Hemangioblastoma
Baldwin Park (Kaiser Permanente) - Hemangioblastoma (3)
Bay Area - Cerebellar hemangioblastoma (3); Epithelioid hemangioendothelioma (1)
Daly City (Seton Medical Center) - Hemangioblastoma
Fontana (Kaiser Permanente) - Hemangioblastoma
Hayward/Fremont - Hemangioblastoma

Loma Linda (Loma Linda University Residents) - Cerebellar hemangioblastoma
Long Beach - Hemangioblastoma (7)
Monterey (Community Hospital of Monterey Peninsula) - Hemangioblastoma
Moreno Valley - Hemangioblastoma
Mountain Area - Hemangioblastoma (3); Cerebellar hemangioblastoma (1)
Mountain View (El Camino Pathology Group) - Hemangioblastoma
Oakland (Kaiser Permanente) - Hemangioblastoma (3)
Orange (Orange County Medical Group) - Hemangioblastoma
Orange (UCI Medical Center Residents) - Hemangioblastoma, cerebellum
San Diego (Naval Medical Center) - Capillary, hemangioblastoma
San Francisco (UCSF Medical Center) - Capillary hemangioblastoma
Santa Barbara (Santa Barbara Cottage Hospital) - Metastatic renal cell carcinoma
Santa Rosa (Santa Rosa Memorial Hospital) - Hemangioblastoma (2); Cerebellar hemangioblastoma (1)
Ventura (Unilab) - Hemangioblastoma (3)
Alaska (Alaska Native Medical Center) - Hemangioblastoma (2)
Arizona (Phoenix Memorial Hospital) - Hemangioblastoma
Florida (Munroe Regional Medical Center) - Hemangioblastoma
Florida (Pathology Associates) - Hemangioblastoma
Florida (Winter Haven Hospital) - Hemangioblastoma
Indiana (Fort Wayne) - Hemangioblastoma
Louisiana (Louisiana State University Hospital) - Hemangioblastoma
Maryland (Johns Hopkins Hospital Residents) - Cerebellar hemangioblastoma (1); Hemangioblastoma (1)
Maryland (National Naval Medical Center) - Hemangioblastoma (10)
Massachusetts (Brigham and Women's Hospital) - Capillary hemangioblastoma
Massachusetts (New England Medical Center Residents) - Capillary hemangioendothelioma
Michigan (Oakwood Hospital) - Hemangioblastoma
Missouri (Truman Medical Center) - Hemangioblastoma
Nebraska (Creighton University School of Medicine Residents) - Hemangioblastoma
Nebraska (University of Nebraska Pathology Residents) - Hemangioblastoma
New Jersey (Overlook Hospital) - Hemangioblastoma (3)
New York (Cornell Pathology Residents) - Hemangioblastoma
New York (Impath, Inc) - Capillary hemangioblastoma
New York (Nassau University Medical Center) - Hemangioblastoma, cerebellum
New York (Stony Brook University Hospital Residents) - Capillary hemangioblastoma
New York (Westchester Medical Center) - Capillary hemangioblastoma
North Carolina (Wake Forest Residents) - Hemangioblastoma
Pennsylvania (Allegheny General Hospital) - Hemangioblastoma
Pennsylvania (Conemaugh Memorial Hospital) - Hemangioblastoma
Puerto Rico (University of Puerto Rico) - Hemangioblastoma
Texas (Propath Services) - Hemangioblastoma (2)
Texas (Scott and White Memorial Hospital) - Hemangioblastoma
Washington (University of Washington) - Hemangioblastoma vs. clear cell renal carcinoma
West Virginia (Greenbrier Valley Medical Center) - Hemangioblastoma
Wisconsin (Meriter Health Services) - Hemangioblastoma
Australia (North Queensland Pathology) - Hemangioblastoma
Australia (Royal Prince Alfred Hospital) - Capillary hemangioblastoma
Canada (Foothills Hospital) - Hemangioblastoma
Hong Kong (Hong Kong Baptist Hospital) - Hemangioblastoma
Ireland (St. James Hospital) - Hemangioblastoma
Japan (Shimada City Hospital) - Hemangioblastoma
Japan (Yamanashi Medical University) - Hemangioblastoma (4)

Case 3 - Diagnosis:

Hemangioblastoma, cerebellum
T-X6000, M-91611

Case 3 - References:

Commins DL and Hinton DR. Cytologic Features of Hemangioblastoma. Comparison with Meningioma, Anaplastic Astrocytoma and Renal Cell Carcinoma. *Acta Cytol* 1998; 42(5):1104-1110.

Brown DF, Dababo MA, Hladik CL, et al. Hormone Receptor Immunoreactivity in Hemangioblastomas and Clear Cell Renal Cell Carcinomas. *Mod Pathol* 1998; 11(1):55-59.

Tse JY, Wong JH, Lo KW, et al. Molecular Genetic Analysis of the von Hippel-Lindau Disease Tumor Suppressor Gene in Familial and Sporadic Cerebellar Hemangioblastomas. *Am J Clin Pathol* 1997; 107(4):459-466.

Case No. 4, Accession No. 18923 September 2002

Bakersfield - Craniopharyngioma
Baldwin Park (Kaiser Permanente) - Adamatinomatous craniopharyngeal (1); Craniopharyngeal (2)
Bay Area - Craniopharyngioma (4)
Daly City (Seton Medical Center) - Craniopharyngioma
Fontana (Kaiser Permanente) - Craniopharyngioma
Hayward/Fremont - Craniopharyngioma
Loma Linda (Loma Linda University Residents) - Ameloblastic craniopharyngioma
Long Beach - Craniopharyngioma, adamantinomatous type (7)
Monterey (Community Hospital of Monterey Peninsula) - Craniopharyngioma, adamatinomatous type
Moreno Valley - Adamantinomatous craniopharyngioma
Mountain Area - Craniopharyngioma (4)
Mountain View (El Camino Pathology Group) - Craniopharyngioma
Oakland (Kaiser Permanente) - Craniopharyngioma (3)
Orange (Orange County Medical Group) - Craniopharyngioma
Orange (UCI Medical Center Residents) - Craniopharyngioma, base of brain
San Diego (Naval Medical Center) - Adamatinomatous craniopharyngioma
San Francisco (UCSF Medical Center) - Adamantinomatous craniopharyngioma
Santa Barbara (Santa Barbara Cottage Hospital) - Craniopharyngioma
Santa Rosa (Santa Rosa Memorial Hospital) - Craniopharyngioma (3)
Ventura (Unilab) - Craniopharyngioma (3)
Alaska (Alaska Native Medical Center) - Craniopharyngioma (adamantinomatous) (1); Craniopharyngioma (1)
Arizona (Phoenix Memorial Hospital) - Craniopharyngioma, adamantinomatous type
Florida (Munroe Regional Medical Center) - Craniopharyngioma
Florida (Pathology Associates) - Craniopharyngioma
Florida (Winter Haven Hospital) - Craniopharyngioma
Indiana (Fort Wayne) - Craniopharyngioma
Louisiana (Louisiana State University Hospital) - Craniopharyngioma
Maryland (Johns Hopkins Hospital Residents) - Adamantinomatous craniopharyngioma with ossification of wet keratin (1); Adamantinomatous craniopharyngioma (1)
Maryland (National Naval Medical Center) - Craniopharyngioma (10)
Massachusetts (Brigham and Women's Hospital) - Adamantinomatous craniopharyngioma
Massachusetts (New England Medical Center Residents) - Craniopharyngioma
Michigan (Oakwood Hospital) - Craniopharyngioma
Missouri (Truman Medical Center) - Craniopharyngioma
Nebraska (Creighton University School of Medicine Residents) - Craniopharyngioma
Nebraska (University of Nebraska Pathology Residents) - Craniopharyngioma, adamantinomatous
New Jersey (Overlook Hospital) - Craniopharyngioma (3)
New York (Cornell Pathology Residents) - Adamantinomatous craniopharyngioma

New York (Impath, Inc) - Craniopharyngioma (adamantinomatous)
New York (Nassau University Medical Center) - Craniopharyngioma, base of brain
New York (Stony Brook University Hospital Residents) - Craniopharyngioma
New York (Westchester Medical Center) - Adamantinomatous craniopharyngioma
North Carolina (Wake Forest Residents) - Craniopharyngioma
Pennsylvania (Allegheny General Hospital) - Adamantinomatous (craniopharyngioma)
Pennsylvania (Conemaugh Memorial Hospital) - Craniopharyngioma
Puerto Rico (University of Puerto Rico) - Craniopharyngioma
Texas (Propath Services) - Craniopharyngioma (2)
Texas (Scott and White Memorial Hospital) - Craniopharyngioma
Washington (University of Washington) - Craniopharyngioma
West Virginia (Greenbrier Valley Medical Center) - Adamantinomatous craniopharyngioma
Wisconsin (Meriter Health Services) - Craniopharyngioma
Australia (North Queensland Pathology) - Craniopharyngioma
Australia (Royal Prince Alfred Hospital) - Craniopharyngioma
Canada (Foothills Hospital) - Craniopharyngioma, papillary
Hong Kong (Hong Kong Baptist Hospital) - Craniopharyngioma
Ireland (St. James Hospital) - Craniopharyngioma
Japan (Shimada City Hospital) - Adamantinomatous craniopharyngioma
Japan (Yamanashi Medical University) - Craniopharyngioma (4)

Case 4 - Diagnosis:

Craniopharyngioma
T-X2000, M-93501

Case 4 - References:

Ito M, Jamshidi J, and Yamanaka K. Does Craniopharyngioma Metastasize? Case Report and Review of the Literature. *Neurosurg* 2001; 48(4):933-935.

Kristopaitis T, Thomas C, Petruzzelli GJ, et al. Malignant Craniopharyngioma. *Arch Pathol Lab Med* 2000; 124(9):1356-1360.

Paulus W, Stockel C, Krauss J, Sorensen N, et al. Odontogenic Classification of Craniopharyngiomas. A Clinicopathologic Study of 54 Cases. *Histopathol* 1997; 30(2):171-176.

Raghavan R, Dickey WT, Margraf LR, et al. Proliferative Activity in Craniopharyngiomas. Clinicopathological Correlations in Adults and Children. *Surg Neurol*; 54(3):241-247.

Fahlbusch R, Honegger J, Paulus W, et al. Surgical Treatment of Craniopharyngiomas. Experience with 168 Patients. *J Neurosurg* 1999; 90(2):237-250.

Case No. 5, Accession No. 22530 September 2002

Bakersfield - Chordoma
Baldwin Park (Kaiser Permanente) - Chordoma (3)
Bay Area - Chordoma (4)
Daly City (Seton Medical Center) - Myxoid chondrosarcoma
Fontana (Kaiser Permanente) - Chordoma
Hayward/Fremont - Chordoma
Loma Linda (Loma Linda University Residents) - Chordoma
Long Beach - Chordoma (7)
Monterey (Community Hospital of Monterey Peninsula) - Metastatic carcinoma vs. chordoma
Moreno Valley - Chordoma
Mountain Area - Chordoma (4)
Mountain View (El Camino Pathology Group) - Chordoma
Oakland (Kaiser Permanente) - Chordoma (3)
Orange (Orange County Medical Group) - Chordoma
Orange (UCI Medical Center Residents) - Chordoma, spinal cord

San Diego (Naval Medical Center) - Chordoma
San Francisco (UCSF Medical Center) - Chordoma
Santa Barbara (Santa Barbara Cottage Hospital) - Myxopapillary ependymoma
Santa Rosa (Santa Rosa Memorial Hospital) - Chordoma (3)
Ventura (Unilab) - Chordoma (3)
Alaska (Alaska Native Medical Center) - Chordoma (2)
Arizona (Phoenix Memorial Hospital) - Chordoma
Florida (Munroe Regional Medical Center) - Chordoma
Florida (Pathology Associates) - Chordoma
Florida (Winter Haven Hospital) - Chordoma
Indiana (Fort Wayne) - Myxopapillary ependymoma
Louisiana (Louisiana State University Hospital) - Chordoma
Maryland (Johns Hopkins Hospital Residents) - Chordoma
Maryland (National Naval Medical Center) - Chordoma (10)
Massachusetts (Brigham and Women's Hospital) - Chordoma
Massachusetts (New England Medical Center Residents) - Chordoma
Michigan (Oakwood Hospital) - Chordoma
Missouri (Truman Medical Center) - Chordoma
Nebraska (Creighton University School of Medicine Residents) - Chordoma
Nebraska (University of Nebraska Pathology Residents) - Chordoma
New Jersey (Overlook Hospital) - Chordoid meningioma (3)
New York (Cornell Pathology Residents) - Chordoid meningioma
New York (Impath, Inc) - Chordoma
New York (Nassau University Medical Center) - Chordoma, spinal cord
New York (Stony Brook University Hospital Residents) - Chordoid meningioma
New York (Westchester Medical Center) - Chordoid meningioma
North Carolina (Wake Forest Residents) - Chordoma
Pennsylvania (Allegheny General Hospital) - Chordoma
Pennsylvania (Conemaugh Memorial Hospital) - Myxomatous chordoma
Puerto Rico (University of Puerto Rico) - Chordoma
Texas (Propath Services) - Chordoma (2)
Texas (Scott and White Memorial Hospital) - Chordoid meningioma
Washington (University of Washington) - Chordoma
West Virginia (Greenbrier Valley Medical Center) - Microcystic meningioma
Wisconsin (Meriter Health Services) - Chordoma
Australia (North Queensland Pathology) - Chondroid chordoma vs. chordoid meningioma
Australia (Royal Prince Alfred Hospital) - Chordoid meningioma (5); Chordoma (2)
Canada (Foothills Hospital) - Chordoma
Hong Kong (Hong Kong Baptist Hospital) - Clear cell meningioma
Ireland (St. James Hospital) - Chordoma (exclude carcinoma)
Japan (Shimada City Hospital) - Chordoma
Japan (Yamanashi Medical University) - Chordoid meningioma (2); Chordoma (1); Paraganglioma (1)

Case 5 - Diagnosis:

Chordoma, extra-dural, in region of T7
T-X7410, M-93703

Case 5 - References:

Walker WP, Landas SK, Bromley CM and Sturm MT. Immunohistochemical Distinction of Classic and Chondroid Chordomas. *Mod Pathol* 1991; 4(5):661-666.
Crapanzano JP, Ali SZ, Ginsberg MS, et al. Chordoma. A Cytologic Study with Histologic and Radiologic Correlation. *Cancer* 2001; 93(1):40-51.
Haeckel C, Krueger S, Kuester D, et al. Expression of Cathepsin K in Chordoma. *Hum Pathol* 2000; 31(7):834-840.

Bergh P, Kindblom LG, Gunterberg B, et al. Prognostic Factors in Chordoma of the Sacrum and Mobile Spine. A Study of 39 Patients. *Cancer* 2000; 88(9):2122-2134.
Moriki T, Takahashi T, Wada M, et al. Chondroid Chordoma. Fine-Needle Aspiration Cytology with Histopathological, Immunohistochemical, and Ultrastructural Study of Two Cases. *Diagn Cytopathol* 1999; 21(5):335-339.

Case No. 6, Accession No. 13433 September 2002

Bakersfield - Oligodendroglioma
Baldwin Park (Kaiser Permanente) - Oligodendrogioma (3)
Bay Area - Vascular malformation with infarction (3)
Daly City (Seton Medical Center) - Oligodendroglioma
Fontana (Kaiser Permanente) - Arteriovenous malformation (AVM)
Hayward/Fremont - Oligodendroglioma
Loma Linda (Loma Linda University Residents) - Oligodendroglioma, grade II
Long Beach - Oligodendroglioma (7)
Monterey (Community Hospital of Monterey Peninsula) - Dysembryoplastic neuroepithelial tumor
Moreno Valley - Oligodendroglioma
Mountain Area - Oligodendroglioma (4)
Mountain View (El Camino Pathology Group) - Dysembryoplastic neuroepithelial tumor (DNET)
Oakland (Kaiser Permanente) - Oligodendroglioma (3)
Orange (Orange County Medical Group) - Oligodendroglioma
Orange (UCI Medical Center Residents) - Oliodendroglioma, cerebrum
San Diego (Naval Medical Center) - Oligodendroglioma
San Francisco (UCSF Medical Center) - Oligodendroglioma
Santa Barbara (Santa Barbara Cottage Hospital) - Low grade oligodendroglioma
Santa Rosa (Santa Rosa Memorial Hospital) - Oligodendroglioma (3)
Ventura (Unilab) - Pilocytic astroctyoma (2); Oligodendroglioma (1)
Alaska (Alaska Native Medical Center) - Oligodendroglioma (1); Astrocytoma (? pilocytic) (1)
Arizona (Phoenix Memorial Hospital) - Dysembryoplastic neuroepithelial tumor
Florida (Munroe Regional Medical Center) - Oligodendroglioma
Florida (Pathology Associates) - Tuberous sclerosis
Florida (Winter Haven Hospital) - Oligodendroglioma
Indiana (Fort Wayne) - Subependymal giant cell astrocytoma
Louisiana (Louisiana State University Hospital) - Dysembryoplastic neuroepithelial tumor
Maryland (Johns Hopkins Hospital Residents) - Oligodendroglioma (1); Well-differentiated oligodendroglioma (1)
Maryland (National Naval Medical Center) - Pilocytic astrocytoma (10)
Massachusetts (Brigham and Women's Hospital) - Low grade oligodendroglioma vs. dysembryoplatic neuroepithelial tumor
Massachusetts (New England Medical Center Residents) - Oligoastrocytoma
Michigan (Oakwood Hospital) - Oligodendroglioma
Missouri (Truman Medical Center) - Pilocytic astrocytoma
Nebraska (Creighton University School of Medicine Residents) - Oligodendroglioma
Nebraska (University of Nebraska Pathology Residents) - Oligodendroglioma, grade 2
New Jersey (Overlook Hospital) - Oligodendroglioma (3)
New York (Cornell Pathology Residents) - Pilocytic astrocytoma
New York (Impath, Inc) - Oligodendroglioma
New York (Nassau University Medical Center) - Oligodendroglioma, cerebrum
New York (Stony Brook University Hospital Residents) - Low grade oligoastrocytoma
New York (Westchester Medical Center) - Oligodendroglioma
North Carolina (Wake Forest Residents) - Oligodendroglioma
Pennsylvania (Allegheny General Hospital) - Pilocytic astrocytoma
Pennsylvania (Conemaugh Memorial Hospital) - Oligodendroglioma

Puerto Rico (University of Puerto Rico) - Cavernous hemangioma
Texas (Propath Services) - Pilocytic astrocytoma (2)
Texas (Scott and White Memorial Hospital) - Oligodendroglioma
Washington (University of Washington) - Oligodendroglioma, maybe with pilocytic astrocytoma component
West Virginia (Greenbrier Valley Medical Center) - Calcifying pseudoneoplasm
Wisconsin (Meriter Health Services) - Oligodendroglioma
Australia (North Queensland Pathology) - Pilocytic astrocytoma
Australia (Royal Prince Alfred Hospital) - Oligodendroglioma
Canada (Foothills Hospital) - Oligodendroglioma
Hong Kong (Hong Kong Baptist Hospital) - Oligodendroglioma
Ireland (St. James Hospital) - Oligodendroglioma (? composite oligo/astrocytoma)
Japan (Shimada City Hospital) - Oligodendroglioma
Japan (Yamanashi Medical University) - Oligodendroglioma (2); Pilocytic astrocytoma (2)

Case 6 - Diagnosis:

Oligodendroglioma, right cerebrum
T-X2000, M-94503

Case 6 - References:

Smith MT, Ludwig CL, Godfrey AD, et al. Grading of Oligodendrogliomas. *Cancer* 1983; 52(11):2107-2114.
Korshunov A and Golanov A. The Prognostic Significance of DNA Topoisomerase II-Alpha (Ki-S1), p21/Cip-1, p27/Kip-1 Protein Immunoexpression in Oligodendrogliomas. *Arch Pathol Lab Med* 2001; 125(7):892-898.
Watson MA, Perry A, Budhjara V, Hicks C, et al. Gene Expression Profiling with Oligonucleotide Microarrays Distinguishes World Health Organization Grade of Oligodendrogliomas. *Cancer Res* 2001; 61(5):1825-1829.
Allam A, Radwi A, El Weshi A, et al. Oligodendroglioma. An Analysis of Prognostic Factors and Treatment Results. *Am J Clin Oncol* 2000; 23(2):170-175.
Fortin D, Cairncross GJ and Hammond RR. Oligodendroglioma. An Appraisal of Recent Data Pertaining to Diagnosis and Treatment. *Neurosurg* 1999; 45(6):1279-1291.
Min KW and Scheithauer BW. Clear Cell Ependymoma. A Mimic of Oligodendroglioma. Clincopathologic and Ultrastructural Considerations. *Am J Surg Pathol* 1997; 21(7):820-826.

Case No. 7, Accession No. 29591 September 2002

Bakersfield - Schwannoma
Baldwin Park (Kaiser Permanente) - Nerve sheath tumor (3)
Bay Area - Peripheral nerve sheath tumor with perineural features vs. schwannoma with pacinian features (2); Neurofibroma (1)
Daly City (Seton Medical Center) - Solitary fibrous tumor
Fontana (Kaiser Permanente) - Neurofibroma
Hayward/Fremont - Schwannoma
Loma Linda (Loma Linda University Residents) - Solitary fibrous tumor
Long Beach - Schwannoma (7)
Monterey (Community Hospital of Monterey Peninsula) - "Ancient" neurofibroma
Moreno Valley - Neurofibroma with degenerative atypia
Mountain Area - Schwannoma (4)
Mountain View - Neurofibroma with ancient change
Oakland (Kaiser Permanente) - Neurofibroma (3)
Orange (UCI Medical Center Residents) - Schwannoma, right cheek
San Diego (Naval Medical Center) - Ancient schwannoma (10); Malignant peripheral nerve sheath tumor, low grade (1)
San Francisco (UCSF Medical Center) - MPNST
Santa Barbara (Santa Barbara Cottage Hospital) - Ancient schwannoma
Santa Rosa (Santa Rosa Memorial Hospital) - Neurothekeoma (2); Neurofibroma with atypical features (atypical neurofibroma) (1)
Ventura (Unilab) - Schwannoma (2); Dermatofibrosarcoma protuberans (1)
Alaska (Alaska Native Medical Center) - Schwannoma (with ancient change) (1); Neurofibroma (1)
Arizona (Phoenix Memorial Hospital) - Solitary fibrous tumor

Florida (Munroe Regional Medical Center) - Schwannoma
Florida (Pathology Associates) - Neurofibroma
Florida (Winter Haven Hospital) - Schwannoma
Indiana (Fort Wayne) - Low grade MPNST
Louisiana (Louisiana State University Hospital) - Peripheral nerve sheath tumor (? schwannoma)
Maryland (Johns Hopkins Hospital Residents) - Schwannoma with degenerative nuclear atypism (1); Atypical neurofibroma (1)
Maryland (National Naval Medical Center) - Schwannoma (10); Angiofibroma (1)
Massachusetts (Brigham and Women's Hospital) - Schwannoma
Massachusetts (New England Medical Center Residents) - Schwannoma
Michigan (Oakwood Hospital) - Schwannoma
Missouri (Truman Medical Center) - Neurofibroma/schwannoma
Nebraska (Creighton University School of Medicine Residents) - Neurothecoma
Nebraska (University of Nebraska Pathology Residents) - Neurofibroma
New Jersey (Overlook Hospital) - Neurofibroma (2); Degenerated schwannoma (1)
New York (Cornell Pathology Residents) - Neurofibroma
New York (Impath, Inc) - Schwannoma
New York (Nassau University Medical Center) - Ancient schwannoma, cheek
New York (Stony Brook University Hospital Residents) - Ancient schwannoma
New York (Westchester Medical Center) - Schwannoma
North Carolina (Wake Forest Residents) - Schwannoma with ancient changes
Pennsylvania (Allegheny General Hospital) - Neurofibroma
Pennsylvania (Conemaugh Memorial Hospital) - Neurofibroma
Puerto Rico (University of Puerto Rico) - Neurofibroma
Texas (Propath Services) - Neurilemoma (2)
Texas (Scott and White Memorial Hospital) - Schwannoma
Washington (University of Washington) - Schwannoma vs. solitary fibrous tumor vs. sarcoma
West Virginia (Greenbrier Valley Medical Center) - Perineurioma
Wisconsin (Meriter Health Services) - Benign peripheral nerve sheath tumor, favor neurofibroma
Australia (North Queensland Pathology) - Ancient schwannoma
Australia (Royal Prince Alfred Hospital) - Schwannoma (6); Perineurioma (1)
Canada (Foothills Hospital) - Schwannoma
Hong Kong (Hong Kong Baptist Hospital) - Neurofibrosarcoma
Ireland (St. James Hospital) - Schwannoma (? neurofibroma, ? melanoma)
Japan (Shimada City Hospital) - Neurofibroma (intraneural)
Japan (Yamanashi Medical University) - Schwannoma (4)

Case 7 - Diagnosis:

Schwannoma with degenerative changes, cheek
T-Y0300, M-95600

Case 7 - References:

Argenyi ZB, Balogh K and Abraham AA. Degenerative ("Ancient") Changes in Benign Cutaneous Schwannoma. A Light Microscopic, Histochemical and Immunohistochemical Study. *J Cutan Pathol* 1993; 20(2):148-153.
Dodd LG, Marom EM, Dash RC, et al. Fine-Needle Aspiration Cytology of "Ancient" Schwannoma. *Diagn Cytopathol* 1999; 20(5):307-311.
Jayaraj SM, Levine T, Frosh AC, et al. Ancient Schwannoma Masquerading as Parotid Pleomorphic Adenoma. *J Laryngol Otol* 1997; 111(11):1088-1090.

Case No. 8, Accession No. 12988 September 2002

Bakersfield - Gemistocytic astrocytoma
Baldwin Park (Kaiser Permanente) - Gemistocytic astrocytoma, grade 2 (3)

Bay Area - Gemistocytic astrocytoma (3)
Daly City (Seton Medical Center) - Gemistocytic astrocytoma
Fontana (Kaiser Permanente) - Gemistocytic astrocytoma, if multiple sclerosis is ruled out clinically
Hayward/Fremont - Gemistocytic astrocytoma
Loma Linda (Loma Linda University Residents) - Gemistocytic astrocytoma
Long Beach - Gemistocytic astrocytoma (7)
Monterey (Community Hospital of Monterey Peninsula) - Gemistocytic astrocytoma
Moreno Valley - Gemistocytic astrocytoma
Mountain Area - Gemistocytic astrocytoma, grade II/IV (2); Gemistocytic astrocytoma (2)
Mountain View (El Camino Pathology Group) - Gemistocytic astrocytoma
Oakland (Kaiser Permanente) - Gemistocytic astrocytoma (3)
Orange (Orange County Medical Group) - Gemistocytic astrocytoma, grade 2
Orange (UCI Medical Center Residents) - Gemistocytic astrocytoma, cerebrum
San Diego (Naval Medical Center) - Anaplastic astrocytoma, gemistocytic type
San Francisco (UCSF Medical Center) - Gemistocytic astrocytoma
Santa Barbara (Santa Barbara Cottage Hospital) - Gemistocytic astrocytoma
Santa Rosa (Santa Rosa Memorial Hospital) - Astrocytoma (2); Gemistocytic astrocytoma (1)
Ventura (Unilab) - Gemistocytic astrocytoma (2); Astrocytoma, pilocytic ? (1)
Alaska (Alaska Native Medical Center) - Astrocytoma (anaplastic/gemistocytic) (1); Astrocytoma with gemistocytic features (1)
Arizona (Phoenix Memorial Hospital) - Gemistocytic astrocytoma
Florida (Munroe Regional Medical Center) - Gemistocytic astrocytoma
Florida (Pathology Associates) - Ganglion cell tumor
Florida (Winter Haven Hospital) - Gemistocytic astrocytoma
Indiana (Fort Wayne) - Gemistocytic astrocytoma, grade 2
Louisiana (Louisiana State University Hospital) - Differentiated (gemistocytic) astrocytoma
Maryland (Johns Hopkins Hospital Residents) - Gemistocytic astrocytoma (1); Gemistocytic astrocytoma, grade II/IV
Maryland (National Naval Medical Center) - Gemistocytic astrocytoma, grade 2 (10)
Massachusetts (Brigham and Women's Hospital) - Subependymal giant cell astrocytoma
Massachusetts (New England Medical Center Residents) - Low grade astrocytoma
Michigan (Oakwood Hospital) - Gemistocytic astrocytoma
Missouri (Truman Medical Center) - Gemistocytic astrocytoma
Nebraska (Creighton University School of Medicine Residents) - Gemistocytic astrocytoma
Nebraska (University of Nebraska Pathology Residents) - Astrocytoma, gemistocytic, grade 2
New Jersey (Overlook Hospital) - Gemistocytic astrocytoma, grade 2 (3)
New York (Cornell Pathology Residents) - Diffuse astrocytoma, grade 2
New York (Impath, Inc) - Fibrillary astrocytoma (gemistocytic)
New York (Nassau University Medical Center) - Gemistocytic astrocytoma, cerebrum
New York (Stony Brook University Hospital Residents) - Gemistocytic astrocytoma
New York (Westchester Medical Center) - Gemistocytic astrocytoma
North Carolina (Wake Forest Residents) - Gemistocytic astrocytoma
Pennsylvania (Allegheny General Hospital) - Gemistocytic astrocytoma
Pennsylvania (Conemaugh Memorial Hospital) - Gemistocytic astrocytoma
Puerto Rico (University of Puerto Rico) - Gemistocytic astrocytoma
Texas (Propath Services) - Gemistocytic astrocytoma (2)
Texas (Scott and White Memorial Hospital) - Gemistocytic astrocytoma
Washington (University of Washington) - Gemistocytic astrocytoma
West Virginia (Greenbrier Valley Medical Center) - Gemistocytic astrocytoma
Wisconsin (Meriter Health Services) - Gemistocytic astrocytoma
Australia (North Queensland Pathology) - Gemistocytic astrocytoma
Australia (Royal Prince Alfred Hospital) - Gemistocytic astrocytoma
Canada (Foothills Hospital) - Gemistocytic astrocytoma
Hong Kong (Hong Kong Baptist Hospital) - Gemistocytic astrocytoma
Ireland (St. James Hospital) - Astrocytoma, gemistocytic

Japan (Shimada City Hospital) - Gemistocytic astrocytoma
Japan (Yamanashi Medical University) - Anaplastic astrocytoma (grade III) (1); Gemistocytic astrocytoma (3)

Case 8 - Diagnosis:

Gemistocytic astrocytoma, right parietal cerebrum
T-X2000, M-94113

Case 8 – References:

Krouwer HG, Davis RL, Silver P and Prados M. Gemistocytic Astrocytomas. A Reappraisal. *J Neurosurg* 1991; 74(3):399-406.
Watanabe K, Tachibana O, Yonekawa Y, et al. Role of Gemistocytes in Astrocytoma Progression. *Lab Invest* 1997; 76(2):277-284.
Geddes JF, Thom M, Robinson SF, et al. Granular Cell Change in Astrocytic Tumors. *Am J Surg Pathol* 1996; 20(1):55-63.
Kattar MM, Kupsky WJ, Shimoyama RK, et al. Clonal Analysis of Gliomas. *Hum Pathol* 1997; 28(10):1166-1179.

Case No. 9, Accession No. 8693 September 2002

Bakersfield - Medulloblastoma
Baldwin Park (Kaiser Permanente) - Medulloblastoma (3)
Bay Area - Medulloblastoma (2); PNET (cannot exclude a pinealcytoma) (1)
Daly City (Seton Medical Center) - Medulloblastoma
Fontana (Kaiser Permanente) - Medulloblastoma
Hayward/Fremont - Medulloblastoma
Loma Linda (Loma Linda University Residents) - Medulloblastoma/PNET
Long Beach - Medulloblastoma (7)
Monterey (Community Hospital of Monterey Peninsula) - Medulloblastoma
Moreno Valley - Medulloblastoma
Mountain Area - Medulloblastoma (4)
Mountain View (El Camino Pathology Group) - Primitive neuroepithelial tumor (PNET) vs. ependymoblastoma
Oakland (Kaiser Permanente) - Medulloblastoma (3)
Orange (Orange County Medical Group) - Medulloblastoma
Orange (UCI Medical Center Residents) - Medulloblastoma/PNET, brain
San Diego (Naval Medical Center) - Ependymoma
San Francisco (UCSF Medical Center) - Medulloblastoma
Santa Barbara (Santa Barbara Cottage Hospital) - Medulloblastoma
Santa Rosa (Santa Rosa Memorial Hospital) - Medulloblastoma (3)
Ventura (Unilab) - Ependymoma (2); Medulloblastoma (1)
Alaska (Alaska Native Medical Center) - Ependymoma (1); Medulloblastoma (1)
Arizona (Phoenix Memorial Hospital) - Ependymoma
Florida (Munroe Regional Medical Center) - Medulloblastoma
Florida (Pathology Associates) - Ependymoma
Florida (Winter Haven Hospital) - Medulloblastoma
Indiana (Fort Wayne) - Medulloblastoma (PNET)
Louisiana (Louisiana State University Hospital) - Medulloblastoma, Diff diag: ependymoma (1)
Maryland (Johns Hopkins Hospital Residents) - Medulloblastoma (2)
Maryland (National Naval Medical Center) - Medulloblastoma (10)
Massachusetts (Brigham and Women's Hospital) - Atypical teratoid/rhabdoid tumor
Massachusetts (New England Medical Center Residents) - Medulloblastoma
Michigan (Oakwood Hospital) - Medulloblastoma
Missouri (Truman Medical Center) - Medulloblastoma
Nebraska (Creighton University School of Medicine Residents) - Medulloblastoma
Nebraska (University of Nebraska Pathology Residents) - Medulloblastoma
New Jersey (Overlook Hospital) - Ependymoma (2); Medulloblastoma (1)
New York (Cornell Pathology Residents) - Medulloblastoma

New York (Impath, Inc) - Medulloblastoma
New York (Nassau University Medical Center) - Medulloblastoma, brain
New York (Stony Brook University Hospital Residents) - Medulloblastoma
New York (Westchester Medical Center) - Choroid plexus carcinoma
North Carolina (Wake Forest Residents) - Medulloblastoma
Pennsylvania (Allegheny General Hospital) - Medulloblastoma
Pennsylvania (Conemaugh Memorial Hospital) - Cellular ependymoma
Puerto Rico (University of Puerto Rico) - Primitive neuroectodermal tumor, PNET
Texas (Propath Services) - Medulloblastoma (2)
Texas (Scott and White Memorial Hospital) - Ependymoma
Washington (University of Washington) - Desmoplastic medulloblastoma (PNET)
West Virginia (Greenbrier Valley Medical Center) - Ependymoma
Wisconsin (Meriter Health Services) - PNET
Australia (North Queensland Pathology) - PNET ? medulloblastoma
Australia (Royal Prince Alfred Hospital) - Medulloblastoma
Canada (Foothills Hospital) - Medulloblastoma, melanotic
Hong Kong (Hong Kong Baptist Hospital) - Pilocytic astrocytoma
Ireland (St. James Hospital) - Medulloblastoma/PNET
Japan (Shimada City Hospital) - Ependymoma
Japan (Yamanashi Medical University) - Medulloblastoma (2); Ependymoblastoma (1); Ependymoma (1)

Case 9 - Diagnosis:

Medulloblastoma, floor of 4th ventricle
T-32400, M-94703

Case 9 – References:

Roberts RO, Lynch CF, Jones MP and Hart MN. Medulloblastoma. A Population-Based Study of 532 Cases. *J Neuropathol Exp Neurol* 1991; 50(2):134-144.

Goldberg-Stern H, Gadoth N, Stern S, et al. The Prognostic Significance of Glial Fibrillary Acidic Protein Staining in Medulloblastoma. *Cancer* 1991; 68(3):568-573.

Caputy AJ, McCullough DC, Manz HJ, et al. A Review of the Factors Influencing Prognosis of Medulloblastoma. The Importance of Cell Differentiation. *J Neurosurg* 1987; 66(1):80-87.

Badiali M, Pession A, Basso G, et al. N-myc and C-myc Oncogenes Amplification in Medulloblastomas. Evidence of Particularly Aggressive Behavior of a Tumor with C-myc Amplification. *Tumouri* 1991; 77(2):118-121.

Kunschner LJ, Kuttesch J and Hess K. Survival and Recurrence Factors in Adult Medulloblastoma. The M.D. Anderson Cancer Center Experience from 1978 to 1998. *Neuro-Oncol* 2001; 3(3):167-173.

Kumar PV, Hosseinzadeh M and Bedayat GR. Cytologic Findings of Medulloblastoma in Crush Smears. *Acta Cytol* 2001; 45(4):542-546.

Case No. 10, Accession No. 18994 — September 2002

Bakersfield - Glioblastoma and gliosarcoma with epithelial metaplasia
Baldwin Park (Kaiser Permanente) - Glioblastoma multiforme (3); GBM (malignant ependyoma) (1)
Bay Area - Glioblastoma multiforme (3)
Daly City (Seton Medical Center) - Glioblastoma multiforme
Fontana (Kaiser Permanente) - High grade pleomorphic xanthoastrocytoma (glioblastoma multiforme)
Hayward/Fremont - Glioblastoma multiforme
Loma Linda (Loma Linda University Residents) - High grade astrocytoma, grade III vs. glioblastoma
Long Beach - Glioblastoma multiforme (7)
Monterey (Community Hospital of Monterey Peninsula) - Glioblastoma vs. ganglioglioma
Moreno Valley - Glioblastoma multiforme
Mountain Area - Glioblastoma multiforme (3); Glioblastoma (1)
Mountain View (El Camino Pathology Group) - Glioblastoma multiforme with aberrant cytokeratin expression
Oakland (Kaiser Permanente) - Glioblastoma multiforme (3)

Orange (Orange County Medical Group) - Glioblastoma multiforme
Orange (UCI Medical Center Residents) - Pleomorphic xanthomatous astrocytoma, right temporal lobe
San Diego (Naval Medical Center) - Glioblastoma multiforme (10); Pleomorphic xanthoastrocytoma with malignant transformation (1)
San Francisco (UCSF Medical Center) - Pleomorphic xanthoastrocytoma
Santa Barbara (Santa Barbara Cottage Hospital) - Gliosarcoma
Santa Rosa (Santa Rosa Memorial Hospital) - Glioblastoma multiforme (3)
Ventura (Unilab) - Glioblastoma multiforme (2); Glioblastoma (1)
Alaska (Alaska Native Medical Center) - Glioblastoma multiforme (1); Glioblastoma (1)
Arizona (Phoenix Memorial Hospital) - Metastatic carcinoma
Florida (Munroe Regional Medical Center) - Gliosarcoma with epithelial metaplasia
Florida (Pathology Associates) - Glioblastoma
Florida (Winter Haven Hospital) - Glioblastoma
Indiana (Fort Wayne) - High grade glioma
Louisiana (Louisiana State University Hospital) - Pleomorphic xanthoastrocytoma
Maryland (Johns Hopkins Hospital Residents) - Glioblastoma multiforme (WHO, grade IV) (1); Glioblastoma multiforme (1)
Maryland (National Naval Medical Center) - Glioblastoma multiforme (10)
Massachusetts (Brigham and Women's Hospital) - Giant cell GBM
Massachusetts (New England Medical Center Residents) - Glioblastoma multiforme
Michigan (Oakwood Hospital) - Glioblastoma multiforme
Missouri (Truman Medical Center) - Glioblastoma multiforme
Nebraska (Creighton University School of Medicine Residents) - Glioblastoma multiforme
Nebraska (University of Nebraska Pathology Residents) - Glioblastoma multiforme, epithelioid type
New Jersey (Overlook Hospital) - Glioblastoma (3)
New York (Cornell Pathology Residents) - PXA with glioblastoma
New York (Impath, Inc) - Glioblastoma multiforme
New York (Nassau University Medical Center) - Glioblastoma, right temporal lobe
New York (Stony Brook University Hospital Residents) - Giant cell glioblastoma
New York (Westchester Medical Center) - Gliosarcoma
North Carolina (Wake Forest Residents) - Glioblastoma multiforme
Pennsylvania (Allegheny General Hospital) - Glioblastoma multiforme
Pennsylvania (Conemaugh Memorial Hospital) - PXA (pleomorphic xanthomatous astrocytoma)
Puerto Rico (University of Puerto Rico) - Anaplastic pleomorphic xantoastrocytoma
Texas (Propath Services) - Glioblastoma multiforme (2)
Texas (Scott and White Memorial Hospital) - Metastatic carcinoma
Washington (University of Washington) - Glioblastoma, maybe with sarcoma component
West Virginia (Greenbrier Valley Medical Center) - Glioblastoma multiforme
Wisconsin (Meriter Health Services) - Gliosarcoma
Australia (North Queensland Pathology) - Glioblastoma multiforme
Australia (Royal Prince Alfred Hospital) - GBM
Canada (Foothills Hospital) - Atypical teratoid rhabdoid tumor
Hong Kong (Hong Kong Baptist Hospital) - Glioblastoma multiforme
Ireland (St. James Hospital) - Glioblastoma multiforme
Japan (Shimada City Hospital) - Gliosarcoma
Japan (Yamanashi Medical University) - Glioblastoma multiforme (3); Pleomorphic xanthoastrocytoma (1)

Case 10 - Diagnosis:

Grade 4 fibrillary astrocytoma ("glioblastoma") with epithelial metaplasia, right temporal lobe
T-X2500, M-94003

Consultation: Bernd W. Scheithauer, M.D., Mayo Clinic, Rochester, MI. "Grade 4 fibrillary astrocytoma with epithelial metaplasia."

Case 10 - References:

Fisher PG, Breiter SN, Carson BS, et al. A Clinicopathologic Reappraisal of Brain Stem Tumor Classification. Identification of Pilocystic Astrocytoma and Fibrillary Astrocytoma as Distinct Entities. *Cancer* 2000; 89(7):1569-1576.

Salmon I, Kiss R, Dewitte O, et al. Histopathologic Grading and DNA Ploidy in Relation to Survival Among 206 Adult Astrocytic Tumor Patients. *Cancer* 1992; 70(2):538-546.

von Deimling A, Eibl RH, Ohgaki H, et al. p53 Mutations are Associated with 17p Allelic Loss in Grade II and Grade III Astrocytoma. *Cancer Res* 1992; 52(10):2987-2990.