1148

CALIFORNIA
TUMOR TISSUE REGISTRY

"ULTRASTRUCTURAL PATHOLOGY"

Study Cases, Subscription A

November 2000

Editor's Note: We hope you enjoy this slight departure from the usual format of the CTTR monthly slide series. While the use of ultrastructure as a diagnostic aid is waning, its importance is still considerable. The intent of this particular study set is to correlate the ultrastructural features of the cases with the characteristic histologic findings. This month's set was put together by former Loma Linda Pathology Resident Dr. Dennis O'Malley. His commentary on the electron micrographs will appear in the "Minutes." ... DRC

California Tumor Tissue Registry
c/o: Department of Pathology and Human Anatomy
Loma Linda University School of Medicine
11021 Campus Avenue, AH 335
Loma Linda, California 92350
(909) 558-4788
FAX: (909) 558-0188
E-mail: cttr@linkline.com
Web Page: www.cttr.org

Target audience:

Practicing pathologists and pathology residents.

Goal:

To acquaint the participant with the histologic features of a variety of benign and malignant neoplasms and tumor-like conditions.

Objectives:

The participant will be able to recognize morphologic features of a variety of benign and malignant neoplasms and tumor-like conditions and relate those processes to pertinent references in the medical literature.

Educational methods and media:

Review of representative glass slides with associated histories.
Feedback on consensus diagnoses from participating pathologists.
Listing of selected references from the medical literature.

Principal faculty:

Weldon K. Bullock, MD
Donald R. Chase, MD

CME Credit:

Loma Linda University School of Medicine designates this continuing medical education activity for up to 2 hours of Category I of the Physician's Recognition Award of the American Medical Association.
CME credit is offered for the subscription year only.

Accreditation:

Loma Linda University School of Medicine is accredited by the Accreditation Council for Continuing Medical Education (ACCME) to sponsor continuing medical education for physicians.

Contributor: G. Phillip Mansur, M.D.
Merced, CA

Case No. 1 - November 2000

Tissue from: Lung

Accession #24978

Clinical Abstract:

While being evaluated for minor injuries in a motor vehicle accident, this 75-year-old male was found to have a large solitary peripheral mass in the left lung. He smoked up to 1 to 1 1/2 packs of cigarettes a day and was a retired welder, mechanic and shipyard worker. He had a history of carcinoma of the bladder, resected 12 years earlier. A left lobectomy was performed.

Gross Pathology:

The 280 gram lobe of lung had a 6 cm diameter bare surface with central cavity, apparently corresponding to an accompanying 55 gram aggregate of white fleshy tumor fragments.

SPECIAL STUDIES:

Cytokeratin	positive
EMA	positive
CEA	negative
CD15	negative

Contributor: Robert T. Dalzell, M.D.
La Mesa, CA

Case No. 2 - November 2000

Tissue from: Right testis

Accession #24553

Clinical Abstract:

After two weeks of left groin pain and swelling, this 72-year-old Caucasian male underwent bilateral inguinal hernia repair and bilateral orchiectomy.

Gross Pathology:

The 90 gram right testis contained a 5.0 cm diameter yellow-tan lobular mass with focal hemorrhage.

Contributor: James P. Kaye, M.D.
Riverside, CA

Case No. 3 - November 2000

Tissue from: Right axilla

Accession #24377

Clinical Abstract:

About 1 year earlier, this 55-year-old female brought to the attention of her family physician a lump in her right axilla. Over the year of observation, the mass grew slowly larger. Her breasts had no palpable masses and mammograms were negative. An axillary dissection was performed.

Gross Pathology:

Most of the 46 resected lymph nodes, ranging from 2 to 4 cm in greatest diameter, contained firm tan tumor with apparent focal hemorrhage.

SPECIAL STUDIES (Outside facility):

Fontana-Masson positive

Contributor: Mark Janssen, M.D.
Loma Linda, CA

Case No. 4 - November 2000

Tissue from: Pancreas

Accession #24421

Clinical Abstract:

This 54-year-old Caucasian male experienced jaundice and slight RUQ abdominal tenderness with dark urine and fatty stools. Ultrasound revealed an echogenic mass in the head of the pancreas with obstruction of the common bile duct.

Gross Pathology:

Included in the resected portion of the pancreas was 3 x 2.5 x 2 cm firm, white to pale yellow mass with foci of hemorrhagic necrosis.

Contributor: Arthur L. Koehler, M.D.
Pasadena, CA

Case No. 5 - November 2000

Tissue from: Right wrist

Accession #27363

Clinical Abstract:

This 81-year-old Caucasian female had noted a large cystic mass in the volar aspect of her right wrist for about a year. The mass was hard and almost immovable.

Gross Pathology:

The 4.5 x 3.0 cm oval mass was firm and non-encapsulated.

Contributor: Mark Janssen, M.D.
Loma Linda, CA

Case No. 6 - November 2000

Tissue from: Thyroid

Accession #24121

Clinical Abstract:

Over a period of a year, this 35-year-old Hispanic male experienced a 35 pound weight loss and a gradually enlarging neck mass. A 2 cm diameter mass was palpable in right lower lobe of his thyroid, along with a 6 cm supraclavicular mass and 3 cm right cervical mass. He also had multiple small submucosal nodules, later found to be neurofibromas. Family history a papillary thyroid carcinoma diagnosed 2 years earlier in his father. A thyroidectomy with right radical neck dissection was performed.

Gross Pathology:

The 7.5 gram right lobe of thyroid contained a 3.5 x 2.0 x 2.0 cm light tan nodule.

SPECIAL STUDIES:

CAM 5.2	4+
Chromogranin	3+
NSE	4+
Calcitonin	1+

Contributor: Mark J. DeMeo, M.D.
Santa Rosa, CA

Case No. 7 - November 2000

Tissue from: Kidney

Accession #27670

Clinical Abstract:

For six months, this 61-year-old Caucasian male had been experiencing difficulty voiding. Sonography disclosed a solid mass near the pole of the right kidney. A right radical nephrectomy was performed.

Gross Pathology:

The 500 gram resection specimen included the right kidney with a 4.0 cm brown-tan bosselated mass in its upper pole.

Contributor: E. M. Courier, M.D.
Fullerton, CA

Case No. 8 - November 2000

Tissue from: Left thigh

Accession #18888

Clinical Abstract:

Following a one-year history of a mass in her left thigh, this 69-year-old Caucasian female underwent a resection of the anterior portion of her rectus femoris muscle. A radiograph had revealed that the mass did not involve adjacent bone.

Gross Pathology:

The encapsulated 10.0 x 7.0 x 6.0 cm fusiform tumor had a variegated yellow-tan cut surface.

Contributor: Mark Janssen, M.D.
Anaheim, CA

Case No. 9 - November 2000

Tissue from: Lung

Accession #28311

Clinical Abstract:

After suffering a fall, this 70-year-old female presented with chest pain. She had a 90-pack-year history of smoking. Chest x-ray and CT scan revealed a mass in the right upper lobe. A right upper lobectomy was performed.

Gross Pathology:

The 16.0 x 13.0 x 4.0 cm lobe of lung had a 2.5 cm diameter white, firm gray mass with ill-defined borders, extending to but not involving, the pleural surface.

Contributor: W. M. Talbert, M.D.
Long Beach, CA

Case No. 10 - November 2000

Tissue from: Left lung

Accession #27244

Clinical Abstract:

When she developed a low grade fever, progressive fatigue, and weight loss, this 4-year-old Brazilian girl was treated for pneumonia. Breath sounds were markedly diminished on the left. Chest x-ray showed 'white-out' of the left lung field. Symptoms persisted and further work-up led to a left pneumonectomy.

Gross Pathology:

The 1660 gram, 25.0 x 19.0 x 8.0 cm left lung was almost completely replaced by a focally necrotic tumor with a fish-flesh cut surface.

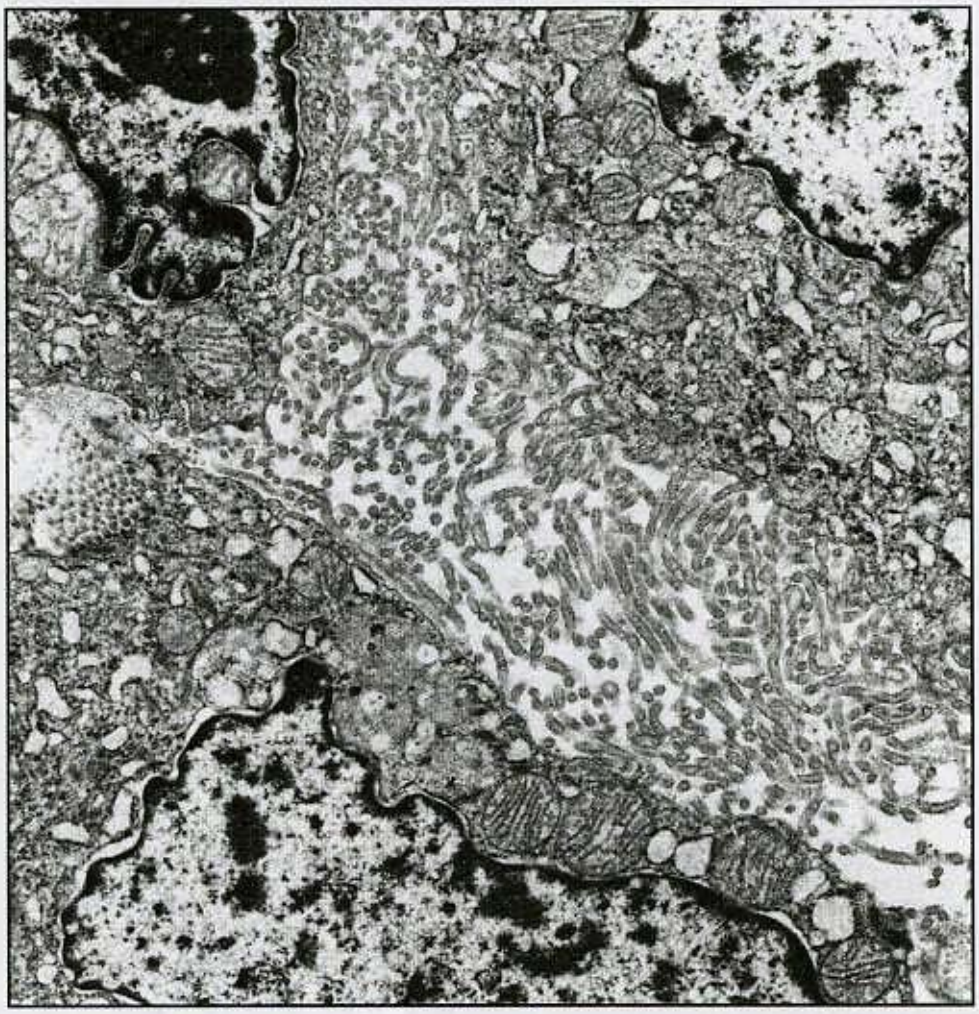

Case1

Case 2

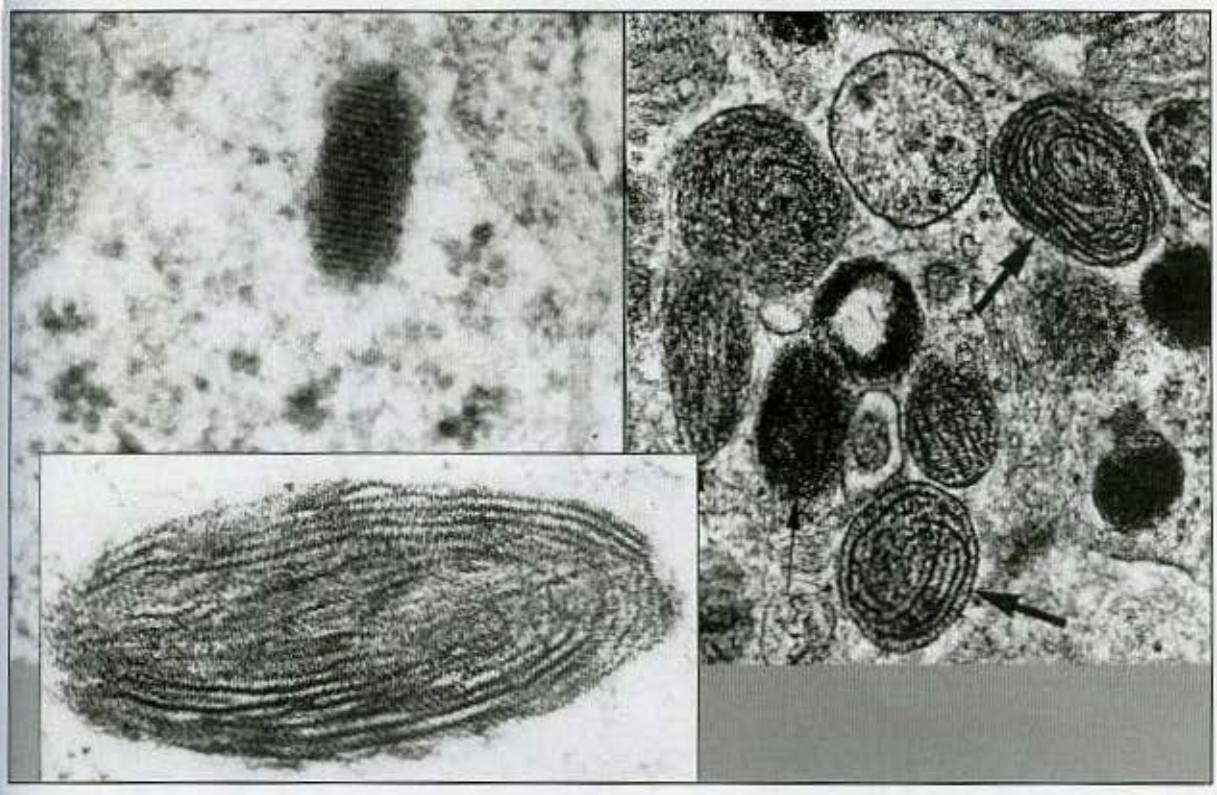

Case 3

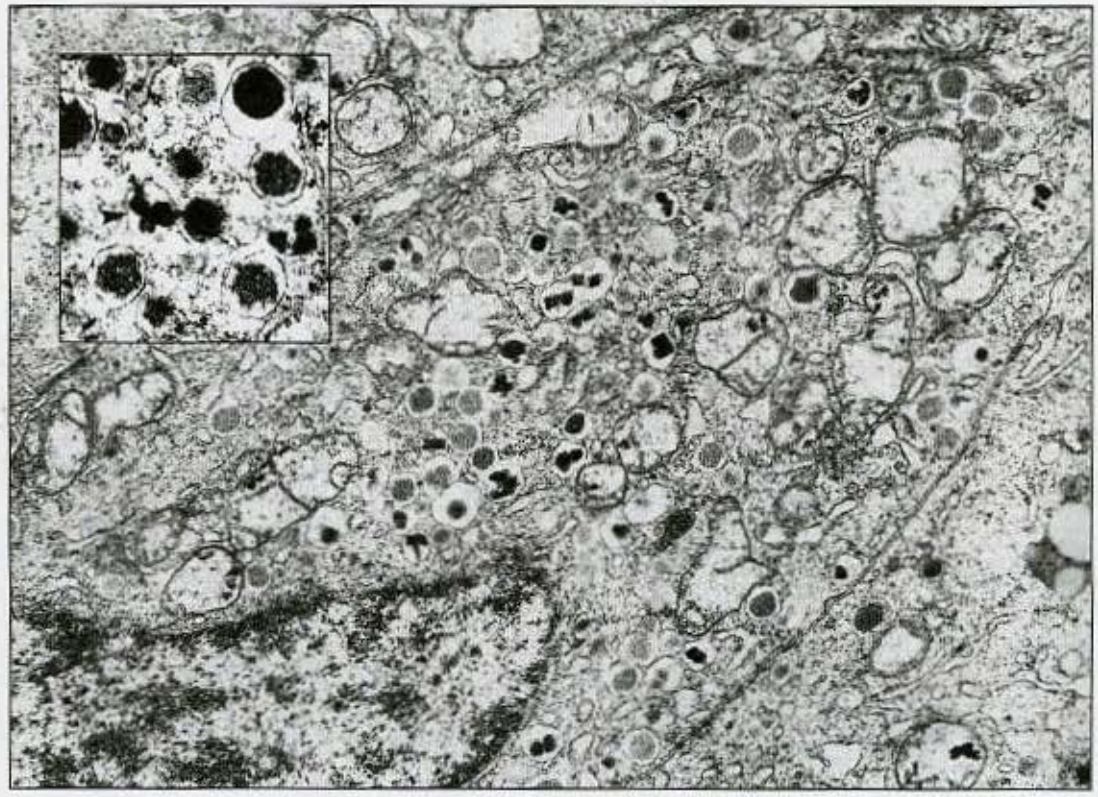

Case 4

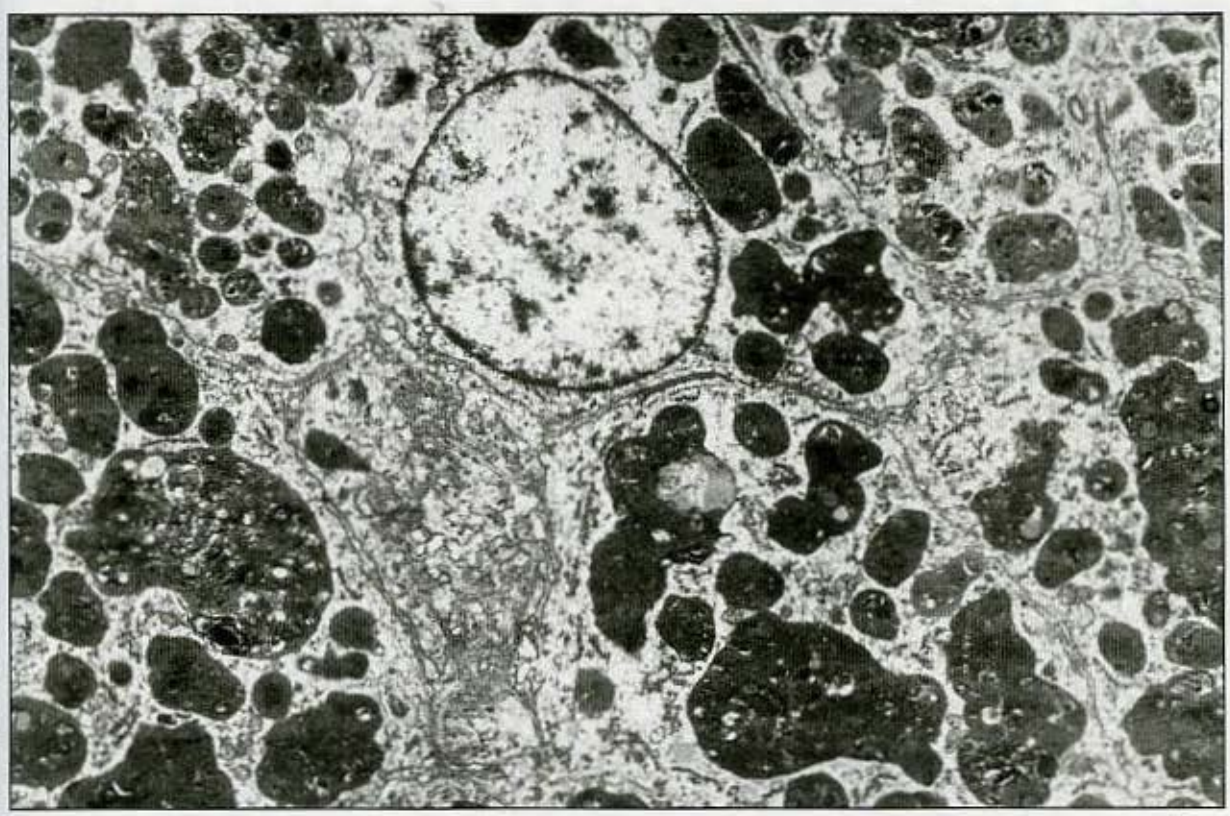

Case 5

Case 6

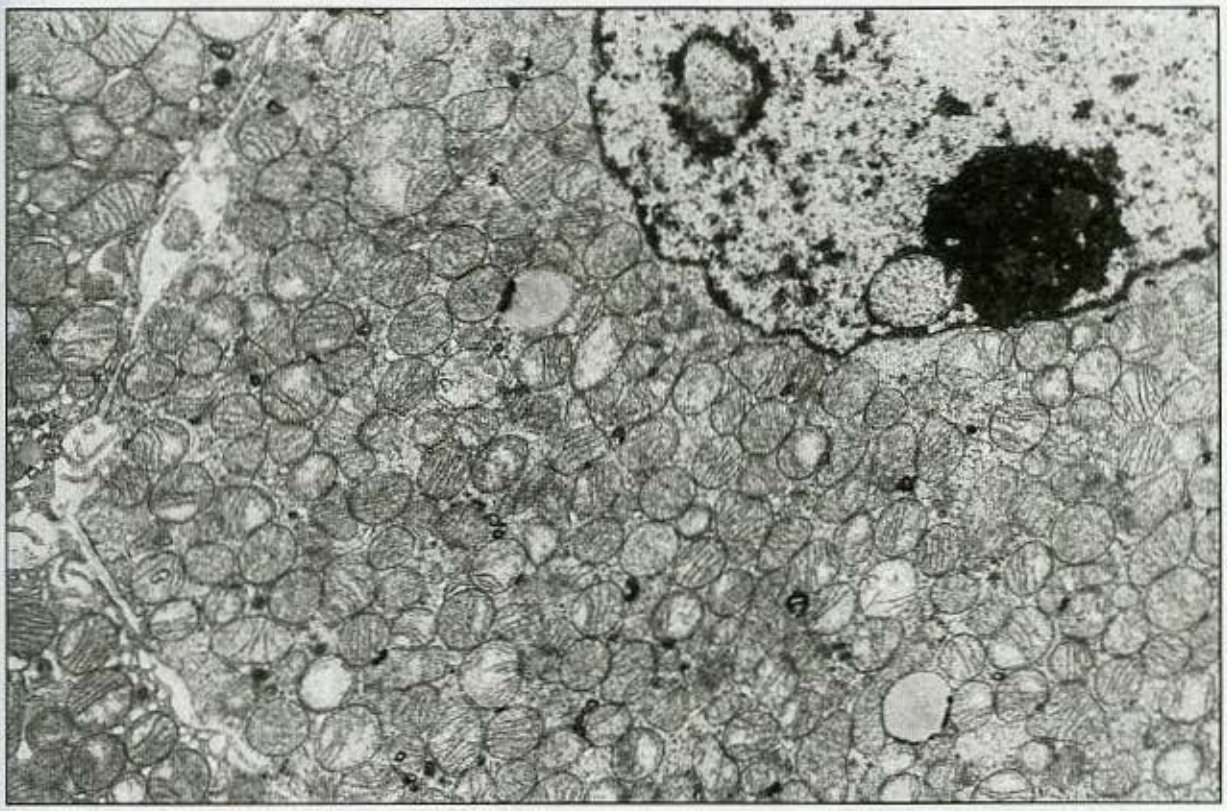

Case 7

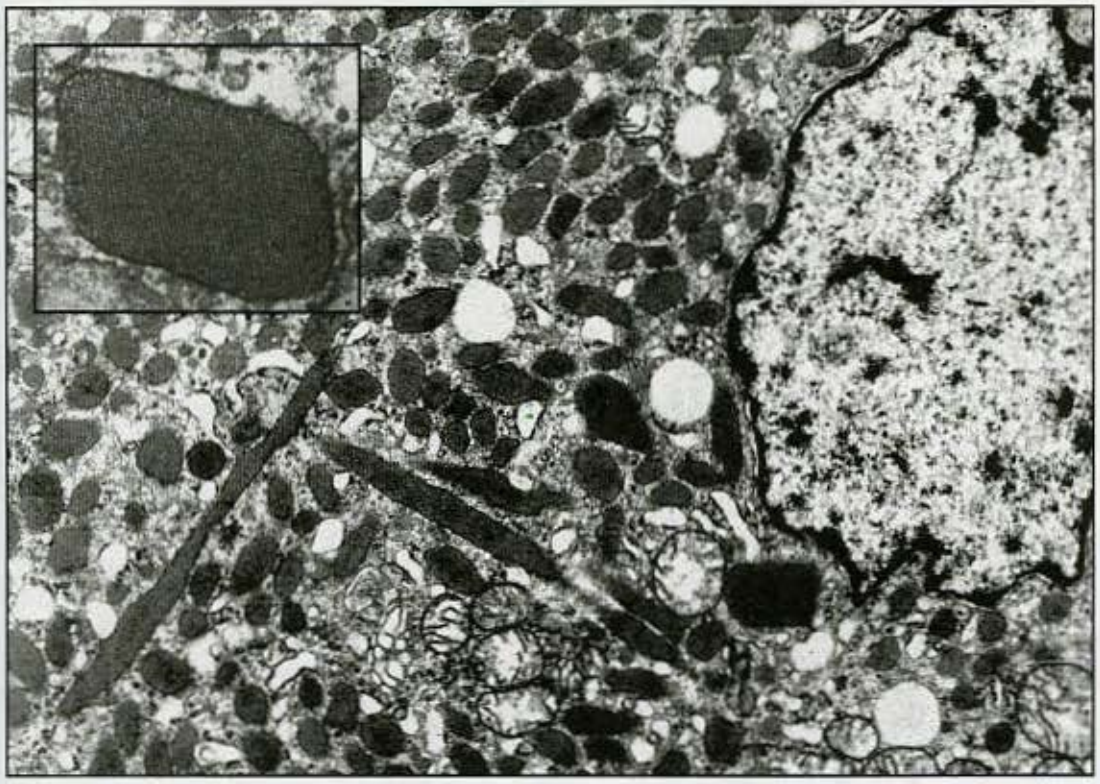

Case 8

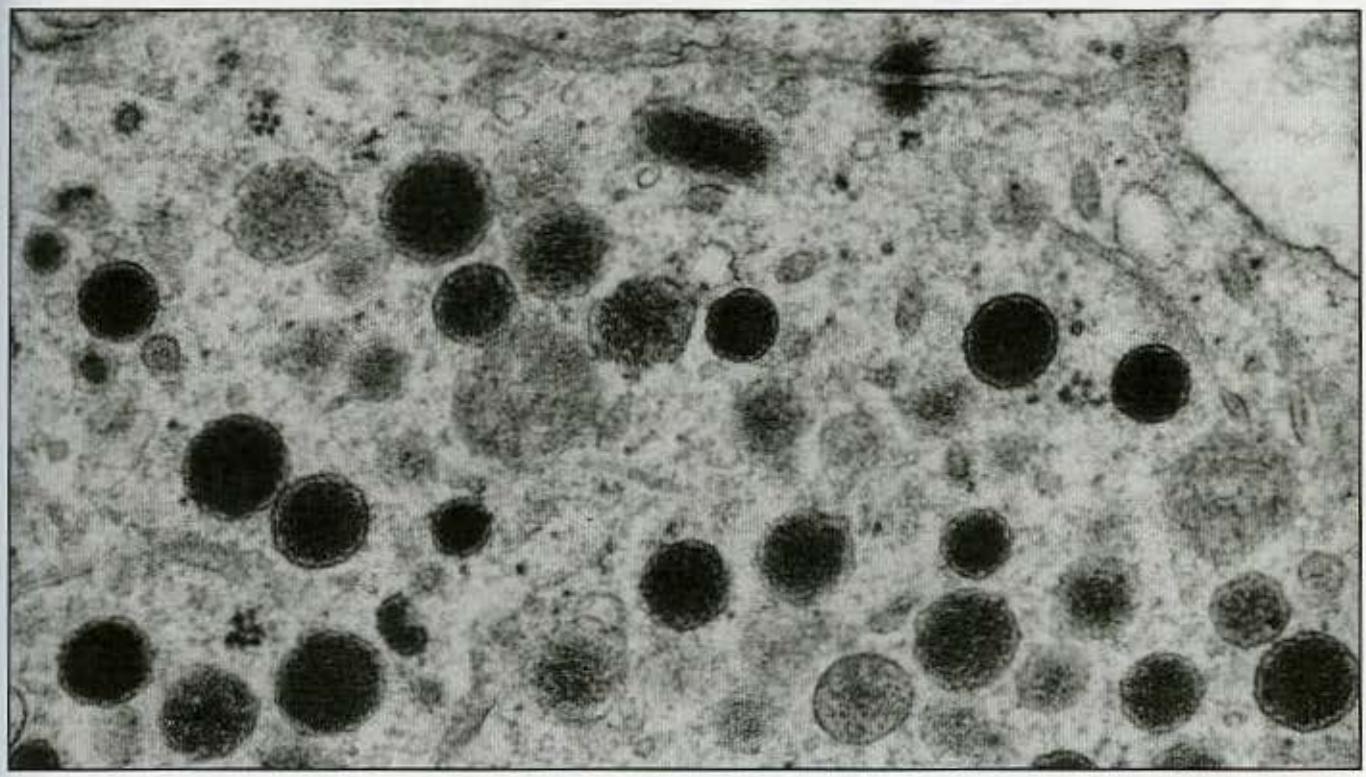

Case 9

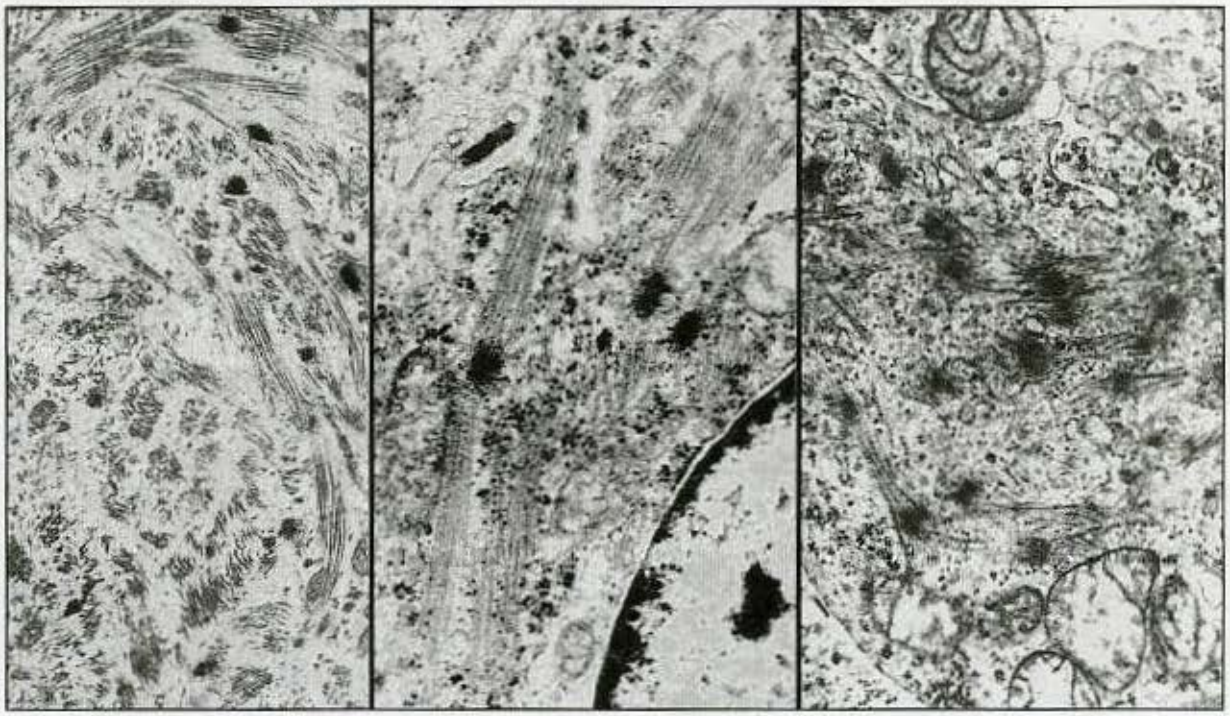

Case 10

CALIFORNIA TUMOR TISSUE REGISTRY

ULTRASTRUCTURAL PATHOLOGY

Minutes – Subscription A

November 2000

SUGGESTED READING (General Topics from Recent Literature):

Metastasizing Fibrous Histiocytoma of the Skin. A Clinicopathologic and Immunohistochemical Analysis of Three Cases. Guillou L and Gebhard S. *Mod Pathol* 2000; 13:654-660.

The Location and Frequency of Intestinal Metaplasia at the Esophagogastric Junction in 223 Consecutive Autopsies. Implication for Patient Treatment and Preventive Strategies in Barrett's Esophagus. Ormsby AH and Kilgore SP *Mod Pathol* 2000; 13:614-620.

Indeterminate Fibrohistiocytic Lesions of the Skin. Is There a Spectrum Between Dermatofibroma and Dermatofibrosarcoma Protuberans? Horenstein MG, Prieto VG, et al. *Am J Surg Pathol* 2000; 24:996-1003.

Lymphovascular Invasion as a Predictor of Disease Progression in Prostate Cancer. Herman CM, Wilcox GE, et al. *Am J Surg Pathol* 2000; 24:859-863.

Electron Microscopy in Tumor Diagnosis. Indications for Its Use in the Immunohistochemical Era. Ordonez NG and Mackay B. *Hum Pathol* 1998; 29(12):1403-1411.

California Tumor Tissue Registry
c/o: Department of Pathology and Human Anatomy
Loma Linda University School of Medicine
11021 Campus Avenue, AH 335
Loma Linda, California 92350
(909) 558-4788
FAX: (909) 558-0188
E-mail: cttr@linkline.com
Case of the Month: www.llu.edu/llu/cttr/cotm
Web Page: www.cttr.org

File Diagnoses

Editor's Note: We hope you enjoyed this slight departure from the usual format of the CTTR monthly slide series. While the use of ultrastructure as a diagnostic aid is waning, its importance is still considerable. The intent of this slide set is to serve as a reminder of the correlation of ultrastructural features with the characteristic histologic findings. Residents might also like to review this material for their boards.

The commentary is given by Dr. Dennis O'Malley, currently a hematopathology fellow at Duke University. Dennis recently graduated from the residency program at Loma Linda, and has been a Co-Director of the CTTR's web-based Case of the Month (cttr.org, or www.llu.edu/llu/cttr/cotm). ....*DRC*

Case No. 1 **Accession No. 24978**

Diagnosis: **Malignant mesothelioma, lung**
T-28000, M-90503

Commentary: Mesothelioma is still considered to be a difficult diagnosis, especially when it is poorly differentiated. Its distinction from adenocarcinoma can be difficult. Recent developments in immunohistochemical stains have made this difficult task easier, but ultrastructure can still help. The key feature for ultrastructural differentiation is the density, length and branching of the microvilli. Classically, mesothelioma has numerous, long slender microvilli, with dichotomous branching. These characters are not seen in adenocarcinoma.

Case No. 2 **Accession No. 24553**

Diagnosis: **Leydig cell tumor, testis**
T-78000, M-86503

Consultation: (AFIP) "Malignant Leydig cell tumor."
Commentary: This tumor falls into the category of steroid-secreting neoplasms. The Reinke's crystalloids in a normal Leydig cell are also present in a Leydig cell tumor, and are an ultrastructural hallmark of the tumor. In longitudinal section (pictured here), the crystals usually present as long rod-like structures. In transverse section, they have a polygonal shape, with each side of the crystal being parallel to the corresponding opposite side.

Case No. 3 **Accession No. 24377**

Diagnosis: **Metastatic melanoma, axilla**
T-Y8100, M-87203

Commentary: Melanin production is a characteristic of the melanocyte and this function is best defined by the presence of premelanosomes. These organelles are the only truly diagnostic ultrastructural feature of melanoma. (A caveat, other non-melanoma entities such as angiomyolipoma, sugar tumor, etc. may also contain premelanosomes). The premelanosome is characterized by an internal, lattice-like structure which is seen before the organelle becomes fully pigmented. As the melanosome matures, through well-defined stages, the melanin pigment obscures the internal structure. Melanin pigment may be present in cells through phagocytosis (melanophages) and these pockets of melanin may masquerade as more advanced stages of melanosomes.

Case No. 4 **Accession No. 24421**

Diagnosis: **Pancreatic neuroendocrine tumor (islet cell tumor)**
T-59000, M-81500

Consultation: (AFIP) "Islet cell tumor, pancreas."
Commentary: This is a neuroendocrine-derived tumor that is subject to some histologic variability. The ultrastructure is characterized by the presence of neurosecretory granules, in this case filled with pancreatic hormones. By ultrastructure, it is possible to determine if the granules contain insulin versus other types of pancreatic hormones (glucagon, etc.). The insulin granules have a membrane coat with a central 'popcorn' or angulated crystal appearance. Other hormones are often homogeneous and electron dense.

Case No. 5 **Accession No. 27363**

Diagnosis: **Granular cell tumor, wrist**
T-Y8600, M-86201

Commentary: This tumor falls into the general category of the 'large pink cell tumors', whose differential is perhaps not so well defined as its counterpart the 'small blue cell tumors.' Granular cell tumor has a very characteristic ultrastructural appearance, which directly correlates to its light microscopic appearance. The cells are packed with numerous secondary lysosomes. These lysosomes impart the granular pink character to the cytoplasm. The histogenesis of these tumors has been clearly resolved: they are of Schwann cell origin.

Case No. 6 **Accession No. 24121**

Diagnosis: **Medullary carcinoma, thyroid**
T-96000, M-85103

Commentary: It is known that endocrine-derived tumors have a marked propensity for varied and sometime bizarre appearances. Medullary thyroid carcinoma is certainly no exception. Its histologic appearance can vary widely and its pleomorphism can lead to wild speculation about possible diagnoses. To parallel the immunohistochemical presence of calcitonin are the presence of neurosecretory granules. The presence of these granules in a tumor of thyroid origin is proof of its neuroendocrine nature and hence the diagnosis of medullary carcinoma of the thyroid. If there is amyloid in the histologic sections, its ultrastructural appearance can also be confirmed by the classic 'pick-up-sticks' appearance of the fibrils. Further, true to its name, it is a carcinoma and has well-developed cell junctions.

Case No. 7 **Accession No. 27670**

Diagnosis: **Oncocytoma, kidney**
T-71000, M-82900

Commentary: The pink, granular light microscopic appearance of these cells is quite distinctive. The ultrastructure is also quite characteristic. The cytoplasm of the cells is virtually always packed with mitochondria. The mitochondria may be normal in appearance, but can be bizarre or misshapen. It is unclear what their functional capacity is.

Case No. 8 **Accession No. 18888**

Diagnosis: **Alveolar soft part sarcoma, thigh**
T-Y9100, M-95813

Commentary: An unusual tumor of unknown origin. Theories of the derivation for alveolar soft part sarcoma abound. These also fall into the category of the large pink cell tumors. There is little that is memorable about predilection for age or location. As such they may be part of the differential for many tumors. By light microscopy, the characteristic cytoplasmic crystals can be sparse or inapparent. PAS stains will accentuate their appearance and they are diastase resistant. Electron microscopy will often find crystals that are not apparent or visible by light microscopy.

Case No. 9 **Accession No. 28311**

Diagnosis: **Small cell carcinoma, lung**
T-28000, M-80413

Consultation: (Mayo Clinic) "Resection of right upper lobe mass showing features of small cell carcinoma."
Commentary: Yet another neuroendocrine carcinoma, with the characteristic neurosecretory granules. In fact, chromogranin, a commonly used immunostain for neuroendocrine differentiation, actually stains a component of the neurosecretory granules. Again, because it is a carcinoma, cell junctions are also present.

Case No. 10 **Accession No. 27244**

Diagnosis: **Rhabdomyosarcoma with pleomorphic features ("pleomorphic rhabdomyosarcoma")**
T-28000, M-89003

Commentary: The histologic variability of rhabdomyosarcoma can make this a difficult diagnosis. Its histologic appearance can be classic, with pink cells with cross striated fibers, or it can present as a small blue cell tumor. As such, the findings of muscle spindle differentiation on electron microscopy can make the diagnosis straightforward.

STUDY GROUP DIAGNOSES and REFERENCES

Case No. 1, Accession No. 24978 **November 2000**

LLUMC Pathology Residents - Malignant mesothelioma
Mountain View (El Camino Pathology Group) - Malignant mesothelioma
Riverside - Transitional cell carcinoma, metastatic
Bakersfield - Fibrous mesothelioma
Orange - Malignant mesothelioma (sarcomatoid type)
Ventura (Unilab) - Mesothelioma (2)
Oakland (Kaiser) - Mesothelioma (4)
Long Beach - Malignant mesothelioma (long microvilli) (9)
Bay Area - Malignant mesothelioma (3)
Monterey -Mesothelioma
Santa Rosa - Mesothelioma
San Diego - Biphasic malignant mesothelioma
Santa Barbara - Mesothelioma
Monterey Park - Malignant fibrous mesothelioma
Haywood/Fremont - Mesothelioma with long microvilli (3)
Nevada (Western Pathology Consultants) - Mesothelioma
Nebraska (Creighton University) - Mesothelioma
Kansas (Coffeyville Regional Medical Center) - Sarcomatoid carcinoma (by light) vs. mesothelioma (by EM)
Kansas (University of Kansas Medical Center) - Mesothelioma (16)
Indiana (Fort Wayne) - Sarcomatoid carcinoma, left lung
Louisiana (Louisiana State University Medical Center) - Mesothelioma, sarcomatous
Wisconsin (Meriter Hospital) - Malignant mesothelioma, biphasic type, r/o metastatic tumor if solitary mass
Illinois (Dupage Pathology Associates) - Solitary fibrous tumor of pleura-malignant (AKA localized malignant mesothelioma-spindle cell type) (1); Fibrous mesothelioma (1)
Michigan (Oakwood Hospital) - Mesothelioma
Michigan (St Joseph Mercy Hospital) - Spindle cell (metaplastic) squamous carcinoma
Kentucky (University of Louisville Residents) - Spindle cell mixed mesothelioma
Florida (Tallahassee) - Malignant spindled cell mesothelioma
Florida (Munroe Regional Medical Center) - Sarcomatoid mesothelioma
Florida (Winter Haven) - Mesothelioma (3)
North Carolina (Wake Forest University) - Malignant mesothelioma
Pennsylvania (Conemaugh Medical Center Residents) - Mesothelioma
Pennsylvania (Lehigh Valley Hospital) - Spindle cell carcinoma (2); Malignant mesothelioma (1)
Maryland (Woodbine) - Mesothelioma (2)
Maryland (National Naval Medical Ctr) - Mesothelioma
Maryland (University of Maryland) - Malignant mesothelioma
New Jersey (Overlook Hospital) - Malignant mesothelioma, epithelial type (4)
Massachusetts (New England Medical Center) - Malignant mesothelioma
Connecticut (University of Connecticut Health Center) - Malignant mesothelioma
New York (Beth Israel Medical Center Residents) - Malignant mesothelioma
New York (Northport) - Mesothelioma
New York (New Hyde Park) - Mesothelioma
Alaska (Anchorage) - Malignant sarcomatous mesothelioma
Canada (Foothills Hospital) - Sarcomatoid carcinoma
Portugal - Sarcomatoid malignant mesothelioma
Japan (Kyoto) - Malignant mesothelioma (3); Spindle cell carcinoma (1)
Japan , Kurashiki (Kawasaki Medical School) - Malignant mesothelioma (4)
Singapore - Mesothelioma
Saudi Arabia (King Khalid University Hospital) - Mesothelioma

References:

Koss M, Travis W, Moran C, et al. Pseudomesotheliomatous Adenocarcinoma. A Reappraisal. *Sem Diagn Pathol* 1992; 9(2):117-123.

Brown RW, Clark GM, Tandon AK, et al. Multiple-Marker Immunohistochemical Phenotypes Distinguishing Malignant Pleural Mesothelioma from Pulmonary Adenocarcinoma. *Hum Pathol* 1993; 24(4):347-354.

Comin CE, de Klerk NH and Henderson DW. Malignant Mesothelioma. Current Conundrums Over Risk Estimates and Whither Electron Microscopy for Diagnosis? *Ultrastruct Pathol* 1997; 21(4):315-320.

Oury TD, Hammar SP and Roggli VL. Ultrastructural Features of Diffuse Malignant Mesotheliomas. *Hum Pathol* 1998; 29 (12):1382-1392.

LLUMC Pathology Residents - Leydig cell tumor
Mountain View (El Camino Pathology Group) - Leydig cell tumor
Riverside - Histiocytoma?
Bakersfield - Leydig cell tumor
Orange - Leydig cell tumor
Ventura (Unilab) - Leydig cell tumor (2)
Oakland (Kaiser) - Leydig cell tumor (4)
Long Beach - Leydig cell tumor (Reinke's crystals) (9)
Bay Area - Leydig cell tumor (3)
Monterey - Leydig cell tumor
Santa Rosa - Leydig cell tumor (Reinke crystalloids) (1); Leydig cell tumor (1)
San Diego - Leydig cell tumor
Santa Barbara - Leydig cell tumor
Monterey Park - Leydig cell tumor
Haywood/Fremont - Leydig cell tumor with Reinke crystalloids (3)
Nevada (Western Pathology Consultants) - Leydig cell tumor
Nebraska (Creighton University) - Leydig cell tumor
Kansas (Coffeyville Regional Medical Center) - Interstitial cell (Leydig) tumor (by light) with Reinke crystals (by EM)
Kansas (University of Kansas Medical Center) - Leydig cell tumor (16)
Indiana (Fort Wayne) - Leydig cell tumor, right testis
Louisiana (Louisiana State University Medical Center) - Leydig cell tumor
Wisconsin (Meriter Hospital) - Leydig cell tumor
Illinois (Dupage Pathology Associates) - Leydig cell tumor (N.B. Reinke crystals on EM), testis (1); Leydig cell tumor (1)
Michigan (Oakwood Hospital) - Leydig cell tumor
Michigan (St Joseph Mercy Hospital) - Leydig cell tumor
Kentucky (University of Louisville Residents) - Leydig cell tumor
Florida (Tallahassee) - Leydig cell tumor
Florida (Munroe Regional Medical Center) - Leydig cell tumor
Florida (Winter Haven) - Leydig cell tumor (2); Sertoli cell tumor (1)
North Carolina (Wake Forest University) - Leydig cell tumor
Pennsylvania (Conemaugh Medical Center Residents) - Leydig cell tumor
Pennsylvania (Lehigh Valley Hospital) - Leydig cell tumor (3)
Maryland (Woodbine) - Leydig cell tumor (1); Malignant Leydig cell tumor (1)
Maryland (National Naval Medical Ctr) - Leydig cell tumor
Maryland (University of Maryland) - Leydig cell tumor
New Jersey (Overlook Hospital) - Leydig cell tumor (4)
Massachusetts (New England Medical Center) - Leydig cell tumor
Connecticut (University of Connecticut Health Center) - Leydig cell tumor with atypia
New York (Beth Israel Medical Center Residents) - Leydig cell tumor
New York (Northport) - Leydig cell tumor
New York (New Hyde Park) - Leydig cell tumor
Alaska (Anchorage) - Leydig cell tumor
Canada (Foothills Hospital) - Leydig cell tumor
Portugal - Leydig cell tumor (probably benign)
Japan (Kyoto) - Leydig cell tumor (4)
Japan , Kurashiki (Kawasaki Medical School) - Leydig cell tumor (4)
Singapore - Leydig cell tumor
Saudi Arabia (King Khalid University Hospital) - Leydig cell tumor

References:

Bertram KA, Bratloff B, Hodges GF, et al. Treatment of Malignant Leydig Cell Tumor. *Cancer* 1991; 68(10):2324-2329.

Cheville JC, Sebo TJ, Lager DJ, et al. Leydig Cell Tumor of the Testis. A Clinicopathologic, DNA Content and MIB-1 Comparison of Nonmetastasizing and Metastasizing Tumors. *Am J Surg Pathol* 1998; 22(11):1361-1367.

Assi A, Sironi M, et al. Leydig Cell Tumor of the Testis. A Cytohistological, Immunohistochemical, and Ultrastructural Case Study. *Diagn Cytopathol* 1997; 16(3):262-266.

Billings SD, Roth LM and Ulbright TM. Microcystic Leydig Cell Tumors Mimicking Yolk Sac Tumor. A Report of Four Cases. *Am J Surg Pathol* 1999; 23(5):546-551.

LLUMC Pathology Residents - Melanoma
Mountain View (El Camino Pathology Group) - Metastatic melanoma with sarcomatoid features
Riverside - Melanoma, metastatic
Bakersfield - Melanoma
Orange - Malignant melanoma
Ventura (Unilab) - Metastatic melanoma (2)
Oakland (Kaiser) - Melanoma (4)
Long Beach -Metastatic malignant melanoma (melanosomes) (9)
Bay Area - Malignant melanoma (3)
Monterey - Metastatic melanoma
Santa Rosa - Melanoma (melanosomes)
San Diego - Metastatic melanoma
Santa Barbara - Metastatic melanoma
Monterey Park - Medullary carcinoma
Haywood/Fremont - Metastatic melanoma with melanosomes (3)
Nevada (Western Pathology Consultants) - Metastatic melanoma
Nebraska (Creighton University) - Metastatic melanoma
Kansas (Coffeyville Regional Medical Center) - Malignant melanoma (by light) with melanosomes (by EM)
Kansas (University of Kansas Medical Center) - Melanoma (16)
Indiana (Fort Wayne) - Metastatic malignant melanoma, right axilla
Louisiana (Louisiana State University Medical Center) - Malignant melanoma
Wisconsin (Meriter Hospital) - Metastatic melanoma
Illinois (Dupage Pathology Associates) - Metastatic malignant melanoma (NB stage II aberrant melanosomes on EM) (1); Malignant melanoma (mets) (1)
Michigan (Oakwood Hospital) - Metastatic melanoma
Michigan (St Joseph Mercy Hospital) - Metastatic melanoma
Kentucky (University of Louisville Residents) - Melanoma
Florida (Tallahassee) - Melanoma
Florida (Munroe Regional Medical Center) - Metastatic melanoma
Florida (Winter Haven) - Metastatic melanoma (3)
North Carolina (Wake Forest University) - Metastatic malignant melanoma
Pennsylvania (Conemaugh Medical Center Residents) - Malignant melanoma
Pennsylvania (Lehigh Valley Hospital) - Metastatic malignant melanoma (2); Melanoma (1)
Maryland (Woodbine) - Melanoma (2)
Maryland (National Naval Medical Ctr) - Melanoma
Maryland (University of Maryland) - Metastatic melanoma
New Jersey (Overlook Hospital) - Metastatic melanoma (4)
Massachusetts (New England Medical Center) - Malignant melanoma
Connecticut (University of Connecticut Health Center) - Metastatic malignant melanoma
New York (Beth Israel Medical Center Residents) - Melanoma
New York (Northport) - Melanoma
New York (New Hyde Park) - Melanoma
Alaska (Anchorage) - Metastatic malignant melanoma
Canada (Foothills Hospital) - Metastatic melanoma
Portugal - Malignant melanoma, metastatic
Japan (Kyoto) - Malignant melanoma (3); Large cell carcinoma (1)
Japan , Kurashiki (Kawasaki Medical School) - Malignant melanoma (4)
Singapore - Metastatic melanoma
Saudi Arabia (King Khalid University Hospital) - Amelanotic melanoma, metastatic

References:

Norman J, Cruse CW, Espinosa C, et al. Redefinition of Cutaneous Lymphatic Drainage with the Use of Lymphoscintigraphy for Malignant Melanoma. *Am J Surg* 1991; 162(5):432-437.
Heller R, King B, Baekey P, et al. Identification of Submicroscopic Lymph Node Metastases in Patients with Malignant Melanoma. *Semin Surg Oncology* 1993; 9(3):285-289.
Hochwald SN and Coit DG. Role of Elective Lymph Node Dissection in Melanoma. *Semin Surg Oncol* 1998; 14(4):276-282.
Nakhleh RE, Wick MR, Rocamora A, Swanson PE, et al. Morphologic Diversity in Malignant Melanomas. *Am J Clin Pathol* 1990; 93(6):731-740.

LLUMC Pathology Residents - Pancreatic neuroendocrine tumor (islet cell tumor)
Mountain View (El Camino Pathology Group) - Islet cell tumor
Riverside - Islet cell tumor
Bakersfield - Islet cell tumor
Orange - Insulinoma
Ventura (Unilab) - Acinar cell carcinoma (2)
Oakland (Kaiser) - Islet cell tumor (4)
Long Beach - Neuroendocrine carcinoma (neurosecretory granules) (9)
Bay Area - Islet cell tumor (? insulinoma) (3)
Monterey - Islet cell tumor
Santa Rosa - Islet cell tumor (secretory vesicles) (1); Islet cell tumor, alpha cell type (1)
San Diego - Insulinoma
Santa Barbara - Pancreatic endocrine neoplasm (insulinoma)
Monterey Park - Malignant tumor , ? melanoma
Haywood/Fremont - Pancreatic endocrine carcinoma with secretory granules (2); Medullary carcinoma with secretory granules (1)
Nevada (Western Pathology Consultants) - Pancreatic endocrine tumor
Nebraska (Creighton University) - Non-functional islet cell tumor
Kansas (Coffeyville Regional Medical Center) - Islet cell tumor (by light; by EM: granules with crystalline cores, insulinoma?)
Kansas (University of Kansas Medical Center) - Insulinoma (16)
Indiana (Fort Wayne) - Oncocytic islet cell carcinoma (neuroendocrine CA), head of pancreas
Louisiana (Louisiana State University Medical Center) - Beta cell tumor
Wisconsin (Meriter Hospital) - Pancreatic neuroendocrine neoplasm
Illinois (Dupage Pathology Associates) - Pancreas-neuroendocrine carcinoma (1); Islet cell tumor (1)
Michigan (Oakwood Hospital) - Pancreatic endocrine tumor
Michigan (St Joseph Mercy Hospital) - Neuroendocrine carcinoma
Kentucky (University of Louisville Residents) - Insulinoma
Florida (Tallahassee) - Neuroendocrine carcinoma
Florida (Munroe Regional Medical Center) - Islet cell tumor
Florida (Winter Haven) - Pancreatic neuroendocrine carcinoma (3)
North Carolina (Wake Forest University) - Acinar cell carcinoma
Pennsylvania (Conemaugh Medical Center Residents) - Islet cell tumor (insulinoma)
Pennsylvania (Lehigh Valley Hospital) - Neuroendocrine carcinoma (2); Islet cell tumor (1)
Maryland (Woodbine) - Insulinoma (2)
Maryland (National Naval Medical Ctr) - Islet cell tumor (insulinoma)
Maryland (University of Maryland) - Islet cell tumor
New Jersey (Overlook Hospital) - Islet cell tumor (4)
Massachusetts (New England Medical Center) - Islet cell tumor of the pancreas
Connecticut (University of Connecticut Health Center) - Beta cell carcinoma, possibly of a component of acinic cell carcinoma
New York (Beth Israel Medical Center Residents) - Pancreatic acinar cell carcinoma
New York (Northport) - Insulinoma
New York (New Hyde Park) - Insulinoma
Alaska (Anchorage) - Insulinoma (islet cell tumor-beta cell type)
Canada (Foothills Hospital) - Islet cell tumor, insulinoma
Portugal - Insulinoma
Japan (Kyoto) - Islet cell tumor (3); Endocrine tumor (insulinoma) with uncertain malignant potential (1)
Japan , Kurashiki (Kawasaki Medical School) - Acinar cell carcinoma (3); Islet cell tumor (1)
Singapore - Pancreatic endocrine tumor
Saudi Arabia (King Khalid University Hospital) - Islet cell tumor

References:

Kruseman PC, Knijnenburg G, del la Riviere GB, et al. Morphology and Immunohistochemically-Defined Endocrine Function of Pancreatic Islet cell Tumors. *Histopathology* 1978; 2(6):389-399.

Erlandsen SL, Hegre OD, Parsons JA, et al. Pancreatic Islet Cell Hormones. Distribution of Cell Types in the Islet and Evidence for the Presence of Somatostatin and Gastrin in the D Cell. *J Histochem Cytochem* 1976; 24:883-897.

Mangham DC and Isaacson PG. A Novel Immunohistochemical Detection System Using Mirror Image Complementary Antibodies (MICA). *Histopathol* 1999; 35(2):129-133.

Case No. 5, Accession No. 27363 **November 2000**

LLUMC Pathology Residents - Granular cell tumor
Mountain View (El Camino Pathology Group) - Granular cell tumor
Riverside - Granular cell tumor
Bakersfield - Granular cell tumor
Orange - Granular cell tumor
Ventura (Unilab) - Granular cell tumor (2)
Oakland (Kaiser) - Granular cell tumor (4)
Long Beach - Granular cell tumor (lysosome) (9)
Bay Area - Granular cell tumor (3)
Monterey - Granular cell tumor
Santa Rosa - Granular cell tumor (dense bodies)
San Diego - Granular cell tumor
Santa Barbara - Granular cell tumor
Monterey Park - Granular cell tumor
Haywood/Fremont - Granular cell tumor with lysosomes (3)
Nevada (Western Pathology Consultants) - Granular cell tumor
Nebraska (Creighton University) - Granular cell tumor
Kansas (Coffeyville Regional Medical Center) - Granular cell tumor (by light) with lysosomes (by EM)
Kansas (University of Kansas Medical Center) - Granular cell tumor (8); PVNS (8)
Indiana (Fort Wayne) - Granular cell tumor, right wrist
Louisiana (Louisiana State University Medical Center) - Granular cell tumor
Wisconsin (Meriter Hospital) - Granular cell tumor
Illinois (Dupage Pathology Associates) - Granular cell tumor (NB secondary lysosomes on EM) (1); Granular cell tumor (1)
Michigan (Oakwood Hospital) - Granular schwannoma
Michigan (St Joseph Mercy Hospital) - Granular cell tumor
Kentucky (University of Louisville Residents) - Granular cell tumor
Florida (Tallahassee) - Granular cell tumor
Florida (Munroe Regional Medical Center) - Granular cell tumor
Florida (Winter Haven) - Granular cell tumor (3)
North Carolina (Wake Forest University) - Granular cell tumor
Pennsylvania (Conemaugh Medical Center Residents) - Granular cell tumor
Pennsylvania (Lehigh Valley Hospital) - Granular cell tumor (3)
Maryland (Woodbine) - Granular cell tumor (2)
Maryland (National Naval Medical Ctr) - Granular cell tumor
Maryland (University of Maryland) - Granular cell tumor
New Jersey (Overlook Hospital) - Granular cell tumor (4)
Massachusetts (New England Medical Center) - Granular cell tumor
Connecticut (University of Connecticut Health Center) - Granular cell tumor
New York (Beth Israel Medical Center Residents) - Granular cell tumor
New York (Northport) - Granular cell tumor
New York (New Hyde Park) - Granular cell tumor
Alaska (Anchorage) - Granular cell tumor
Canada (Foothills Hospital) - Granular cell tumor
Portugal - Granular cell tumor
Japan (Kyoto) - Granular cell tumor (4)
Japan , Kurashiki (Kawasaki Medical School) - Granular cell tumor (4)
Singapore - Granular cell tumor
Saudi Arabia (King Khalid University Hospital) - Granular cell tumor

References:

Apisarnthanaray P. Granular Cell Tumor. An Analysis of 16 Cases and Review of the Literature. *J Am Acad Dermatopathol* 1981; 5(2):171-182.

Khansur T, Balducci L and Tavassoli M. Identification of Desmosomes in the Granular Cell Tumor. Implications in Histologic Diagnosis and Histogenesis. *Am J Surg Pathol* 1985; 9(12): 898-904.

Bhawan J, Malholra R and Naik DR. Gaucher-Like Cells in a Granular Cell Tumor. *Hum Pathol* 1983; 14(8):730-733.

LeBoit PE, Barr RJ, Burall S, et al. Primitive Polyploid Granular-Cell Tumor and Other Cutaneous Granular-Cell Neoplasms of Apparent Non Neural Origin. *Am J Surg Pathol* 1991; 15(1):48-58.

Kurtin PJ and Bonin DM. Immunohistochemical Demonstration of the Lysosome-Associated Glycoprotein CD68 (KP-1) in Granular Cell Tumors and Schwannomas. *Hum Pathol* 1994; 25(11):1172-1178.

LLUMC Pathology Residents - Medullary carcinoma, thyroid
Mountain View (El Camino Pathology Group) - Medullary carcinoma
Riverside - Medullary carcinoma
Bakersfield - Medullary carcinoma
Orange - Medullary carcinoma
Ventura (Unilab) - Medullary carcinoma (2)
Oakland (Kaiser) - Medullary carcinoma (4)
Long Beach - Medullary carcinoma (neurosecretory granules) (9)
Bay Area - Medullary carcinoma of the thyroid (3)
Monterey - Carcinoma with glandular and neuroendocrine features
Santa Rosa - Medullary carcinoma (consistent with) (2)
San Diego - Medullary thyroid carcinoma
Santa Barbara - Medullary carcinoma
Monterey Park - Medullary carcinoma
Haywood/Fremont - Small cell variant of medullary carcinoma with type II granules (dense core) (3)
Nevada (Western Pathology Consultants) - Metastatic medullary carcinoma
Nebraska (Creighton University) - Medullary carcinoma of thyroid
Kansas (Coffeyville Regional Medical Center) - Medullary carcinoma (by light), neurosecretory granules (by EM)
Kansas (University of Kansas Medical Center) - Medullary carcinoma of the thyroid (16)
Indiana (Fort Wayne) - Medullary carcinoma, right lobe of thyroid
Louisiana (Louisiana State University Medical Center) - Medullary carcinoma
Wisconsin (Meriter Hospital) - Medullary carcinoma
Illinois (Dupage Pathology Associates) - Medullary carcinoma, thyroid (2)
Michigan (Oakwood Hospital) - Medullary thyroid carcinoma, small cell type
Michigan (St Joseph Mercy Hospital) - Medullary carcinoma
Kentucky (University of Louisville Residents) - Medullary thyroid carcinoma
Florida (Tallahassee) - Medullary carcinoma
Florida (Munroe Regional Medical Center) - Medullary carcinoma
Florida (Winter Haven) - Medullary carcinoma (3)
North Carolina (Wake Forest University) - Medullary carcinoma
Pennsylvania (Conemaugh Medical Center Residents) - Medullary carcinoma, thyroid
Pennsylvania (Lehigh Valley Hospital) - Medullary carcinoma of thyroid (3)
Maryland (Woodbine) - Medullary carcinoma, M.E.N 2b (2)
Maryland (National Naval Medical Ctr) - Medullary carcinoma
Maryland (University of Maryland) - Medullary carcinoma of thyroid
New Jersey (Overlook Hospital) - Medullary thryoid carcinoma (4)
Massachusetts (New England Medical Center) - Insular carcinoma
Connecticut (University of Connecticut Health Center) - Medullary thyroid carcinoma
New York (Beth Israel Medical Center Residents) - Medullary carcinoma
New York (Northport) - Medullary carcinoma
New York (New Hyde Park) - Medullary carcinoma
Alaska (Anchorage) - Medullary carcinoma of thyroid
Canada (Foothills Hospital) - Medullary carcinoma, thyroid
Portugal - Medullary carcinoma of the thyroid, in a context of M.E.N 2b
Japan (Kyoto) - Medullary carcinoma of thyroid (4)
Japan , Kurashiki (Kawasaki Medical School) - Medullary carcinoma (4)
Singapore - Medullary carcinoma
Saudi Arabia (King Khalid University Hospital) - Medullary carcinoma

References:

Saad MF, Ordonez NG, Rashid RK, et al. Medullary Carcinoma of the Thyroid. A Study of the Clinical Features and Prognostic Factors in 161 Patients. *Medicine* (Baltimore) 1984; 63(6):319-342.

Bergholm U, Adami HO, Bergstrom R, et al. Clinical Characteristics in Sporadic and Familial Medullary Thyroid Carcinoma. A Nationwide Study of 249 Patients in Sweden from 1959 through 1981. *Cancer* 1989;63(6):1196-1204.

DeLellis RA and Balogh K. Histochemical Characteristics of Parafollicular Cells and Medullary Thyroid Carcinoma. *Am J Surg Pathol* 1973; 72(1):119-128.

Albores-Saavedra J, LiVolvi VA, et al. Medullary Carcinoma. *Seminars in Diagnostic Pathology* 1985; 2(2):137-146.

Harach HR and Williams ED. Glandular (Tubular and Follicular) Variants of Medullary Carcinoma of the Thyroid. *Histopathol* 1983; 7(1):83-97.

LLUMC Pathology Residents - Oncocytoma, kidney
Mountain View (El Camino Pathology Group) - Oncocytoma
Riverside - Oncocytoma
Bakersfield - Oncocytoma
Orange - Oncocytoma
Ventura (Unilab) - Oncocytoma (2)
Oakland (Kaiser) - Oncocytoma (4)
Long Beach - Oncocytoma (mitochondria) (9)
Bay Area - Oncocytoma (3)
Monterey - Oncocytoma
Santa Rosa - Oncocytoma (mitochondria)
San Diego - Oncocytoma
Santa Barbara - Oncocytoma
Monterey Park - Oncocytoma
Haywood/Fremont - Oncocytoma with fat mitochondria (3)
Nevada (Western Pathology Consultants) - Oncocytoma
Nebraska (Creighton University) - Oncocytoma
Kansas (Coffeyville Regional Medical Center) - Oncocytoma (by light), mitochondria (by EM)
Kansas (University of Kansas Medical Center) - Oncocytoma (16)
Indiana (Fort Wayne) - Oncocytoma, right kidney
Louisiana (Louisiana State University Medical Center) - Oncocytoma
Wisconsin (Meriter Hospital) - Oncocytoma
Illinois (Dupage Pathology Associates) - Renal oncocytoma (2)
Michigan (Oakwood Hospital) - Oncocytoma
Michigan (St Joseph Mercy Hospital) - Oncocytoma
Kentucky (University of Louisville Residents) - Oncocytoma
Florida (Tallahassee) - Oncocytoma
Florida (Munroe Regional Medical Center) - Oncocytoma
Florida (Winter Haven) - Oncocytoma (3)
North Carolina (Wake Forest University) - Oncocytoma
Pennsylvania (Conemaugh Medical Center Residents) - Oncocytoma, kidney
Pennsylvania (Lehigh Valley Hospital) - Renal oncocytoma (3)
Maryland (Woodbine) - Oncocytoma (2)
Maryland (National Naval Medical Ctr) - Oncocytic renal neoplasm
Maryland (University of Maryland) - Oncocytoma
New Jersey (Overlook Hospital) - Oncocytoma (4)
Massachusetts (New England Medical Center) - Renal cell carcinoma
Connecticut (University of Connecticut Health Center) - Oncocytoma
New York (Beth Israel Medical Center Residents) - Oncocytoma
New York (Northport) - Oncocytoma
New York (New Hyde Park) - Oncocytoma
Alaska (Anchorage) - Renal oncocytoma
Canada (Foothills Hospital) - Renal oncocytoma
Portugal - Renal oncocytoma
Japan (Kyoto) - Renal oncocytoma (4)
Japan , Kurashiki (Kawasaki Medical School) - Oncocytoma (4)
Singapore - Renal oncocytoma
Saudi Arabia (King Khalid University Hospital) - Oncocytoma

References:

Marshall FF, Stewart AK and Menck HR. The National Cancer Data Base. Report on Kidney Cancers. The American College of Surgeons Commission on Cancer and the American Cancer Society. *Cancer* 1997; 80(11):2167-2174.

Eble JN and Hull MT. Morphologic Features of Renal Cell Oncocytoma. A Light and Electron Microscopic Study. *Hum Pathol* 1984; 15(11):1054-1061.

Amin MG, Crotty TB, et al. Renal Oncocytoma. A Reappraisal of Morphologic Features with Clinicopathologic Findings in 80 Cases. *Am J Surg Pathol* 1998; 22(2):271-272.

Tickoo SK, Reuter VE, et al. Renal Oncocytosis. A Morphologic Study of Fourteen Cases. *Am J Surg Pathol* 1999; 23(9):1094-1101.

LLUMC Pathology Residents - Alveolar soft part sarcoma
Mountain View (El Camino Pathology Group) - Alveolar soft part sarcoma
Riverside - Alveolar soft part sarcoma
Bakersfield - Alveolar soft part sarcoma
Orange - Alveolar soft part sarcoma
Ventura (Unilab) - Alveolar soft part sarcoma (2)
Oakland (Kaiser) - Alveolar soft part sarcoma (4)
Long Beach - Alveolar soft part sarcoma (crystalline grid) (9)
Bay Area - Alveolar soft part sarcoma (3)
Monterey - Alveolar soft parts sarcoma
Santa Rosa - Alveolar soft part sarcoma (70-angstrom inclusions) (2)
San Diego - Alveolar soft tissue sarcoma
Santa Barbara - Alveolar soft part sarcoma
Monterey Park - Alveolar soft part sarcoma
Haywood/Fremont - Alveolar soft part sarcoma with rhomboid crystals (3)
Nevada (Western Pathology Consultants) - Alveolar soft part sarcoma
Nebraska (Creighton University) - Alveolar soft part sarcoma
Kansas (Coffeyville Regional Medical Center) - Alveolar soft parts tumor (by light) with crystals (by EM)
Kansas (University of Kansas Medical Center) - Alveolar soft part sarcoma (16)
Indiana (Fort Wayne) - Alveolar soft part sarcoma, rectus femoris muscle
Louisiana (Louisiana State University Medical Center) - Alveolar soft part sarcoma
Wisconsin (Meriter Hospital) - Alveolar soft part sarcoma
Illinois (Dupage Pathology Associates) - Alveolar soft part sarcoma (1); Alveolar rhabdomyosarcoma (1)
Michigan (Oakwood Hospital) - Alveolar soft part sarcoma
Michigan (St Joseph Mercy Hospital) - Alveolar soft part sarcoma
Kentucky (University of Louisville Residents) - Alveolar soft part sarcoma
Florida (Tallahassee) - Alveolar soft part sarcoma
Florida (Munroe Regional Medical Center) - Alveolar soft part sarcoma
Florida (Winter Haven) - Alveolar soft part sarcoma (3)
North Carolina (Wake Forest University) - Alveolar soft part sarcoma
Pennsylvania (Conemaugh Medical Center Residents) - Alveolar soft part sarcoma
Pennsylvania (Lehigh Valley Hospital) - Rhabdomyosarcoma (1); Embryonal rhabdomyosarcoma (1); Alveolar soft part sarcoma (1)
Maryland (Woodbine) - Alveolar soft part sarcoma (2)
Maryland (National Naval Medical Ctr) - Alveolar soft part sarcoma
Maryland (University of Maryland) - Alveolar soft part sarcoma
New Jersey (Overlook Hospital) - Alveolar soft part sarcoma (4)
Massachusetts (New England Medical Center) - Alveolar soft part sarcoma
Connecticut (University of Connecticut Health Center) - Alveolar soft part sarcoma
New York (Beth Israel Medical Center Residents) - Alveolar soft part sarcoma
New York (Northport) - Alveolar soft part sarcoma
New York (New Hyde Park) - Alveolar soft part sarcoma
Alaska (Anchorage) - Alveolar soft part sarcoma
Canada (Foothills Hospital) - Alveolar soft part sarcoma
Portugal - Alveolar soft part sarcoma
Japan (Kyoto) - Alveolar soft part sarcoma (3); Rhabdomyosarcoma (1)
Japan , Kurashiki (Kawasaki Medical School) - Alveolar soft part sarcoma (4)
Singapore - Alveolar soft part sarcoma
Saudi Arabia (King Khalid University Hospital) - Alveolar soft part sarcoma

References:

Gomez JA, Amin MB, et al. Immunohistochemical Profile of Myogenin and MyoD1 Does Not Support Skeletal Muscle Lineage in Alveolar Soft Part Sarcoma. *Arch Pathol Lab Med* 1999; 123(6):503-507.

Joyama S, Ueda T, et al. Chromosome Rearrangement at 17q25 and xp 11.2 in Alveolar Soft-Part Sarcoma. A Case Report and Review of the Literature. *Cancer* 1999; 86(7):1246-1250.

Ordonez NG. Alveolar Soft Part Sarcoma. A Review and Update. *Adv Anat Pathol* 1999; 6(3):125-139.

Husain M and Nguyen GK. Alveolar Soft Part Sarcoma. Report of a Case Diagnosed by Needle Aspiration Cytology and Electron Microscopy. *Acta Cytol* 1995; 39(5):951-954.

d'Amore ES and Ninfo V. Tumors of the Soft Tissues Composed of Large Eosinophilic Cells. *Semin Diagn Pathol* 1999; 16(2):178-189.

LLUMC Pathology Residents - Small cell neuroendocrine carcinoma
Mountain View (El Camino Pathology Group) - Small cell neuroendorcrine carcinoma, intermediate type
Riverside - Neuroedocrine carcinoma
Bakersfield - Neuroendocrine carcinoma (small cell carcinoma)
Orange - Small cell carcinoma
Ventura (Unilab) - Large cell neuroendocrine carcinoma (2)
Oakland (Kaiser) - Small cell neuroendocrine carcinoma (4)
Long Beach - Neuroendocrine carcinoma (neurosecretory granules) (9)
Bay Area - Neuroendocrine carcinoma (2); Malignant carcinoid (1)
Monterey - Neuroendocrine (small cell) carcinoma
Santa Rosa - Neuroendocrine carcinoma (secretory vesicles) (2)
San Diego - Small cell lung carcinoma
Santa Barbara - Neuroendocrine carcinoma
Monterey Park - Oat cell carcinoma
Haywood/Fremont - Large cell neuroendocrine carcinoma (dense core granules) (3)
Nevada (Western Pathology Consultants) - Small cell carcinoma
Nebraska (Creighton University) - Small cell carcinoma with neuroendocrine differentiate
Kansas (Coffeyville Regional Medical Center) - Neuroendocrine (oat cell) carcinoma (by light), neuroendocrine granules (by EM)
Kansas (University of Kansas Medical Center) - Small cell carcinoma (16)
Indiana (Fort Wayne) - Large cell neuroendocrine carcinoma, right upper lobe, lung
Louisiana (Louisiana State University Medical Center) - Neuroendocrine carcinoma
Wisconsin (Meriter Hospital) - Neuroendocrine carcinoma (LNEC, grade 3 vs. atypical carcinoid, grade 2)
Illinois (Dupage Pathology Associates) - Small cell carcinoma, lung (2)
Michigan (Oakwood Hospital) - Small cell carcinoma
Michigan (St Joseph Mercy Hospital) - Small cell carcinoma
Kentucky (University of Louisville Residents) - Small cell carcinoma, mixed type
Florida (Tallahassee) - Small cell undifferentiated carcinoma
Florida (Munroe Regional Medical Center) - Neuroendocrine carcinoma
Florida (Winter Haven) - Small cell carcinoma (2); Atypical carcinoid (1)
North Carolina (Wake Forest University) - Small cell carcinoma
Pennsylvania (Conemaugh Medical Center Residents) - Small cell carcinoma, lung
Pennsylvania (Lehigh Valley Hospital) - Undifferentiated small cell carcinoma (1); Small cell carcinoma (1); Neuroendocrine carcinoma (1)
Maryland (Woodbine) - Small cell carcinoma (2)
Maryland (National Naval Medical Ctr) - Small cell carcinoma (12); Large cell neuroendocrine carcinoma (6)
Maryland (University of Maryland) - Small cell carcinoma
New Jersey (Overlook Hospital) - Large cell neuroendocrine carcinoma (4)
Massachusetts (New England Medical Center) - Small cell (neuroendocrine) carcinoma
Connecticut (University of Connecticut Health Center) - Neuroendocrine carcinoma, intermediate cell
New York (Beth Israel Medical Center Residents) - Carcinoid tumor
New York (Northport) - Neuroendocrine tumor
New York (New Hyde Park) - Small cell carcinoma
Alaska (Anchorage) - Small cell carcinoma of lung
Canada (Foothills Hospital) - Neuroendocrine carcinoma, large cell type
Portugal - Small cell lung carcinoma
Japan (Kyoto) - Small cell carcinoma (3); Large cell neuroendocrine carcinoma (1)
Japan , Kurashiki (Kawasaki Medical School) - Small cell carcinoma (4)
Singapore - Small cell carcinoma, intermediate cell type
Saudi Arabia (King Khalid University Hospital) - Small cell carcinoma

References:

Khuder SA, Dayal HH, et al. Effect of Cigarette Smoking on Major Histological Types of Lung Cancer in Men. *Lung Cancer* 1999; 24(1):45.
Travis WD, Gal AA, et al Reproducibility of Neuroendocrine Lung Tumor Classification. *Hum Pathol* 1998; 29(3):272-279.
Carter D. Small Cell Carcinoma of the Lung. *Am J Surg Pathol* 1983; 7(8):787-795.

LLUMC Pathology Residents - Rhabdomyosarcoma, embryonal
Mountain View (El Camino Pathology Group) - Pleomorphic rhabdomyosarcoma (primary) vs pleuro-pulmonary blastoma
Riverside - Neurofibroma
Bakersfield - Rhabdomyosarcoma
Orange -Rhabdomyosarcoma
Ventura (Unilab) - Embryonal rhabdomyosarcoma (2)
Oakland (Kaiser) - Rhabdomyosarcoma, pleomorphic (3); Infantile fibrosarcoma (1)
Long Beach - Embryonal rhabdomyosarcoma (Z-band material) (9)
Bay Area - Rhabdomyosarcoma (3)
Monterey - Rhabdomyosarcoma, pleomorphic
Santa Rosa - Blastoma (rhabdomyoblastic) (2)
San Diego - Pleuropulmonary blastoma
Santa Barbara - Rhabdomyosarcoma
Monterey Park - Embryonal rhabdomyosarcoma
Haywood/Fremont - Leiomyosarcoma (thin myofilaments and dense bodies) (3)
Nevada (Western Pathology Consultants) - Rhabdomyosarcoma
Nebraska (Creighton University) - Embryonal rhabdomyosarcoma
Kansas (Coffeyville Regional Medical Center) - Rhabdomyosarcoma (by light), filaments, attenuated Z lines (by EM)
Kansas (University of Kansas Medical Center) - Rhabdomyosarcoma (16)
Indiana (Fort Wayne) - Pulmonary blastoma, left lung (pleuropulmonary blastoma of childhood)
Louisiana (Louisiana State University Medical Center) - Rhabdomyosarcoma
Wisconsin (Meriter Hospital) - Rhabdomyosarcoma
Illinois (Dupage Pathology Associates) - Likely metaplastic (sarcomatoid) carcinoma, lung (1); High grade sarcoma (rhabdo vs. carcinosarcoma) (1)
Michigan (Oakwood Hospital) - Pleomorphic rhabdomyosarcoma
Michigan (St Joseph Mercy Hospital) - Pleomorphic rhabdomyosarcoma
Kentucky (University of Louisville Residents) - Rhabdomyosarcoma
Florida (Tallahassee) - Pleomorphic rhabdomyosarcoma
Florida (Munroe Regional Medical Center) - Ganglioneuroblastoma
Florida (Winter Haven) - Leiomyosarcoma (2); Rhabdomyosarcoma (1)
North Carolina (Wake Forest University) - Metastatic alveolar rhabdomyosarcoma
Pennsylvania (Conemaugh Medical Center Residents) - Alveolar rhabdomyosarcoma
Pennsylvania (Lehigh Valley Hospital) - Rhabdomyosarcoma (2); Leiomyosarcoma (1)
Maryland (Woodbine) - Giant cell carcinoma (2)
Maryland (National Naval Medical Ctr) - Rhabdomyosarcoma
Maryland (University of Maryland) - Embryonal rhabdomyosarcoma
New Jersey (Overlook Hospital) - Rhabdomyosarcoma (4)
Massachusetts (New England Medical Center) - Rhabdomyosarcoma
Connecticut (University of Connecticut Health Center) - Rhabdomyosarcoma
New York (Beth Israel Medical Center Residents) - Rhabdomyosarcoma
New York (Northport) - Rhabdomyosarcoma
New York (New Hyde Park) - Rhabdomyosarcoma
Alaska (Anchorage) - Pleomorphic rhabdomyosarcoma
Canada (Foothills Hospital) - Embryonal rhabdomyosarcoma
Portugal - Pleuropulmonary blastoma
Japan (Kyoto) - Embryonal rhabdomyosarcoma (3); Pleuropulmonary blastoma (1)
Japan , Kurashiki (Kawasaki Medical School) - Leiomyosarcoma, metastatic (4)
Singapore - Pleomorphic sarcoma
Saudi Arabia (King Khalid University Hospital) - Rhabdomyosarcoma

References:

Lee SH, Regauchary SS and Paramesh J. Primary Pulmonary Rhabdomyosarcoma. A Case Report and Review of the Literature. *Hum Pathol* 1981; 12(1):92-95.
Przygodzki RM, Moran CA, et al. Primary Pulmonary Rhabdomyosarcomas. A Clinicopathologic and Immunohistochemical Study of Three Cases. *Mod Pathol* 1995; 8(6):658-661.
Wesche WA, Fletcher CD, Dias P, et al. Immunohistochemistry of MyoD1 in Adult Pleomorphic Soft Tissue Sarcomas. *Am J Surg Pathol* 1995; 19(3):261-269.
Dagher R and Helman L. Rhabdomyosarcoma. An Overview. *Oncologist* 1999; 4(1):34-44.
Atahan S, Aksu O and Ekinci C. Cytologic Diagnosis and Subtyping of Rhabdomyosarcoma. *Cytopathol* 1998; 9(6):389-397.