1142

CALIFORNIA
TUMOR TISSUE REGISTRY

"TUMORS OF THE SKIN"

Study Cases, Subscription A

February 2000

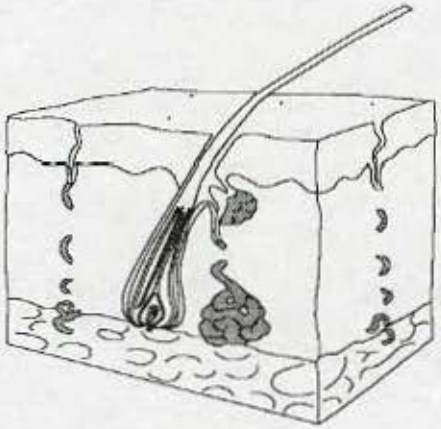

California Tumor Tissue Registry
c/o: Department of Pathology and Human Anatomy
Loma Linda University School of Medicine
11021 Campus Avenue, AH 335
Loma Linda, California 92350
(909) 558-4788
FAX: (909) 558-0188
E-mail: cttr@linkline.com
Case of the Month: www.llu.edu/llu/cttr/cotm

Target audience:

Practicing pathologists and pathology residents.

Goal:

To acquaint the participant with the histologic features of a variety of benign and malignant neoplasms and tumor-like conditions.

Objectives:

The participant will be able to recognize morphologic features of a variety of benign and malignant neoplasms and tumor-like conditions and relate those processes to pertinent references in the medical literature.

Educational methods and media:

Review of representative glass slides with associated histories.
Feedback on consensus diagnoses from participating pathologists.
Listing of selected references from the medical literature.

Principal faculty:

Weldon K. Bullock, MD
Donald R. Chase, MD

CME Credit:

Loma Linda University School of Medicine designates this continuing medical education activity for up to 2 hours of Category I of the Physician's Recognition Award of the American Medical Association.

CME credit is offered for the subscription year only.

Accreditation:

Loma Linda University School of Medicine is accredited by the Accreditation Council for Continuing Medical Education (ACCME) to sponsor continuing medical education for physicians.

Contributor: Arnold A. Channing, M.D.
Canoga Park, CA

Case No. 1 - February 2000

Tissue from: Skin of arm

Accession #17192

Clinical Abstract:

This 45-year-old Asian male reported multiple gradually enlarging masses on the posterior aspect of both forearms. Similar lesions had appeared 10 year previously and had been surgically removed.

Gross Pathology:

Six separate pieces of skin were received, each with a subcutaneous yellow-orange firm nodule. The nodules varied from 0.4 to 4.5 cm in greatest dimension, and each exhibited a firm yellow-orange cut surface.

Contributor: Philip G. Robinson, M.D.
Boynton Beach, FL

Case No. 2 - February 2000

Tissue from: Left chest wall

Accession #28661

Clinical Abstract:

A mass was noted on the left chest wall of this 69-year-old male.

Gross Pathology:

The 11.0 x 10.0 x 3.4 cm round piece of skin and subcutaneous tissue had a 2.0 cm shallow ulcer on the cutaneous surface, which was overlying a 4.5 x 4.0 x 3.6 cm sharply delineated mass of homogeneous white lobulated tissue.

SPECIAL STAINS:

Keratin	negative	Smooth muscle actin	positive
S-100	negative	Desmin	focally positive
CD-34	negative	Muscle specific actin (HHF35)	focally positive
HMB-45	negative		
EMA	negative		
GFAP	negative		
Myoglobin	negative		
MyoD1	negative		

Contributor: Meyer Zeiler, M.D.
Los Angeles, CA

Case No. 3 - February 2000

Tissue from: Right inguinal lymph node

Accession #23101

Clinical Abstract:

During a work-up for severe headaches, physical examination of this 35-year-old Caucasian male revealed cervical and inguinal lymphadenopathy and a mass on the left shoulder. He had had a skin lesion removed from the right thigh two years earlier.

Gross Pathology:

The 2.5 cm diameter oval mass covered by a thin rim of adipose tissue. The cut surface was dark-tan to black.

Contributor: Yasuko Kidokoro, M.D.
San Diego, CA

Case No. 4 - February 2000

Tissue from: Chest wall

Accession #28559

Clinical Abstract:

This 84-year-old African-American woman reported a 60 year history of a massive keloid scarring her chest. Three years prior to presentation, the mass developed an ulceration that had steadily increased in size.

Gross Pathology:

An irregularly shaped portion of skin weighed 1,490 grams and measured up to 22.0 by 20.0 cm. It supported a 12.0 by 11.0 cm centrally ulcerated lesion.

SPECIAL STAINS:

Keratin	trace positive
S100	negative
HMB-45	negative
CD34	negative

Contributor: James J. Norton, M.D.
El Cajon, CA

Case No. 5 - February 2000

Tissue from: Neck

Accession #17255

Clinical Abstract:

A mass on the neck of this 62-year-old Caucasian male had been growing for about two years.

Gross Pathology:

The specimen was a 4.8 x 3.2 cm portion of tan skin with a 1.8 cm diameter firm gray mass.

SPECIAL STAINS:

S100	strongly positive
CAM 5.2	negative
Desmin	negative

Contributor: Reuben Straus, M.D.
Burbank, CA

Case No. 6 - February 2000

Tissue from: Left shoulder

Accession #15545

Clinical Abstract:

For about 20 years this 57-year-old Caucasian male had noticed a left shoulder mass. During the last three years, it had doubled in size.

Gross Pathology:

The 14.0 x 7.0 cm skin specimen was occupied by numerous nodules which measured up to 4.5 cm in diameter. Sectioning of the tumors showed a firm, pinkish gray and slightly whorled architecture.

Contributor: S.K. Abul-Haj, M.D.
Ventura, CA 93003

Case No. 7 - February 2000

Tissue from: Perianal skin

Accession #17260

Clinical Abstract:

During an examination of this 71-year-old Caucasian male, who was complaining of hemorrhoids, the physician noted a peculiar orange peel appearance to the anal skin.

Gross Pathology:

The specimen consisted of a 6.0 cm diameter, roughly circular segment of ano-rectal wall taken through the mucocutaneous junction. The wall varied from 0.2 to 0.6 cm in thickness and had a warty wrinkled surface with an orange-peel appearance.

Contributor: Raid Chappell, M.D.
Modesto, CA

Case No. 8 - February 2000

Tissue from: Left forehead

Accession #17427

Clinical Abstract:

Countless lesions had been removed from the forehead of this 64-year-old Caucasian female over the previous ten to fifteen years. The latest lesion was a smooth discoid swelling up to 6 cm in diameter which gently elevated the overlying intact skin.

Gross Pathology:

The specimen consisted of a round disc of tumor measuring 5.2 cm in diameter and 1.2 cm in thickness, partially surrounded by a rim of cranial bone. The tumor had a rubbery, fibrous consistency with a homogeneous and gray-white cut surface.

SPECIAL STAINS:

Cytokeratin	strongly positive
Factor VIII	negative

Contributor: Paul Ortega, M.D.
Burlingame, CA

Case No. 9 - February 2000

Tissue from: Forehead

Accession #25967

Clinical Abstract:

For 6 months this 85-year-old Caucasian female had noticed a slow growing lesion on her forehead. An excisional biopsy was performed.

Gross Pathology:

A 4.0 x 2.5 cm ellipse of skin had a central elevated ulceration region.

SPECIAL STAINS:

Cytokeratin	strongly positive

Contributor: Lilibeth Guinto-Miranda, M.D.
Bakersfield, CA

Case No. 10 - February 2000

Tissue from: Scalp

Accession #25982

Clinical Abstract:

This 63-year-old female reported a small lump on the back of the head which remained the same size for several years. During the few months prior to presentation, the lump had grown to "the size of a baseball." The patient denied any trauma to the head.

Gross Pathology:

The 212 gram mass was 9.0 x 8.0 x 8.0 cm, rubbery, and showed areas of hemorrhage mixed with yellow coloration.

SPECIAL STAINS:

CD34	positive
CD68	negative

CALIFORNIA TUMOR TISSUE REGISTRY

TUMORS OF THE SKIN

Minutes – Subscription A

February 2000

SUGGESTED READING (General Topics from Recent Literature):

Cell Culture Proof of Neurogenic Potential of Ewing's Sarcoma. Sugimoto T, et al. *Virchows Arch* 1997; 430:41-46.

Immunohistochemical Markers for Distinguishing Spitz Nevi from Malignant Melanomas. Kanter-Lewensohn L, et al. *Mod Pathol* 1997; 10:917-920.

Prognostic Evaluation of Cutaneous Malignant Melanoma. A Clinicopathologic and Immunohistochemical Study. Niezabitowski A, et al. *J of Surg Oncol* 1999; 70:150-160.

California Tumor Tissue Registry
c/o: Department of Pathology and Human Anatomy
Loma Linda University School of Medicine
11021 Campus Avenue, AH 335
Loma Linda, California 92350
(909) 558-4788
FAX: (909) 558-0188
E-mail: cttr@linkline.com
Case of the Month: www.llu.edu/llu/cttr/cotm

Mountain View (El Camino Hospital) - Tuberous xanthoma
Bakersfield - Xanthoma
Bay Area - Granular cell tumor (4)
Santa Rosa - Tuberous xanthoma (2); Fibrous xanthoma (1)
Ventura (Unilab) - Nodular xanthoma (2)
San Diego (Naval Medical Center) - Xanthoma
Oakland (Kaiser) - Xanthoma (4)
Santa Barbara (Cottage Hospital) - Xanthoma
Monterey (Community Hospital of Monterey Peninsula) - Granular cell tumor
Long Beach - Xanthoma (6)
Nevada (Reno) - Granular cell tumor (2)
Utah (Anatomic Pathology Associates) - Tuberous xanthoma
Nebraska (Creighton University) - Xanthoma
Texas, El Paso (Texas Technical Medical Health Center) - Xanthoma
Texas (Residents of University of Texas Medical Branch) - Tuberous xanthoma
Iowa (University of Iowa) - Xanthoma (probably eruptive)
Michigan (Foote Hospital) - Xanthogranuloma
Michigan (St. Joseph Mercy Hospital) - Xanthoma disseminatum (3)
Florida (Tallahassee) - Xanthoma (3)
Florida (Monroe Regional Medical Center) - Lepromatous leprosy
New Jersey (Overlook Hospital) - Tuberous xanthoma (3); Xanthoma r/o lepromatous leprosy (1)
Pennsylvania (Lehigh Valley Pathology Associates) - Malignant pleomorphic fibrous histiocytoma (1); Reticulohistiocytoma (1); Granular cell tumor (1)
Pennsylvania (Residents Conemaugh Memorial Hospital) - Granular cell tumor
Connecticut (University of Connecticut Health Center) - Tuberous xanthoma
Massachusetts (Berkshire Medical Center) - Metabolic storage disease vs. Rosai-Dorfman disease vs. infectious leprosy
New York (Long Island, Jewish Medical Center) - Xanthoma multiple, clinicopathological correlation required
New York (Monteflore Medical Center) - Xanthoma tuberosum
New York (Impath) - Tubero-eruptive xanthoma
Maryland (University of Maryland) - Xanthoma
Maryland (National Naval Medical Center) - Xanthoma
Maryland (Woodbine) - Xanthoma (2)
Japan (Kurashiki) - Xanthoma
Saudi Arabia (King Khalid University Hospital) - Granular cell tumor (5) Xanthoma, skin (1)

DIAGNOSIS:

Tuberous Xanthoma, Skin of Elbow
T-Y8300, M-55320

REFERENCES:

Walton KW, et al. The Pathogenesis of Xanthomata. *J Pathol* 1973; 109:271.
Wilkes LL. Tendon Xanthoma in Type IV Hyperlipoproteinemia. *South Med J* 1977; 70:254.
Cho HR, et al. Generalized Tuberous Xanthoma with Type IV Hyperlipoproteinemia. *Cutis* 1997; 59(6):315-318.

Case No. 2, Accession No. 28661 **February 2000**

Mountain View (El Camino Hospital) - Leiomyosarcoma
Bakersfield - Subcutaneous leiomyosarcoma
Bay Area - Leiomyosarcoma, low grade (4)
Santa Rosa - Leiomyosarcoma (3)
Ventura (Unilab) - Leiomyosarcoma (2)
San Diego (Naval Medical Center) - Leiomyosarcoma
Oakland (Kaiser) - Leiomyosarcoma (4)
Santa Barbara (Cottage Hospital) - Leiomyosarcoma
Monterey (Community Hospital of Monterey Peninsula) - Leiomyosarcoma
Long Beach - Leiomyosarcoma (6)
Nevada (Reno) - Leiomyosarcoma (2)
Utah (Anatomic Pathology Associates) - Leiomyosarcoma
Nebraska (Creighton University) - Leiomyosarcoma
Texas, El Paso (Texas Technical Medical Health Center) - Leiomyosarcoma
Texas (Residents of University of Texas Medical Branch) - Leiomyosarcoma
Iowa (University of Iowa) - Leiomyosarcoma
Michigan (Foote Hospital) - Leiomyosarcoma
Michigan (St. Joseph Mercy Hospital) - Leiomyosarcoma (3)
Florida (Tallahassee) - Leiomyosarcoma/Malignant fibrous histiocytoma (3)
Florida (Monroe Regional Medical Center) - Leiomyosarcoma
New Jersey (Overlook Hospital) - Leiomyosarcoma (4)
Pennsylvania (Lehigh Valley Pathology Associates) - Fibroblastic fibrosarcoma (1); Leiomyosarcoma (2)
Pennsylvania (Residents Conemaugh Memorial Hospital) - Leiomyosarcoma
Connecticut (University of Connecticut Health Center) - MFH (cannot r/o leiomyosarcoma with certainty)
Massachusetts (Berkshire Medical Center) - Leiomyosarcoma
New York (Long Island, Jewish Medical Center) - Leiomyosarcoma
New York (Monteflore Medical Center) - Leiomyosarcoma
New York (Impath) - Leiomyosarcoma
Maryland (University of Maryland) - Cutaneous leiomyosarcoma
Maryland (National Naval Medical Center) - Leiomyosarcoma
Maryland (Woodbine) - Leiomyosarcoma (2)
Japan (Kurashiki) - Leiomyosarcoma
Saudi Arabia (King Khalid University Hospital) - Leiomyosarcoma of skin

DIAGNOSIS:

Cutaneous Leiomyosarcoma, Left Chest
T-Y2100, M-88903

REFERENCES:

Kaddu S, et al. Cutaneous Leiomyosarcoma. *Am J Surg Pathol* 1997; 21(9):979-987.
Montes LF, et al. Response of Leiomyosarcoma to Cryosurgery. A Clinicopathological and Ultrastructural Study. *Clin Exp Dermatol* 1995; 20(1):22-26.
Wascher RA, et al. Recurrent Cutaneous Leiomyosarcoma. *Cancer* 1992; 70(2):90-92.
Dahl I, et al. Cutaneous and Subcutaneous Leiomyosarcoma. A Clinicopathologic Study of 47 Patients. *Pathol Eur* 1974; 9(4):307-315.

Mountain View (El Camino Hospital) - Metastatic melanoma
Bakersfield - Metastatic melanoma
Bay Area - Melanoma, metastatic (4)
Santa Rosa - Metastatic melanoma (2); Lymph node with metastatic melanoma (1)
Ventura (Unilab) - Metastatic melanoma
San Diego (Naval Medical Center) - Metastatic melanoma
Oakland (Kaiser) - Metastatic melanoma (4)
Santa Barbara (Cottage Hospital) - Metastatic melanoma
Monterey (Community Hospital of Monterey Peninsula) - Metastatic melanoma
Long Beach - Metastatic malignant melanoma (6)
Nevada (Reno) - Metastatic melanoma (2)
Utah (Anatomic Pathology Associates) - Metastatic melanoma
Nebraska (Creighton University) - Metastatic melanoma
Texas, El Paso (Texas Technical Medical Health Center) - Metastatic malignant melanoma
Texas (Residents of University of Texas Medical Branch) - Metastatic melanoma
Iowa (University of Iowa) - Metastatic melanoma
Michigan (Foote Hospital) - Metastatic melanoma
Michigan (St. Joseph Mercy Hospital) - Metastatic melanoma (3)
Florida (Tallahassee) - Metastatic malignant melanoma
Florida (Monroe Regional Medical Center) - Metastatic melanoma
New Jersey (Overlook Hospital) - Metastatic melanoma (4)
Pennsylvania (Lehigh Valley Pathology Associates) - Metastatic melanocarcinoma in lymphoid tissues (1); Metastatic melanoma (2)
Pennsylvania (Residents Conemaugh Memorial Hospital) - Metastatic malignant melanoma
Connecticut (University of Connecticut Health Center) - Metastatic melanoma
Massachusetts (Berkshire Medical Center) - Metastatic melanoma
New York (Long Island, Jewish Medical Center) - Metastatic malignant melanoma
New York (Montefiore Medical Center) - Metastatic melanoma to lymph node
New York (Impath) - Metastatic melanoma
Maryland (University of Maryland) - Metastatic melanoma
Maryland (National Naval Medical Center) - Metastatic melanoma
Maryland (Woodbine) - Metastatic melanoma (2)
Japan (Kurashiki) - Malignant melanoma, metastatic
Saudi Arabia (King Khalid University Hospital) - Metastatic malignant melanoma

DIAGNOSIS:

Metastatic Melanoma, Inguinal Lymph Nodes
T-08000, M-87203

REFERENCES:

Karakousis CP, et al. Survival after Groin Dissection for Malignant Melanoma. *Surg* 1991; 109(2):119-126.
Pu LL, et al. Lymphatic Mapping and Sentinel Lymph Node Biopsy In Patients with Melanoma of the Lower Extremity. *Plast Reconstr Surg* 1999; 104(4):964-969.
Singletary SE, et al. Melanoma with Metastasis to Regional Axillary or Inguinal Lymph Nodes. Prognostic Factors and Results of Surgical Treatment in 714 Patients. *South Med J* 1988; 81(1):5-9.
Jonk A, et al. Contralateral Inguinal Lymph Node Metastasis in Patients with Melanoma of the Lower Extremities. *Br J Surg* 1989; 76(11):1161-1162.

Case No. 4, Accession No. 28559 **February 2000**

Mountain View (El Camino Hospital) - Pigmented squamous cell carcinoma
Bakersfield - Metastatic carcinoma
Bay Area - Squamous cell carcinoma (3); Carcinoma, NOS (1)
Santa Rosa - Malignant adnexal tumor (1); Metastatic carcinoma (1); Metastatic carcinoma, differential diagnosis-melanoma (1)
Ventura (Unilab) - Metastatic carcinoma, probable breast, within keloid (2)
San Diego (Naval Medical Center) - Microcystic adnexal carcinoma (5); Squamous cell carcinoma (2); Basal cell carcinoma (2)
Oakland (Kaiser) - Poorly differentiated squamous cell carcinoma (4)
Santa Barbara (Cottage Hospital) - Squamous cell carcinoma in keloid
Monterey (Community Hospital of Monterey Peninsula) - Metastatic carcinoma
Long Beach - Adnexal carcinoma (6)
Nevada (Reno) - Malignant skin adnexal tumor (1); Malignant adnexal tumor, favor sclerosing sweat duct carcinoma (1)
Utah (Anatomic Pathology Associates) - Squamous cell carcinoma
Nebraska (Creighton University) - Squamous cell carcinoma
Texas, El Paso (Texas Technical Medical Health Center) - Adnexal carcinoma, well-differentiated
Texas (Residents of University of Texas Medical Branch) - Well-differentiated, invasive squamous cell carcinoma with involvement of underlying keloid
Iowa (University of Iowa) - Squamous cell carcinoma arising in scar
Michigan (Foote Hospital) - Pigmented squamous cell carcinoma
Michigan (St. Joseph Mercy Hospital) - Invasive carcinoma with squamous differentiation, primary vs. metastatic (? breast) (3)
Florida (Tallahassee) - Metaplastic carcinoma/squamous cell carcinoma
Florida (Monroe Regional Medical Center) - Squamous cell carcinoma
New Jersey (Overlook Hospital) - Sweat duct carcinoma (3); Squamous cell carcinoma arising in a keloid (1)
Pennsylvania (Lehigh Valley Pathology Associates) - Poorly to moderate differentiated squamous cell carcinoma growing in a background of an ulcerated keloid with areas of melanin deposits (in African-American female patients) (1); Epithelioid sarcoma (1); Infiltrating carcinoma, favor squamous (1)
Pennsylvania (Residents Conemaugh Memorial Hospital) - Sweat gland carcinoma, sclerosing type
Connecticut (University of Connecticut Health Center) - Desmoplastic squamous cell carcinoma
Massachusetts (Berkshire Medical Center) - Probable mammary carcinoma
New York (Long Island, Jewish Medical Center) - Squamous adnexal tumor with melanotic hyperplasia resembling microcystic carcinoma
New York (Monteflore Medical Center) - Squamous cell carcinoma involving keloid vs. breast carcinoma involving keloid/favor former
New York (Impath) - Squamous cell carcinoma arising in keloid
Maryland (University of Maryland) - Microcystic adnexal carcinoma
Maryland (National Naval Medical Center) - Infiltrating carcinoma (NOS)
Maryland (Woodbine) - Ductal carcinoma of the breast (1); Metaplastic carcinoma, metastatic (1)
Japan (Kurashiki) - Squamous cell carcinoma
Saudi Arabia (King Khalid University Hospital) - Desmoplastic malignant melanoma

DIAGNOSIS:

Pigmented Sweat Gland Carcinoma, Skin of Breast
T-04000, M-80723

Consultation: Juan Rosai, M.D., Memorial Sloan-Kettering Cancer Center. "Pigmented sweat gland carcinoma."

REFERENCES:

Swanson PE, et al. Eccrine Sweat Gland Carcinoma. A Histologic and Immunohistochemical Study of 32 Cases. *J Cutan Pathol* 1987; 14(2):65-86.
Swanson PE, et al. Immunoreactivity for Estrogen Receptor Protein in Sweat Gland Tumors. *Am J Surg Pathol* 1991; 15(9):835-841.
Cruz DJ. Sweat Gland Carcinoma. A Comprehensive Review. *Semin Diagn Pathol* 1987; 4(1):38-74.

Case No. 5, Accession No. 17255 **February 2000**

Mountain View (El Camino Hospital) - Spindle cell melanoma
Bakersfield - Malignant nerve sheath tumor
Bay Area - Malignant nerve sheath tumor (schwannoma features) (4)
Santa Rosa - Malignant schwannoma rule out melanoma (1); Malignant schwannoma (2)
Ventura (Unilab) - Neurofibrosarcoma (2)
San Diego (Naval Medical Center) - Malignant peripheral nerve sheath tumor (7); Spindle cell melanoma (2)
Oakland (Kaiser) - Melanoma-spindle cell type (4)
Santa Barbara (Cottage Hospital) - Malignant peripheral nerve sheath tumor
Monterey (Community Hospital of Monterey Peninsula) - Neurofibrosarcoma
Long Beach - Malignant schwannoma (6)
Nevada (Reno) - Malignant schwannoma (1); Malignant peripheral nerve sheath tumor (1)
Utah (Anatomic Pathology Associates) - Malignant peripheral nerve sheath tumor vs. leiomyosarcoma
Nebraska (Creighton University) - Malignant schwánnoma
Texas, El Paso (Texas Technical Medical Health Center) - Malignant peripheral nerve sheath tumor
Texas (Residents of University of Texas Medical Branch) - Malignant peripheral nerve sheath tumor
Iowa (University of Iowa) - Malignant peripheral nerve sheath tumor
Michigan (Foote Hospital) - Spindle cell melanoma
Michigan (St. Joseph Mercy Hospital) - Malignant peripheral nerve sheath tumor vs. melanoma (3)
Florida (Tallahassee) - Spindle cell melanoma (3)
Florida (Monroe Regional Medical Center) - Malignant peripheral nerve sheath tumor
New Jersey (Overlook Hospital) - Neurofibrosarcoma (3); Cellular schwannoma (1)
Pennsylvania (Lehigh Valley Pathology Associates) - Amelanotic malignant melanoma spindle cell acroma-like features and alveolar patterns (1); Melanoma (1); Neurogenic sarcoma (1)
Pennsylvania (Residents Conemaugh Memorial Hospital) - Malignant peripheral nerve sheath tumor
Connecticut (University of Connecticut Health Center) - Malignant peripheral nerve sheath tumor (must also consider spindle cell melanoma)
Massachusetts (Berkshire Medical Center) - Desmoplastic melanoma
New York (Long Island, Jewish Medical Center) - Sarcoma, favor malignant peripheral nerve sheath tumor (should perform HMB-45 to exclude melanoma)
New York (Monteflore Medical Center) - Neurofibrosarcoma
New York (Impath) - Spindle cell melanoma
Maryland (University of Maryland) - Spindle cell malignant melanoma
Maryland (National Naval Medical Center) - Spindle cell melanoma (7); Malignant peripheral nerve sheath tumor (6)
Maryland (Woodbine) - Malignant peripheral nerve sheath tumor (2)
Japan (Kurashiki) - Malignant melanoma, spindle-cell
Saudi Arabia (King Khalid University Hospital) - Malignant peripheral nerve sheath tumor

DIAGNOSIS:

Spindle Cell Melanoma, Skin of Neck
T-02300, M-87723

Directors Note: Virtually all spindle cell melanomas stain for S-100 protein, but fail to express HMB-45. (drc)

REFERENCES:

Nahkleh RE, et al. Morphologic Diversity in Malignant Melanomas. *Am J Clin Pathol* 1990; 93(6):731-740.
Anstey A, et al. Desmoplastic Malignant Melanoma. An Immunohistochemical Study of 25 Cases. *Am J Dermatopathol* 1994; 16(1):14-22.
Whorton JM, et al. Desmoplastic Malignant Melanoma. Diagnosis of Early Clinical Lesions. *Hum Pathol* 1999; 30(5):537-542.
Wick MR, et al. Cutaneous Sarcomas and Sarcomatoid Neoplasms of the Skin. *Semin Diagn Pathol* 1993; 10(2):148-158.

Case No. 6, Accession No. 15545 **February 2000**

Mountain View (El Camino Hospital) - Dermatofibrosarcoma protuberans
Bakersfield - Dermatofibroma
Bay Area - Schwannoma (2); Neurofibroma (2)
Santa Rosa - Dermatofibrosarcoma protuberans (1); Fibromatosis/dermatofibrosarcoma protuberans (1); Dermatofibrosarcoma protuberans, differential diagnosis-dermatofibroma (1)
Ventura (Unilab) - Neurilemmoma (2)
San Diego (Naval Medical Center) - Dermatofibrosarcoma protuberans (DFSP)
Oakland (Kaiser) - Dermatofibrosarcoma protuberans (4)
Santa Barbara (Cottage Hospital) - Dermatofibrosarcoma protuberans
Monterey (Community Hospital of Monterey Peninsula) - Dermatofibrosarcoma protuberans
Long Beach - Dermatofibrosarcoma protuberans (6)
Nevada (Reno) - Dermatofibrosarcoma protuberans (2)
Utah (Anatomic Pathology Associates) - Dermatofibrosarcoma protuberans
Nebraska (Creighton University) - Dermatofibrosarcoma protuberans
Texas, El Paso (Texas Technical Medical Health Center) - Elastofibroma
Texas (Residents of University of Texas Medical Branch) - Dermatofibrosarcoma protuberans
Iowa (University of Iowa) - Plexiform neurofibroma
Michigan (Foote Hospital) - Dermatofibrosarcoma protuberans
Michigan (St. Joseph Mercy Hospital) - Dermatofibrosarcoma protuberans (3)
Florida (Tallahassee) - Dermatofibrosarcoma protuberans
Florida (Monroe Regional Medical Center) - Elastofibroma
New Jersey (Overlook Hospital) - Dermatofibrosarcoma protuberans (4)
Pennsylvania (Lehigh Valley Pathology Associates) - Desmoid tumor (1); Dermatofibrosarcoma (1); Malignant fibrous histiocytoma (1)
Pennsylvania (Residents Conemaugh Memorial Hospital) - Dermatofibroma/pigmented DFSP (Bednar's tumor)
Connecticut (University of Connecticut Health Center) - Dermatofibrosarcoma protuberans, low grade
Massachusetts (Berkshire Medical Center) - Dermatofibrosarcoma protuberans
New York (Long Island, Jewish Medical Center) - Dermatofibrosarcoma protuberans (DFSP)
New York (Monteflore Medical Center) - Dermatofibrosarcoma protuberans
New York (Impath) - Dermatofibrosarcoma protuberans
Maryland (University of Maryland) - Bednar tumor
Maryland (National Naval Medical Center) - Dermatofibrosarcoma protuberans
Maryland (Woodbine) - Schwannoma (2)
Japan (Kurashiki) - Dermatofibrosarcoma protuberans
Saudi Arabia (King Khalid University Hospital) - Dermatofibrosarcoma protuberans (5); Cellular variant of dermatofibroma (1)

DIAGNOSIS:

Pigmented Dermatofibrosarcoma Protuberans ("Bednar Tumor"), Skin of Shoulder
T-Y1220, M-88323

REFERENCES:

Davis DA, et al. Atrophic and Plaquelike Fibrosarcoma Protuberans. *Am J Dermatol* 1998; 20(5):498-501.
Carlson A, et al. (Letter to the Editor.) Dermatofibrosarcoma Protuberans Can Induce Epidermal Hyperplasia that is Inversely Related to its Proximity to the Dermis. *Am J Dermatol* 1998; 20(4):428-430.
Franchi A, et al. Tenascin Expression in Cutaneous Fibrohistiocytic Tumors. Immunohistochemical Investigation of 24 Cases. *Am J Dermatopathol* 1996; 18(5):454-459.
Duda RB, et al. Growth Factor Receptor and Related Oncogene Determination in Mesenchymal Tumors. *Cancer* 1993; 71(11):3526-3530.

Case No. 7, Accession No. 17260 **February 2000**

Mountain View (El Camino Hospital) - Extramammary Paget's disease
Bakersfield - Extramammary Paget's disease
Bay Area - Adenocarcinoma with Paget's disease (4)
Santa Rosa - Extramammary Paget's disease rule out melanoma with IPOX (1); Extramammary Paget's disease (1); Melanoma, differential diagnosis-Paget's disease (1)
Ventura (Unilab) - Extramammary Paget's disease (2)
San Diego (Naval Medical Center) - Extramammary Paget's disease (8); Extramammary Paget's disease, favor secondary (2)
Oakland (Kaiser) - Extramammary Paget's disease (4)
Santa Barbara (Cottage Hospital) - Extramammary Paget's disease
Monterey (Community Hospital of Monterey Peninsula) - Paget's disease
Long Beach - Paget's disease (6)
Nevada (Reno) - Paget's disease of skin (1); Extramammary Paget's disease (1)
Utah (Anatomic Pathology Associates) - Extramammary Paget's disease
Nebraska (Creighton University) - Extramammary Paget's disease
Texas, El Paso (Texas Technical Medical Health Center) - Paget's disease, extramammary
Texas (Residents of University of Texas Medical Branch) - Extramammary Paget's disease
Iowa (University of Iowa) - Extramammary Paget's disease/hemorrhoids
Michigan (Foote Hospital) - Extramammary Paget's disease
Michigan (St. Joseph Mercy Hospital) - Extramammary Paget's disease (3)
Florida (Tallahassee) - Extramammary Paget's disease
Florida (Monroe Regional Medical Center) - Paget's disease
New Jersey (Overlook Hospital) - Extramammary Paget's disease (4)
Pennsylvania (Lehigh Valley Pathology Associates) - Superficial spreading malignant melanoma (premalignant melanosis or pagetoid melanoma) (1); Paget's disease (1); Paget's disease of anus (1)
Pennsylvania (Residents Conemaugh Memorial Hospital) - Extramammary Paget's disease
Connecticut (University of Connecticut Health Center) - Paget's disease and underlying angioma
Massachusetts (Berkshire Medical Center) - Extramammary Paget's disease
New York (Long Island, Jewish Medical Center) - Paget's disease
New York (Monteflore Medical Center) - Extramammary Paget's disease
New York (Impath) - Extramammary Paget's disease
Maryland (University of Maryland) - Extramammary Paget's
Maryland (National Naval Medical Center) - Paget's disease
Maryland (Woodbine) - Extramammary Paget's disease (2)
Japan (Kurashiki) - Paget's disease, extramammary, possibly secondary
Saudi Arabia (King Khalid University Hospital) - Extramammary Paget's disease (5); mucin secreting adenocarcinoma with pagetoid spread (1)

DIAGNOSIS:

Extramammary Paget's Disease, Perianal Skin
T-69000, M-85423

REFERENCES:

Sitakalin C, et al. Mammary and Extramammary Paget's Disease. *Am J Dermatopathol* 1985; 7(4):335-340.
Kariniemi AL, et al. Paget's Cell Express Cytokeratins Typical of Glandular Epithelia. *Br J Dermatol* 1985; 112(2):179-183.
Mori O, et al. Expression of ras p21 in Mammary and Extramammary Paget's Disease. *Arch Pathol Lab Med* 1990; 114(8):858-861.
Keatings L, et al. c-erbB-2 Oncoprotein Expression in Mammary and Extra-Mammary Paget's Disease. An Immunohistochemical Study. *Histopathology* 1990; 17(3):243-247.
Goldblum JR, et al. Perianal Paget's Disease. A Histologic and Immunohistochemical Study of 11 Cases With and Without Associated Rectal Adenocarcinoma. *Am J Surg Pathol* 1998; 22(2):170-179.

Case No. 8, Accession No. 17427 **February 2000**

Mountain View (El Camino Hospital) - Adenoid squamous cell carcinoma
Bakersfield - Poorly differentiated carcinoma
Bay Area - Adenocarcinoma (?adnexal origin) (4)
Santa Rosa - Malignant adnexal neoplasm (1); Metastatic renal cell carcinoma (1); Malignant neoplasm (biphasic pattern) (1)
Ventura (Unilab) - Metastatic carcinoma, probable breast (2)
San Diego (Naval Medical Center) - Malignant adnexal carcinoma, NOS (8); Squamous cell carcinoma (2)
Oakland (Kaiser) - Ductal carcinoma (4)
Santa Barbara (Cottage Hospital) - Carcinoma, favor adenocarcinoma
Monterey (Community Hospital of Monterey Peninsula) - Adenocarcinoma
Long Beach - Carcinoma (acantholytic squamous cell carcinoma?) (6)
Nevada (Reno) - Recurrent poorly differentiated carcinoma (1); Infiltrating carcinoma, favor acantholytic squamous cell
Utah (Anatomic Pathology Associates) - Adnexal carcinoma
Nebraska (Creighton University) - Malignant syringoma
Texas, El Paso (Texas Technical Medical Health Center) - Adenocarcinoma
Texas (Residents of University of Texas Medical Branch) - Clear cell eccrine carcinoma (clear cell hidradenocarcinoma)
Iowa (University of Iowa) - Ductal eccrine carcinoma
Michigan (Foote Hospital) - Epithelioid angiosarcoma
Michigan (St. Joseph Mercy Hospital) - Pseudoangiomatous squamous carcinoma (3)
Florida (Tallahassee) - Metastatic carcinoma favor breast-metastatic clear cell carcinoma
Florida (Monroe Regional Medical Center) - Basal cell carcinoma with sebaceous differentiation
New Jersey (Overlook Hospital) - Acantholytic squamous cell carcinoma (1); Epithelioid sarcoma (2); Eccrine gland carcinoma (1)
Pennsylvania (Lehigh Valley Pathology Associates) - Monophasic sclerosing tendosynovial sarcoma or "epithelioid sarcoma" (trapped in collagenous dense stroma) (1); Adenocarcinoma (1); Metastatic poorly differentiated non-small cell carcinoma (1)
Pennsylvania (Residents Conemaugh Memorial Hospital) - Sebaceous carcinoma/eccrine adenocarcinoma
Connecticut (University of Connecticut Health Center) - Adenosquamous cell carcinoma
Massachusetts (Berkshire Medical Center) - Metastatic carcinoma
New York (Long Island, Jewish Medical Center) - Sebaceous carcinoma ? arising in the background of Muir-Torre syndrome
New York (Monteflore Medical Center) - Metatypical basal cell carcinoma
New York (Impath) - Invasive carcinoma primary in skin
Maryland (University of Maryland) - Adenocarcinoma, unknown primary
Maryland (National Naval Medical Center) - Poorly differentiated carcinoma, possibly metastatic breast carcinoma
Maryland (Woodbine) - Poorly differentiated carcinoma (1); Pleomorphic carcinoma (1)
Japan (Kurashiki) - Squamous cell carcinoma, angiomatoid
Saudi Arabia (King Khalid University Hospital) - Malignant appendageal tumor, probably arising on a background of multiple cylinidromas; Sweat gland carcinoma; Metastatic adenocarcinoma

DIAGNOSIS:

Invasive Carcinoma of Skin (NOS), Forehead
T-Y0110, M-80103

REFERENCES:

Miller SJ, et al. Biology of Basal Cell Carcinoma (Part I). *J Am Acad Dematol* 1991; 24(1):1-13.
Miller DL, et al. Non Melanoma Skin Cancer in the United States. Incidence. *J Am Acad Dermatol* 1994; 30(5 Pt 1):774-778.
Johnson TM, et al. Unusual Basal Cell Carcinoma. *Cutis* 1994; 54:85-92.
Oram Y, et al. Histologic Patterns of Basal Cell Carcinoma Based Upon Patient Immunostatus. *Dermatol Surg* 1995; 21(7):611-614.
Randle HW, et al. Basal Cell Carcinoma. Identification and Treatment of the High-Risk Patient. *Dermatol Surg* 1996; 22(3):255-261.

Case No. 9, Accession No. 25967 **February 2000**

Mountain View (El Camino Hospital) - Sarcomatoid squamous cell carcinoma
Bakersfield - Poorly differentiated carcinoma, possible squamous
Bay Area - Squamous cell carcinoma (4)
Santa Rosa - Poorly differentiated squamous cell carcinoma (1) Pseudosarcomatous squamous cell carcinoma (1); Poorly differentiated carcinoma (probably squamous) and a seborrheic keratosis (1)
Ventura (Unilab) - Poorly differentiated squamous cell carcinoma (2)
San Diego (Naval Medical Center) - Spindle cell squamous cell carcinoma
Oakland (Kaiser) - Sarcomatoid squamous cell carcinoma (4)
Santa Barbara (Cottage Hospital) - Squamous cell carcinoma
Monterey (Community Hospital of Monterey Peninsula) - Squamous cell carcinoma
Long Beach - Spindle cell squamous cell carcinoma (6)
Nevada (Reno) - Poorly differentiated carcinoma (1); Carcinoma of possible adnexal derivation (1)
Utah (Anatomic Pathology Associates) - Squamous cell carcinoma-spindle cell
Nebraska (Creighton University) - Malignant eccrine poroma
Texas, El Paso (Texas Technical Medical Health Center) - Malignant eccrine poroma
Texas (Residents of University of Texas Medical Branch) - Squamous cell carcinoma, spindle cell type
Iowa (University of Iowa) - Poorly differentiated carcinoma, need to rule out sebaceous carcinoma
Michigan (Foote Hospital) - Carcinoma, rule out ? (illegible)
Michigan (St. Joseph Mercy Hospital) - Poorly differentiated carcinoma, eccrine vs. sebaceous origin (3)
Florida (Tallahassee) - Poorly differentiated carcinoma, r/o epithelioid sarcoma
Florida (Monroe Regional Medical Center) - Squamous cell carcinoma
New Jersey (Overlook Hospital) - Invasive squamous cell carcinoma (undifferentiated) (1); Poorly differentiated carcinoma (1); Undifferentiated malignant tumor (2)
Pennsylvania (Lehigh Valley Pathology Associates) - Malignant pleomorphic fibrous xanthoma (fibroxanthosarcoma) (1); Apocrine adenocarcinoma (1); Poorly differentiated non-small cell carcinoma, favor squamous (1)
Pennsylvania (Residents Conemaugh Memorial Hospital) - Spindle cell squamous cell carcinoma
Connecticut (University of Connecticut Health Center) - Poorly differentiated skin appendage carcinoma
Massachusetts (Berkshire Medical Center) - Invasive squamous cell carcinoma
New York (Long Island, Jewish Medical Center) - Spindle cell squamous carcinoma
New York (Monteflore Medical Center) - Spindle cell squamous cell carcinoma
New York (Impath) - Poorly differentiated squamous carcinoma with overlying seborrheic keratosis
Maryland (University of Maryland) - Squamous cell carcinoma
Maryland (National Naval Medical Center) - Poorly differentiated carcinoma
Maryland (Woodbine) - Seborrheic keratosis with SCC (2)
Japan (Kurashiki) - Carcinoma, spindle cell
Saudi Arabia (King Khalid University Hospital) - Spindle cell squamous carcinoma (2); Sebaceous carcinoma (3); Metastatic renal cell carcinoma (1)

DIAGNOSIS:

Spindle Cell Carcinoma Skin of Forehead
T-Y0110, M-80323

REFERENCES:

Marks R, et al. Squamous Cell Carcinoma. *Lancet* 1996; (9003) 347:735-738.
Berstein SC, et al. The Many Faces of Squamous Cell Carcinoma. *Dermatol Surg* 1996; 22(3):243-254.
Smith KJ, et al. Spindle Cell Neoplasms Co Expressing Cytokeratin and Vimentin (Metaplastic Squamous Cell Carcinoma). *J Cutan Pathol* 1992; 19(4):286-293.
Ampil FL, et al. Perineural Invasion in Skin Cancer of the Head and Neck. *J Oral Maxillofac Surg* 1995; 53(1):34-38.

Case No. 10, Accession No. 25982 **February 2000**

Mountain View (El Camino Hospital) - Hemangiopericytoma
Bakersfield - Vascular tumor of intermediate malignancy
Bay Area - Hemangiopericytoma (2); Vasoformative tumor (1); Solitary fibrous tumor ? meningioma (1)
Santa Rosa - Hemangiopericytoma vs. hemangiosarcoma (1); hemangiopericytoma rule out other mesenchymal tumor (1); Hemangioendothelioma (spindle cell type), need reticulin stain –differential diagnosis-hemangiopericytoma (1)
Ventura (Unilab) - Hemangiopericytoma (2)
San Diego (Naval Medical Center) - Hemangiopericytoma
Oakland (Kaiser) - Hemangiopericytoma/solitary fibrous tumor (4)
Santa Barbara (Cottage Hospital) - Solitary fibrous tumor
Monterey (Community Hospital of Monterey Peninsula) - Hemangiopericytoma
Long Beach - Dermatofibrosarcoma protuberans (6)
Nevada (Reno) - Solitary fibrous tumor of skin (1); Hemangiopericytoma (1)
Utah (Anatomic Pathology Associates) - Hemangiopericytoma vs. hemangioendothelioma vs. solitary fibrous tumor
Nebraska (Creighton University) - Hemangiopericytoma
Texas, El Paso (Texas Technical Medical Health Center) - Dermatofibrosarcoma protuberans
Texas (Residents of University of Texas Medical Branch) - Hemangiopericytoma
Iowa (University of Iowa) - Dermatofibrosarcoma protuberans
Michigan (Foote Hospital) - Hemangiopericytoma
Michigan (St. Joseph Mercy Hospital) - Dermatofibrosarcoma protuberans
Florida (Tallahassee) - Dermatofibrosarcoma protuberans
Florida (Monroe Regional Medical Center) - Dermatofibrosarcoma protuberans
New Jersey (Overlook Hospital) - Hemangiopericytoma (4)
Pennsylvania (Lehigh Valley Pathology Associates) - Dermatofibrosarcoma protuberans (1); Hemangiopericytoma (2)
Pennsylvania (Residents Conemaugh Memorial Hospital) - Hemangiopericytoma/Dermatofibrosarcoma protuberans
Connecticut (University of Connecticut Health Center) - Hemangiopericytoma
Massachusetts (Berkshire Medical Center) - Dermatofibrosarcoma protuberans
New York (Long Island, Jewish Medical Center) - Hemangiopericytoma, differential diagnosis: meningioma, solitary fibrous tumor (1)
New York (Montefiore Medical Center) - Hemangiopericytoma
New York (Impath) - Dermatofibrosarcoma protuberans
Maryland (University of Maryland) - Dermatofibrosarcoma protuberans
Maryland (National Naval Medical Center) - Hemangiopericytoma
Maryland (Woodbine) - Hemangiopericytoma (2)
Japan (Kurashiki) - So-called hemangiopericytoma
Saudi Arabia (King Khalid University Hospital) - Dermatofibrosarcoma protuberance

DIAGNOSIS:

Hemangiopericytoma, Scalp
T-Y0160, M-91501

REFERENCES:

Okamura JM, et al. Solitary Fibrous Tumor of the Skin. *Am J Dermatopathol* 1997; 19(5):515-518.
Nappi O, et al. Hemangiopericytoma. Histopathological Pattern or Clinicopathologic Entity? *Semin Diagn Pathol* 1995; 12(3):221-232.
Craven JP, et al. Current Management and Clinical Outcome of Hemangiopericytomas. *Am J Surg* 1992; 163(5):490-493.
Philippou S, et al. Hemangiopericytoma of the Head and Neck Region. A Clinical and Morphological Study of Three Cases. *Int J Oral Maxillofac Surg* 1992; 21(2):99-103.
Nemes Z. Differentiation Markers in Hemangiopericytoma. *Cancer* 1992; 69(1):133-140.