874

PATHOLOGISTS' CLUB
OF NEW YORK

WMP

MEETING

PRESIDENT
BOYCE BENNETT, M.D.
JACK D. WEILER HOSPITAL OF
ALBERT EINSTEIN COLLEGE OF MEDICINE
1825 EASTCHESTER ROAD
BRONX, NEW YORK 10461

VICE - PRESIDENT
MARIUS P. VALSAMIS, M.D.
DEPARTMENT OF PATHOLOGY
NEW YORK MEDICAL COLLEGE
VALHALLA, NEW YORK 10595

SECRETARY TREASURER
FRED B. SMITH, M.D.
DEPARTMENT OF PATHOLOGY
ST. VINCENT'S HOSPITAL
153 WEST 11TH STREET
NEW YORK, NY 10011

DATE: Thursday, June 3, 1993

PLACE: The Long Island College Hospital
357 Hicks Street
(between Amity St. and Atlantic Ave.)
Brooklyn, NY 11201

HOST: Dr. John K. H. Li
Department of Pathology
The Long Island College Hospital
718-780-1005

****

RECEPTION AND DINNER: 5:15 - 7:00 PM: Othmer Conference Room A

SCIENTIFIC SESSION: 7:00 - 9:00 PM: Othmer Conference Room B

****

DIRECTIONS: By subway and car: See map on reverse.

PARKING: Parking is available on the Henry Street parking lots. You may park after identifying yourself as a member or guest of the Pathologists' Club.

After parking, walk 1/2 block to Amity Street, make a right turn and walk to Hicks Street, and make another right. In the middle of the block is the entrance to the Hospital.

Directions to: THE LONG ISLAND COLLEGE HOSPITAL

SUBWAY: **F & G** trains to Bergen Street (corner of Smith Street), 5 blocks away; or **A** and **C** trains to Jay St Borough Hall, transfer to **F** across the platform, ride one stop to Bergen Street. **2, 3, 4** and **5** trai Borough Hall, **R** and **M** trains to Court Street, 8 blocks away.

CAR: FDR Drive to Brooklyn Bridge- exit on **Adams Street** - drive straight to - **Atlantic Avenue**. Ma **RIGHT** - drive straight to **Henry Street**. On Henry Street make a **LEFT**. L.I.C.H. covers e block.

Brooklyn -Queens Exressway - Exit **27 Atlantic Avenue** - drive straight to Henry Street. Make a t on Henry Street - parking lots located on the right and left side of the block.

Parking: will be available in the Henry Street lots : 2 located on the right hand side of the b (between Pacific and Amity Streets) and 1 across the street (left hand side) corner of Pacific Str

▲ - COURT STREET

● - JAY STREET-BOROUGH HALL, BERGEN STR

■ - BOROUGH HALL

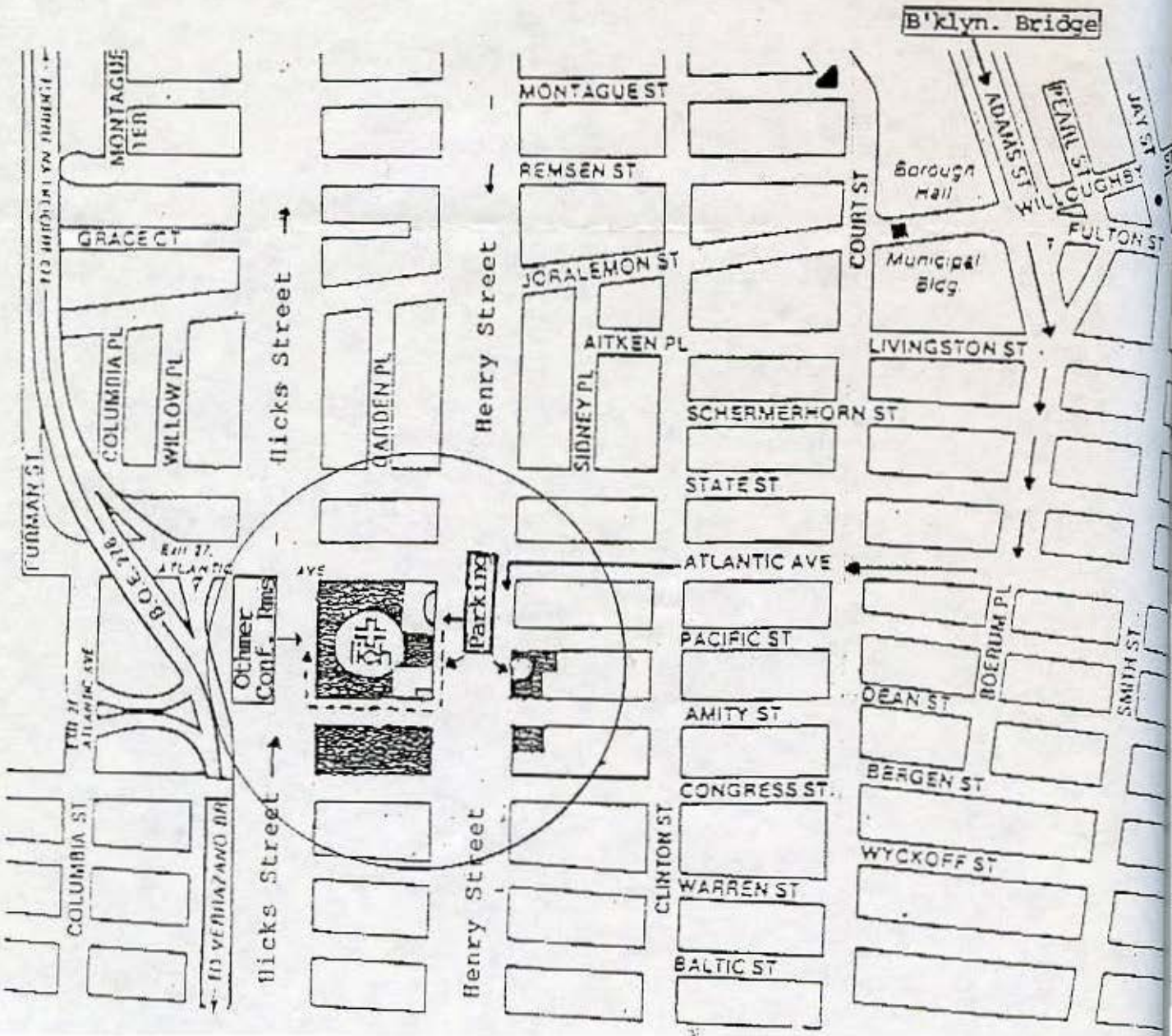

CLINICAL SUMMARIES

Guest: Dr. Peter Farmer Host: Dr. Y. F. Ku

Case #1

A 16 year old black female admitted with a 3-day history of neck stiffness, headache, progressive lower limb weakness, and vomiting. The patient had no significant illnesses except for childhood asthma. There was no history of heredofamilial disease. HIV status was unknown. A CT scan of the head showed mild hydrocephalus, increased density in the basilar system and along tentorium, right frontal encephalomalacia. CSF: RBC 7,840, WBC 80, Polys 86%, Lymphs 8% Monos 2%, Glu 71, Cl 119, Protein 50, LDH 88, Toxo IgG AB (-), CMV AB (-); CSF viral culture negative after 7 days. CSF cytology negative for malignant cells. The patient's condition underwent rapid deterioration: she suffered seizures, decline in vision, quadriplegia, and expired 20 days after admission.

Guest: Dr. Archinto Anzil Host: Dr. Roger Kula

Case #2

A 58 year old black female complaining of diffuse weakness of proximal and distal arm muscles and left deltoid associated with proximal leg weakness, difficulty in standing up from chair and occasional falls. Past medical history of hemithyroidectomy for colloid goiter. EMG studies show selective right tibial motor neuropathy and suggestion of mild asymmetric sensory motor neuropathy. Blood chemistry shows a CPK of 398 (normal 0-225) and LDH of 25. A biopsy of left thigh was performed.

Guest: Dr. Yale Rosen Host: Dr. Richard Alexis

Case #3

A 49 year old Hispanic male admitted for non-specific epigasttric pain, weight loss and ascites. Past medical history revealed severe hypertension. Patient is not an alcohol abuser. CT scan showed dilated bile duct in area of pancreatic head and neck. ERCP showed obstruction of pancreatic duct proximal to head of pancreas. Normal angiogram. Laboratory parameters consistent with unresolved chronic pancreatitis. In order to rule out a pancreatitic malignancy, the patient was explored and a partial pancreatectomy was performed.

Guest: Dr. William Thelmo Host: Dr. Roosevelt Torno

Case #4

A 9 year old Arabic girl presented with a one-week history of double vision and drooping of right eyelid, accompanied by headache, nausea and vomiting. CT ad MRI showed a nasopharyngeal mass extending into the right middle cranial fossa and base of the brain. Biopsy of nasopharyngeal mass was done.

Guest: Dr. John Scholes Host: Dr. John Li

Case #5

This 53 year old presented with a long history of persistent pain and drainage of blood and mucus from the peri-rectal area. In 1991 he had I and D of bilateral perineal abscesses. Subsequently he developed recto-cutaneous fistulas treated with a diverting colostomy. When tracts continued to drain, curetting of the tracts were performed.

87

PATHOLOGISTS' CLUB
OF NEW YORK

PRESIDENT
BOYCE BENNETT, M.D.
JACK D. WEILER HOSPITAL OF
ALBERT EINSTEIN COLLEGE OF MEDICINE
1825 EASTCHESTER ROAD
BRONX, NEW YORK 10461

VICE - PRESIDENT
MARIUS P. VALSAMIS, M.D.
DEPARTMENT OF PATHOLOGY
NEW YORK MEDICAL COLLEGE
VALHALLA, NEW YORK 10595

SECRETARY TREASURER
FRED B. SMITH, M.D.
DEPARTMENT OF PATHOLOGY
ST. VINCENT'S HOSPITAL
153 WEST 11TH STREET
NEW YORK, NY 10011

MINUTES OF MEETING

THE LONG ISLAND COLLEGE HOSPITAL
THURSDAY, JUNE 3, 1993

Dr. John Li, the host for this meeting, welcomed the members and guests to this meeting of the Club, the first ever held at Long Island College Hospital. He provided a brief, illustrated history of this institution, the site of the first hospital-based medical college in the country--the forerunner of the present S.U.N.Y.-Downstate Medical Sciences Center--and of the laboratory where Dr. Jean Oliver spent most of his career.

Dr. Richard Alexis chaired the case presentations of the Scientific Session that followed; at the meeting, Cases 1 and 2 were presented in the reverse order.

Case 1. Invited discussant: Dr. Peter Farmer, North Shore University Hospital
Host discussant: Dr. Y. F. Ku

SMALL CELL MALIGNANCY OF MENINGES (?LYMPHOMA ?PNET)

The patient was a 16 year old girl with a devastating illness of the CNS, which began with headache, vomiting, and lower limb weakness, progressed to seizures, visual loss and quadriplegia, and led to her death 20 days later. The CSF showed no evidence of infection or malignant cells, and CT scan of the head did not show tumor. Discussion centered on the findings in an autopsy section of the spinal cord, in which a leptomeningeal infiltrate of cytologically malignant "small round blue cells" was evident. Dr. Farmer reviewed the differential diagnostic possibilities for the general group of small round cell tumors of childhood, and of those originating in the CNS. The histochemical features (LCA, vim, and PAS negative, synaptophysin positive) suggested a primitive neuroectodermal nature of the cell population. In this clinical setting, the most likely primitive neuroectodermal tumor (PNET) would be a medulloblastoma. However, the lack of a demonstrable cerebellar mass on the CT study was problematic.

Dr. Ku had interpreted the process as a primary meningeal lymphoma. He illustrated the gross appearance of the CNS at autopsy (no significant findings were seen in other organs.) There was no gross parenchymal mass, and thickening of the meninges was widespread, most marked over the hippocampal gyrus. The appearance of the cellular infiltrate was similar in all the sites sampled to that in the cord section, although in some areas there was subpial and vascular invasion. The cells demonstrated staining for CD3, but other markers for lymphoma had not been investigated. The findings in Dr. Farmer's laboratory (LCA-, synaptophysin+), as well as the negative CSF cytologic studies during life, seemed to leave many in the audience unsettled about the diagnosis of lymphoma.

References: Lechance OH, et al: Primary leptomeningeal lymphoma. Report of 9 cases with diagnosis by immunocytochemical analysis. Neurol 41:95(1991)
Diaz-Anastasia R, et al: Neurolymphomatosis. A clinopathologic syndrome reemerges. Neurol 42:1136(1992)
Jiddam N, et al: Intracranial malignant lymphoma. Report of 30 cases and review of the literature. J Neurosurg 65:592(1986)

Case 2. Invited discussant: Dr. Archinto Anzil, Kings County Hospital Center
Host discussant: Dr. Roger Kula

INCLUSION BODY MYOSITIS

A 58 year old black woman with progressive muscle weakness in the proximal and distal arms and proximal legs, electromyographic evidence of sensorimotor neuropathy, and moderate CPK elevation, underwent biopsy of left thigh muscle. Both discussants concurred that the histologic findings were diagnostic of inclusion body myositis. Dr. Anzil demonstrated sarcoplasmic vacuoles rimmed with basophilic material (known to be phospholipid by e.m. studies) which are demonstrable in this disease only on cryostat sections (members had been provided with a kodachrome illustration.) On paraffin sections, the sarcoplasm contained eosinophilic inclusions, which stained positively for ubiquitin, as well as the vacuoles. Other histologic features included variability in fiber size, small group atrophy, and an inflammatory infiltrate comprised predominantly of lymphocytes. The differential considerations in a muscle biopsy with these inflammatory changes include dermatomyositis and polymyositis, in addition to inclusion body myositis; the former is easily excluded in this case by the absence of a skin rash, the latter by the presence of the inclusions. Dr. Kula added further comments and illustrations of the morphologic aspects of the disease, particularly the ultrastructural changes, and discussed the clinicopathologic features in the series of 15 patients which has been followed at LICH and Downstate over a number of years.

References: Askanas V, et al: Light and electron microscopic localization of B-amyloid protein in muscle biopsies of patients with inclusion body myositis. Am J Pathol 141:31(1992)
Mendell JR, et al: Amyloid filaments in inclusion body myositis: Novel findings provide insight into nature of filaments. Arch Neurol 48:12(1991)

Case 3. Invited discussant: Dr. Yale Rosen, Winthrop University Hospital
Host discussant: Dr. Richard Alexis

ISCHEMIC PANCREATITIS SECONDARY TO HYPERTENSIVE ARTERIOPATHY

The specimen considered in this case was a portion of the pancreas removed from a 49 year old man with clinical evidence of chronic pancreatitis and radiological evidence of proximal obstruction of the pancreatic and common bile ducts. The patient had a history of severe hypertension and he had not abused alcohol. The pancreatectomy was performed because of the surgeon's concern about a neoplasm, in spite of the lack of evidence of tumor on radiographic studies and negative intraoperative frozen section examination. Dr. Rosen illustrated the histologic features in slides from the specimen, which consisted of pancreatic parenchyma with the fibroinflammatory changes of chronic pancreatitis, small pale cells scattered among acini which he interpreted as degranulated acinar epithelium, and extensive obliterative intimal fibrosis and medial hyperplasia of small arteries and arterioles

consistent with hypertensive arteriopathy. The ducts contained hyperplastic epithelium, but there was no evidence of neoplasm. He interpreted the changes as those of chronic pancreatitis caused by ischemia, and suggested the hypertensive vascular obliteration as the basis of the ischemia. Dr. Alexis concurred in this interpretation, and both discussants commented on the clinicopathologic aspects of ischemic pancreatitis, an entity not represented very extensively in the pathology literature. (Dr. Alexis's diagnosis differed slightly from Dr. Rosen's, in that he considered some of the nongranulated cell population to represent nesidioblastosis.)

References: Dreiling DA, et al: Vascular pancreatitis. A clinical entity of growing importance. J Clin Gastroenterol 10:3(1988)
Prinz RA: Mechanisms of acute pancreatitis. Vascular etiology. Int J Pancreatology 9:31(1991)

Case 4. Invited discussant: Dr. William Thelmo, Woodhull Medical and Mental Health Center
Host discussant: Dr. Roosevelt Torno

NASOPHARYNGEAL CARCINOMA (EBV-ASSOCIATED) IN A CHILD

Both of the discussants agreed that the histologic findings in this biopsy of a nasopharyngeal mass in a 9 year old girl of Arab extraction were diagnostic of nonkeratinizing squamous cell carcinoma. Dr. Thelmo pointed out the sheets of neoplastic spindle cells infiltrating respiratory mucosa and reviewed the differential diagnosis of spindle/polygonal cell tumors (rhabdomyosarcoma, melanoma, and undifferentiated, adeno- and squamous cell carcinoma) and small cell tumors (neuroblastoma, neuroendocrine carcinoma, lymphoma, and rhabdomyosarcoma) in this region. He concluded that the histochemical findings (CK+, S100-, LCA-, desmin-), as well as the histologic appearance were diagnostic of nonkeratinizing carcinoma. Dr. Torno showed the CT scan appearance of the tumor, which had extended into the right middle cranial fossa and base of the brain, electron micrographs demonstrating tonofilaments and desmosomes in the tumor cells, and in-situ hybridization preparations positive for EB virus RNA. He reminded us that nasopharyngeal carcinoma, although seen most commonly in adults, also occurs in childhood, and is the second most prevalent nasopharyngeal tumor in this age group.

References: Shanmugaratnam K, et al: Histopathology of nasopharyngeal carcinoma. Correlations with epidemiology, survival rates and other biological characteristics. Cancer 44:1029(1979)
Carbone A, Micheau C: Pitfalls in microscopic diagnosis of undifferentiated carcinoma of nasopharyngeal type (lymphoepithelioma). Cancer 50:1344(1982)

Case 5. Invited discussant: Dr. John Scholes, New York University Medical Center
Host discussant: Dr. John Li

MUCINOUS ADENOCARCINOMA ASSOCIATED WITH ANAL FISTULA
(?PRIMARY ANAL DUCT OR GLAND CARCINOMA)

Discussions in this case centered upon the interpretation of the changes present in tissue fragments curetted from persistent recto-cutaneous fistulas in a 53 year old man. Dr. Scholes analyzed the various components of the specimen, fragments of hemorrhagic exudate and debris, inflamed granulation tissue, strips of epithelium, and masses of mucin with embedded epithelial cells and clusters. He pointed out the abnormal cytologic appearance of the epithelial cells in the latter fragments; the cells were not the usual large bowel enterocyte population with

mixed goblet/absorptive components, but were comprised entirely of tall columnar mucinous cells, growing in focally complex, and sometimes papillary arrangements. The nuclei were atypical and frequently pseudostratified, and he felt that abnormalities were sufficiently severe and extensive to warrant a diagnosis of malignancy. He reviewed the differential diagnosis of neoplastic, as well as non-neoplastic processes manifested as anorectal-cutaneous fistulas, and narrowed the possibilities in this case to carcinoma of anal duct or glands, perforating or fistulizing mucosal carcinoma, carcinoma arising in a fistula, and the vanishingly rare carcinoma metastatic to a pre-existing fistula. Dr. Li concurred in the diagnosis of mucinous adenocarcinoma associated with a fistula, although he revealed that the members of his department had been reluctant to make a firm diagnosis of carcinoma on the basis of the curettings reviewed here. The patient subsequently underwent an A-P resection of the anorectum, in which the presence of carcinoma was confirmed. He showed the gross appearance of the resected specimen, in which there was no mucosal mass; tumor was demonstrated histologically in the mucinous cysts which were present beneath fistulous openings on the mucosal surface. He felt that the clinical, gross and microscopic features were most consistent with primary anal gland or duct carcinoma, although the site of origin could not be demonstrated in sections.

Reference: Onerheim RM: A case of perianal mucinous adenocarcinoma arising in a fistula-in-ano. Am J Clin Pathol 89:809(1988)

Fenoglio-Preiser CM, et al: Gastrointestinal Pathology. An atlas and text. New York, Raven Press, 1989, 831-2

Respectfully submitted,

Fred B. Smith, M.D.
Secretary-Treasurer

****

FORTHCOMING MEETING: OCTOBER 7, 1993--OUR LADY OF MERCY MEDICAL CENTER