CASE HISTORIES FOR LYMPH NODE WORKSHOP

Case 1. Pt. is a 41-year-old female with cervical and inguinal adenopathy. She has no constitutional symptoms but has a widened mediastinum on chest X-ray.

Case 2. Patient is a 49-year-old female with axillary, supraclavicular, and cervical adenopathy for 18 months. She is otherwise asymptomatic.

Case 3. The patient is a 29-year-old male who presented with painless axillary adenopathy. He is otherwise asymptomatic.

Case 4. The patient is a 62-year-old female with generalized lymph adenopathy for one year. The section is from a right supraclavicular lymph node which has been enlarging for the past year.

Case 5. The patient is a 51-year-old male who has a "clinically malignant" gastric ulcer. The section is taken from the omentum at the time of exploration.

Case 6. The patient is a 76-year-old female with anorexia, fever, night sweats, and a palpable epigastric mass. Sections are from a lymph node in the region of the porta hepatis.

Case 7. The patient is a 13-year-old girl with a left cervical mass. A biopsy was performed.

Case 8. The patient was a 20-year-old male who had received a renal transplant and was on immunosuppression when he became progressively weak and febrile. Terminally he developed massive generalized adenopathy and died after 10 days of illness.

Case 9. The patient is a 56-year-old male with inguinal and retroperitoneal adenopathy. An upper GI study shows a retroperitoneal mass involving the stomach.

Case 10. 8-year-old girl. Presented 6 months ago with cervical, submandibular and mediastinal lymphadenopathy, hepatomegaly and splenomegaly. Cutaneous lesions, pink bluish and slightly elevated, were present on the extensor surfaces of the lower legs. Moderate leukopenia and relative monocytosis (10-20%) in peripheral blood; normal bone marrow and serum proteins. A cervical lymph node biopsy was diagnosed as histiocytic medullary reticulosis. The histiocytes contained abundant fat (by Sudan IV) but no PAS-positive material. Therapy with Vincristine and Endoxan was begun. The patient is doing very well; the enlargement of lymph nodes, liver and spleen receded markedly, like the cutaneous manifestations. The monocytosis persists.

Case 11. The patient is a 71-year-old male with axillary and inguinal adenopathy.

DIAGNOSES FOR ASPEN LYMPH NODE WORKSHOP

CASE 1. (UH77-1067) - Hodgkin's disease, nodular sclerosis

CASE 2. (UH76-1886) - Malignant lymphoma, nodular, poorly differentiated lymphocytic

CASE 3. (2150B-5,6) - Hodgkin's disease, lymphocyte predominance

CASE 4. (UH76-6196) - Malignant lymphoma, diffuse, well differentiated lymphocytic

CASE 5. (UH76-6596) - Malignant lymphoma, histiocytic

CASE 6. (UH77-2435) - Hodgkin's disease, lymphocyte depletion

CASE 7. (UH76-6543) - Hodgkin's disease, mixed cellularity

CASE 8. (A76-234) - "Post-transplant lymphoma"

CASE 9. (UH74-5890) - Metastatic carcinoma

CASE 10. (SHML #40) - Sinus histiocitosis with massive lymphadenopathy

CASE 11. (UH76-1212) - Dermatopathic lymphadenitis

CASE 1. - HODGKIN'S DISEASE
NODULAR SCLEROSIS

HODGKIN'S DISEASE, NODULAR SCLEROSIS	23
HODGKIN'S DISEASE, MIXED CELLULARITY	1
LYMPHADENITIS/REACTIVE	2
IMMUNOBLASTIC LYMPHADENOPATHY	1

CASE 2 - MALIGNANT LYMPHOMA, NODULAR, POORLY DIFFERENTIATED LYMPHOCYTIC

ML, NODULAR, PDL	17
ML, WDL	7
IMMUNOBLASTIC LYMPHADENOPATHY	1

CASE 3 - HODGKIN'S DISEASE, LYMPHOCYTE PREDOMINANCE

HODGKIN'S DISEASE, LP	6
ML, DIFFUSE	10
ML, NODULAR	4
REACTIVE/HYPERPLASTIC	6
VIRAL LYMPHADENITIS	1

CASE 4 - MALIGNANT LYMPHOMA, DIFFUSE, WELL DIFFERENTIATED LYMPHOCYTIC

ML, DIFFUSE, WDL	17
ML, DIFFUSE, MIXED	3
ML, DIFFUSE, PDL	3
HODGKIN'S DISEASE, L&H	1
HAIRY CELL LEUKEMIA	1
METASTATIC CARCINOMA	1

CASE 5 - MALIGNANT LYMPHOMA, HISTIOCYTIC

ML, HISTIOCYTIC	17
ML, PDL	5
METASTATIC CARCINOMA	3
IMMUNOBLASTIC SARCOMA	1

CASE 6 - HODGKIN'S DISEASE, LYMPHOCYTE DEPLETION

HODGKIN'S DISEASE, LD	17
HODGKIN'S DISEASE, MIXED	6
ML, HISTIOCYTIC	2
HODGKIN'S DISEASE, LP	1
HISTIOCYTIC MEDULLARY RETICULOSIS	1

CASE 7 - HODGKIN'S DISEASE, MIXED CELLULARITY

HODGKIN'S DISEASE, MIXED	14
HODGKIN'S DISEASE, LP	8
HODGKIN'S DISEASE, NS	1
REACTIVE	2
ML, MIXED	1
IMMUNOBLASTIC LYMPHADENOPATHY	1

CASE 8 - "POST-TRANSPLANT LYMPHOMA"

ML, HISTIOCYTIC	6
MALIGNANT HISTIOCYTOSIS	3
LEUKEMIC INFILTRATE	3
IMMUNOBLASTIC SARCOMA	2
HISTOPLASMOSIS	2
PNEUMOCYSTIS	2
TOXOPLASMOSIS	1
INFECTIOUS MONONUCLEOSIS	1
ML, PDL	1
CMV	1
GRANULOCYTIC SARCOMA	1
REACTIVE/INFECTIOUS	2
UNDIFFERENTIATED TUMOR	1

CASE 9 - METASTATIC ADENOCARCINOMA

ML, HISTIOCYTIC	9
ML, PDL	7
ADENOCARCINOMA	7
CARCINOID	1
HAIRY CELL LEUKEMIA	1
MALIGNANT HISTIOCYTOSIS	1

CASE 10 - S.H.M.L.

S.H.M.L.	7
MAL. HISTIOCYTOSIS/H.M.R.	5
DON'T KNOW	4
GAUCHER	3
HISTIOCYTOSIS X	2
TOXOPLASMOSIS	1
RETICULOHISTIOCYTOMA	1
CHRONIC GRANULOMATOUS DISEASE	1
ML, HISTIOCYTIC	1
DERMATOPATHIC LYMPHADENITIS	1

CASE 11 - DERMATOPATHIC LYMPHADENITIS

REACTIVE/HISTIOCYTOSIS	17
IMMUNOBLASTIC LYMPHADENOPATHY	3
DERMATOPATHIC LYMPHADENOPATHY	2
CASTLEMAN'S DISEASE	1

HODGKIN'S DISEASE

Juan Rosai, M.D.

Hodgkin's disease can be defined as a type of malignant lymphoma characterized by the presence of Reed-Sternberg cells in the proper architectural background. It is important to emphasize that both Reed-Sternberg cells and the proper background are needed in order to designate a particular type of lymphoma as Hodgkin's disease. The diagnostic Reed-Sternberg cell has a lobulated nucleus or multiple nuclei. The lobes or individual nuclei contain large homogeneous acidophilic nuclei. These nuclei often are at least one fourth of the nucleus or lobe. The cytoplasm is generally amphophilic and stains strongly with methyl green pyronin. Several variants of the Reed-Sternberg cells have been described. These are the lacunar cells of nodular sclerosing Hodgkin's disease, the folded and lobulated cells of the lymphocytic and histiocytic type and the pleomorphic variant of the reticular type.

Hodgkin's disease characteristically involves lymphoid organs and structures. The frequency of extranodal involvement by Hodgkin's disease, particularly as an initial manifestation of the disease, is less common for Hodgkin's disease then for any other malignant lymphoma. The early involvement of lymph nodes and other lymphoid structures by Hodgkin's disease is often in the T-related areas, suggesting that this disease primarily involved structures related with cellular rather than humoral immunological responses.

The first important classification of Hodgkin's disease based on morphological grounds was that of Jackson and Parker. They divided this condition into granuloma, paragranuloma and sarcoma. These groups were prognostically significant. However, the value of their classification was limited by the fact that the two prognostically significant groups, paragranuloma and sarcoma, together comprised only about 10% of the cases. Smetana added a nodular sclerosis type to the Jackson and Parker classification. In 1966 Lukes and Butler proposed a different classification based on the predominant histologic features of pretherapy lymph node biopsies. The types described reflected the importance of lymphocytic proliferation, the relationship between lymphocytes and diagnostic Reed-Sternberg cells and the presence of two different types of connective tissue proliferation. The types described were: lymphocytic and histiocytic nodular, lymphocytic and histiocytic diffuse, mixed cellularity, nodular sclerosis, reticular and diffuse fibrosis.

The proposal was used as a basis for the currently used classification of Hodgkin's disease, which was agreed upon at a meeting on Hodgkin's disease held in Rye, New York. The Rye classification consists of four types which are: nodular sclerosis, lymphocyte predominance, lymphocyte depletion and mixed cellularity. It is important to emphasize that nodular sclerosis, lymphocyte depletion and lymphocyte predominance probably represent homogeneous subtypes whereas mixed cellularity represents a heterogeneous group of cases which does not fit into any of the previous three groups.

The main features of the lymphocyte predominant type are: large number of lymphocytes, some of which may appear immature, scarcity of diagnostic Reed-Sternberg cells and paucity or absence of esinophiles, plasma cells and fibrosis. The nodular sclerosis type is characterized by collagen septae in different stages of development and the presence of the lacunartype of Reed-

Sternberg cells. We like to restrict the term nodular sclerosis to cases of Hodgkin's disease in which neoplastic lobules are formed by collagen fibrils which surrounds them entirely. The concept of a cellular phase of nodular sclerosis in Hodgkin's disease, in which the diagnosis is based almost solely on the presence of lacunar cells in the absence of fibrosis, is probably valid but one in which no total assurance is possible at the present time. In the mixed cellularity type, large variety of cells are present. Another important feature is the fact that diagnostic Reed-Sternberg cells should be easily found. A case in which many diagnostic Reed-Sternberg cells are present should be classified as mixed cellularity, even if the background is one of a predominantly lymphocytic type. The lymphocyte depletion group includes the diffuse fibrosis and reticular types of the classification of Lukes and Butler. In the diffuse fibrosis type, the number of lymphocytes and other cells progressively decreases. The reticular type is characterized by increased number of diagnostic Reed-Sternberg cells and considerably fewer lymphocytes. Areas of necrosis are common. In some cases, the Reed-Sternberg cells are pleomorphic and often bizarre, whereas in other cases they are not. One should be careful not to confuse a case of nodular sclerosis Hodgkin's disease exhibiting focal aggregation with lacunar cells with a lymphocyte depletion Hodgkin's disease.

Once the diagnosis of Hodgkin's disease has been made on the basis of diagnostic Reed-Sternberg cells, involvement by Hodgkin's disease in the same patient of another organ is allowed in the presence of a lymphoid infiltrate with atypical mononuclear cells (so-called Hodgkin's cells), even in the absence of diagnostic Reed-Sternberg cells.

The two microscopic types with better prognosis are lymphocyte predominance and nodular sclerosis. The worst prognosis is represented by lymphocyte depletion, mixed cellularity being intermediate. These differences, which were quite marked a few years ago, are now progressively becoming less and less important because of improved methods of therapy. At the present time, lymphocyte depletion still carries a bad prognosis but the other three microscopic types carry a very similar prognosis.

A definite relation exists between microscopic types of Hodgkin's disease and clinical features. Nodular sclerosis involves the mediastinum more commonly then all the other types combined. It is the type most affecting the lungs and is the type most prevalant in women. Also it has a very predictable pattern of spread. On the other hand, lymphocyte depletion is the one most commonly involving the abdominal cavity at the time of the first observation. It is most likely to present with widespread invasion of the bone marrow, whereas peripheral lymphadenopathy can be minimal or absent.

The diagnosis of Hodgkin's disease should be seriously doubted in lymphomas involving the Waldeyer's ring, the skin and the gastrointestinal tract, especially if this happens to be the first manifestation of the disease. A diagnosis of Hodgkin's disease should also be viewed with suspicion if it presents as a complication of a immune deficiency, immunosuppression, or other immune disease. Most of these cases actually represent immunoblastic sarcomas containing with binucleated immunoblasts morphologically similar to Reed-Sternberg cells.

REFERENCES

Berard, C.W.: Synthesis and implication for the etiology, pathogenesis and spread of Hodgkin's disease. Natl. Cancer Inst. Monogr. 36:261-263, 1973.

Butler, J.J.: Relationship of histological findings to survival in Hodgkin's disease. Cancer Res. 31:1770-1775, 1971.

Dorfman, R.F.: Relationship of histology to site in Hodgkin's disease. Cancer Res. 31:1786-1793, 1971.

Lukes, R.J., and Butler, J.J.: The pathology and nomenclature of Hodgkin's disease. Cancer Res. 26:1063-1081, 1966.

Lukes, R.J., Craver, L.F., Hall, T.C., Rappaport, H., and Ruben, P.: Report of the nomenclature committee. Cancer Res. 26:1311, 1966.

Neiman, R.S., Rosen, P.J., and Lukes, R.J.: Lymphocyte depletion Hodgkin's disease. A clinicopathological entity. N. Engl. J. Med. 288:751-755, 1973.

Strum, S.B., Park, J.K., and Rappaport, H.: Observation of cells resembling Sternberg-Reed cells in conditions other than Hodgkin's disease. Cancer 26:176-190, 1970.

Strum, S.B. and Rappaport, H.: Significance of focal involvement of lymph nodes for the diagnosis and staging of Hodgkin's disease. Cancer 25:1314-1319, 1970.

Strum, S.B., and Rappaport, H.: Consistency of histologic subtypes in Hodgkin's disease in simultaneous and sequential biopsy specimens. Natl. Cancer Inst. Monogr. 36:253-260, 1973.

Thomas, L.B., and Berard, C.W.: Hodgkin's disease: relationship of histopathological type at diagnosis of clinical parameters and to histological progression and anatomical distribution at autopsy. In Malignant Diseases of the Hematopoietic System, Gann Monograph on Cancer Research No. 15, ed. by Akazaki, K., Rappaport, H., Berard, C.W., Bennett, J.M., and Jshikawa, E., pp. 253-273. Tokyo, University of Tokyo Press, 1973.

BENIGN LYMPHADENOPATHY SIMULATING LYMPHOMA

Juan Rosai, M.D.

Antigenic stimulus to a lymph node results in the appearance of anatomic changes in one or more of the lymph node structures, this leading to recognizable and reproduceable histologic patterns. They are of importance not only because they can provide a clue as to the etiologic organism but also because they can be confused on morphologic grounds with malignant lymphoma. The basic morphologic patterns of a stimulated lymph node can be divided in four major categories: the follicular (nodular pattern), the sinus pattern, the diffuse pattern, and the mixed pattern.

Follicular (nodular) pattern.

This type of reaction can be confused with follicular (nodular) lymphoma because large, closely packed, lymphoid follicles are seen throughout the cortex and medulla compressing and obliterating the sinuses. Rappaport laid down some years ago the key microscopic features that differentiate these two processes. The most important are the following: reactive lymphoid follicles vary greatly in size and shape, are concentrated in the cortical region, are composed of an admixture of small and large lymphoid cells, contain a variable but a usually large number of macrophages containing nuclear debris and mitoses are numerous. In contrast, follicular lymphoma is characterized by nodules of similar size and shape, uniformly distributed throughout the nodes, without phagocytosis of nuclear debris, with peripheral fading and occasional coalescence of the nodules and extension into the capsule and perinodal tissues.

Conditions that are associated with the follicular (nodular) reactive pattern include: non-specific reactive follicular hyperplasia; secondary syphilis; rheumatoid arthritis, including Felty syndrome and Still's disease; and giant lymph node hyperplasia (Castleman's disease).

Sinus pattern.

This is characterized by distention of the sinuses, which contain a large number of activated cells, including lymphocytes, plasma cells, immunoblasts and histiocytes. The type of lymphoreticular malignancy with which this pattern is often confused is malignant histiocytosis (histiocytic medullary reticulosis). Features that in a particular case favor a diagnosis of malignant histiocytosis over one of sinus hyperplasia include: presence of cytologically atypical histiocytes within subcapsular or medullary sinuses; evidence of erythrophagocytosis; proliferation of discrete cells which are not organized in cohesive cell masses.

Conditions that can result in the sinus pattern of lymphoid hyperplasia include: histiocytosis X; sinus histiocytosis with massive lymphadenopathy; lymphoma-like Kaposi's sarcoma; vascular transformation of sinuses; lymphangiogram effect; and metastatic tumor (particularly carcinoma and melanoma).

Diffuse pattern.

This results in a partial or total effacement of the architecture by diffuse proliferation of cells. The most prominent among these are large lymphoid cells (immunoblasts). These are activated lymphocytes of either T or B line which are

characterized by a slightly eccentric nucleus, perinuclear clear halo and amphophilic or basophilic cytoplasm which is strongly pyroninophilic. They result in a mottled appearance to the lymph node. On occasion, they can be binucleated and thus simulate the Reed-Sternberg cells of Hodgkin's disease. The blood vessels are very prominent in this pattern of reaction.

Diseases associated with a diffuse pattern of lymph node hyperplasia include: post vaccinal lymphadenitis; hydantoin (Dilantin) hypersensitivity; viral (Herpes-Zoster) lymphadenitis; immunoblastic lymphadenopathy; lupus erythematosus; and metastatic tumor (especially carcinoma and melanoma).

Mixed pattern.

This refers to a combination of follicular, sinus and diffuse patterns. The most important disease which results in this type of lymph node proliferation is infectious mononucleosis. This is probably the single most common reactive lymph node condition that is confused pathologically with malignant lymphoma. Other diseases characterized by mixed pattern of growth are toxoplasmosis; cat scratch disease; lymphogranuloma inguinale; and metastatic tumor (especially carcinoma and melanoma).

The differential diagnosis between malignant lymphoma and the above listed reactive proliferations of lymph nodes are mainly based on careful evaluation under a light microscope of well fixed, well embedded, well cut and well stained H&E sections. Special techniques that may prove of some value in an occasional case include: methyl green pyronin stain; reticulin stain; melanin and mucin stain; chromosomal studies on a fragment of lymph node; determination of markers for T lymphocytes, B lymphocytes and histiocytes on cell suspension from the lymph node; immunoperoxidase stains for immunoglobulins and histiocytic enzymes using the bridge (PAP) technique; and electron microscopy. In some cases, a definite differential diagnosis will not be possible even after performing this battery of procedures. Under such circumstances, it is always better to be on the conservative side and designate the lymph node change as atypical lymphoid hyperplasia. This diagnosis relays a definite message to the clinician: it tells him that the pathologist is seeing in the lymph node a very florid proliferation or lymphoid elements which either simulates malignant lymphoma, may be precursor of a malignant lymphoma or may even be the expression of an early stage of malignant lymphoma. The recommendation under these circumstances is for the physician to also adopt a conservative attitude, give only supportive symptomatic therapy if needed and follow closely the patient for the possible development of an obvious malignancy. It has been shown on many occasions that if the patient has indeed a lymphoma, this diagnosis will become obvious within six months in the overwhelming majority of the cases. It is very unlikely that this delay will affect significantly the evolution of the disease.

It seems clear that in the majority of cases in which an atypical proliferation of lymphoid cells is present in the lymph node, this represents either a reactive process or a malignant disease. However, it is becoming increasingly evident that in exceptional instances the group of diseases resulting in lymph node hyperplasia may actually induce the appearance of a malignant lymphoma, perhaps as a result of persistent immunologic stimulation. The oncogenic effect of such a stimulation has been demonstrated in experimental conditions. An increased incidence of lymphoma has been reported in rheumatoid arthritis, anti-convulsivant therapy, lupus erythematosus and Sjögren's syndrome.

REFERENCES

Berard, C.W., and Dorfman, R.F.: Histopathology of malignant lymphomas. Clin. Hematol. In press.

Butler, J.J.: Non-neoplastic lesions of lymph nodes of man to be differentiated from lymphomas. Nat. Cancer Inst. Monogr., 32:233-255, 1969.

Cottier, H., Turk, J., and Sobin, L.: A proposal for a standardized system of reporting human lymph node morphology in relation to immunological function. Bull. WHO, 47:375-408, 1972.

Dorfman, R.F., and Remington, J.S.: Value of lymph node biopsy in the diagnosis of acute acquired toxoplasmosis. New Eng. J. Med., 289:878-881, 1973.

Dorfman, R.F., and Warnke, R.: Lymphadenopathy simulating the malignant lymphomas. Human Pathol., 5:519-550, 1974.

Frizzera, G., Moran, E.M., and Rappaport, H.: Angio-immunoblastic lymphadenopathy; diagnosis and clinical course. Am. J. Med., 59:803-818, 1975.

Haferkamp, O., Rosenau, W., and Lennert, K.: Vascular transformation of lymph node sinuses due to venous obstruction. Arch. Path., 92:81-83, 1971.

Hartsock, R.J.: Postvaccinial lymphadenitis. Hyperplasia of lymphoid tissue that simulates malignant lymphomas. Cancer, 21:632-649, 1968.

Hyman, G.A., and Sommers, C.: The development of Hodgkin's disease and lymphoma during anticonvulsant therapy. Blood, 28:416-427, 1966.

Keller, A.R., Hochholzer, L., and Castleman, B.: Hyaline-vascular and plasma cell types of giant cell lymph node hyperplasia of the mediastinum and other locations. Cancer, 29:670-683, 1972.

Lubin, J., and Rywlin, A.M.: Lymphoma-like lymph node changes in Kaposi's sarcoma. Arch. Path., 92:338-341, 1971.

Nosanchuk, J.S., and Schnitzer, B.: Follicular hyperplasia in lymph nodes from patients with rheumatoid arthritis. Cancer, 24:334-354, 1969.

Rappaport, H., Winter, W.J., and Hicks, E.B.: Follicular lymphoma. A reevaluation of its position in the scheme of malignant lymphoma based on a survey of 253 cases. Cancer, 9:792-821, 1956.

Rosai, J., and Dorfman, R.F.: Sinus histiocytosis with massive lymphadenopathy. A pseudolymphomatous benign disorder. Analysis of 34 cases. Cancer 30: 1174-1188, 1972.

Saltzstein, S.L., and Ackerman, L.V.: Lymphadenopathy induced by anticonvulsant drugs and mimicking clinically and pathologically malignant lymphoma. Cancer, 12:164-182, 1959.

Stansfeld, A.G.: The histological diagnosis of toxoplasmic lymphadenitis. J. Clin. Pathol., 14:565-573, 1961.

Tindle, B.H., Parker, J.W., and Lukes, R.J.: "Reed-Sternberg" cells in infectious mononucleosis? Am. J. Clin. Path., 58:607-617, 1972.

NON-HODGKIN'S LYMPHOMAS

Several major changes have taken place since Rappaport's proposed classification of the malignant lymphomas (MLs) (1956), calling for a revision of his approach, which was based purely on morphology (pattern: nodular or diffuse; cytology):

1) The apparently homogenous population of lymphocytes was shown actually to be composed of at least two cell types, B and T, with different origins, functions, and properties[1].

2) It was shown that the small lymphocyte is not an end-cell but, on the contrary, can - under appropriate stimuli - undergo morphological transformation and rapid proliferation[2]. The transformed lymphocyte, also called by Dameshek an immunoblast, can be as large as the normal histiocyte and very similar microscopically to it. Thus it turned out that the vast majority of Rappaport's histiocytic MLs do not possess the markers of the histiocytes, but those of the lymphocytes B[3-4] or no markers at all[5].

3) Cytochemical, ultrastructural[6] and immunological evidence has established that the "nodular" lymphomas are neoplasms of germinal center origin, hence the name of "follicular" was proposed for them instead.

4) New types of lymphomas have been recognized, which have a distinct cytology and apparently also a definite relation to the immunologic compartments of the lymphoid system: the convoluted lymphocyte lymphoma described by Barcos and Lukes[7], and the non-convoluted lymphoblastic type of Nathwani, Kim and Rappaport[8].

Among the attempts made to organize these new data in a coherent conceptual frame, two are discussed: Lukes and Collins' and the very similar scheme of Lennert[9] (Tables 1 and 2). Both aim at correlating the morphological features of the MLs with the functional characteristics of the component cells, as revealed by immunological studies.

The confusing nomenclature of the cell types of the MLs, which resulted from these and other proposals is compared in Table 3.

There is a good correlation between the cytological type of the MLs, the architectural pattern and the results of marker studies (Table 4). It appears that the small lymphocytic and the lympho-plasmacytoid types are always diffuse, never follicular. The cleaved and non-cleaved types may present with both patterns. It is usual for the small cleaved cell lymphomas, apparently composed of cells with very low mitotic rate, though very mobile, to be distinctly follicular; while the

non-cleaved cell lymphomas, composed of actively proliferating cells, tend to be more often diffuse. The lymphomas of immunoblasts and lymphoblasts are always diffuse. Malignant histiocytosis, of course, has a definite sinusal pattern, at the beginning at least.

From the results of immunological work on the MLs, it seems that some generalizations can be made concerning their origin or histogenesis (Table 4). The diffuse MLs of small and plasmacytoid lymphocytes and those composed of follicular center cells show the functional characteristics of the B cells[11]. The exceptions to this rule are represented by the small percentage of CLL bearing the markers of T-cells[12]. The lymphoblastic MLs are usually composed of T-cells[11] or, less frequently, of Null-cells[4], and the cases of malignant histiocytosis studied so far were composed of cells with the characteristics of the histiocytes[13]. There remains a large group of MLs (usually with a mixed cellular population) which appears to be very heterogeneous. No definite morphological subgroups can today be recognized within it, save for the MLs composed of a mixture of cleaved and non-cleaved cells, which are of follicular origin[11].

Recent studies have shown that, with a correct interpretation of both the architecture and the cytology of the MLs, it is possible to identify disease patterns, with distinctive clinical presentation, evolution and prognosis, diseases which therefore, have to be approached and treated differently. The clinical features of some of these better defined clinico-pathological syndromes are summarized in Table 4 and correlated with the morphological and functional data already given. These are:

1) Follicular lymphomas[14]
2) Burkitt lymphoma[15]
3) Malignant histiocytosis[16] (MH)
4) Well differentiated lymphocytic lymphoma, diffuse (ML, WDL)
5) Mycosis fungoides (MF)[17]
6) Lymphoblastic malignant lymphoma[8] (ML, Lbl) (Table 5)

Other types of malignant lymphomas, which do not fall into any of the above categories, represent a heterogeneous group, not only - as already stated - morphologically and immunologically, but also from a clinical standpoint. No definite clinico-pathological correlations have been worked out within this group. In general, they represent a worse disease than the nodular forms of corresponding cytology, with more rapid dissemination and aggressive course.

Classification. As mentioned, there are at present two morphological classifications, which - even though not yet proven useful clinically - correlate best with the information provided by the immunological studies of the MLs (Table 2): one was proposed by Lukes and Collins, the other was drawn in Kiel (Germany), in accordance with Lennert's views[18]. Table 6 compares these classifications with that of Rappaport, which, despite its theoretical drawbacks, has been shown in a number of studies to be clinically and prognostically useful.

It is apparent that, despite the different terminology, there are many similarities between the Lukes-Collins and the Kiel schemes, to the point that almost each one of the Lukes-Collins' types can be matched with one of the Kiel types. At the same time, the Table shows that almost each one of the Rappaport's types includes more than one entity in the other systems. Rappaport's classification is still probably the most used and useful both in this country and abroad, and it is doubtful that it will be discontinued, before the others can be shown to be clinically significant. It seems appropriate, however, for prospective studies and adherence to the current immunological knowledge, that the use of Rappaport's terms be associated with a comment clarifying its meaning with reference to either the Lukes-Collins' or the Kiel schemes of classification.

Additional References

1. Raff, M.D.: T and B lymphocytes and immune responses. Nature 242: 19, 1973.

2. Mellman, W.J. and Rawnsley J.M.: Blastogenesis in peripheral blood lymphocytes in response to phytohemagglutinin and antigens. Fed. Proc. 25: 1720, 1966.

3. Brouet, J.C.: Membrane markers in "histiocytic" lymphomas (reticulum cell sarcomas). J. Natl. Cancer Inst. 56: 631, 1976.

4. Braylan, R.C. et al.: Surface receptors of human neoplastic lymphoreticular cells. In Immunological Diagnosis of Leukemias and Lymphomas. Springer-Verlag, Berlin-Heidelberg-New York, pp. 47, 1977.

5. Gajl-Peczalska, K.J. et al.: B and T cell lymphomas. Analysis of blood and lymph nodes in 87 patients. Am. J. Med. 59: 674, 1975.

6. Lennert, K.: Follicular lymphoma . A tumor of the germinal centers. In Malignant Diseases of the Hematopoietic System. Gann Monograph on Cancer Research 15. University of Tokyo Press, pp. 217, 1973.

7. Barcos, M.P. and Lukes R.J.: Malignant lymphoma of convoluted lymphocytes: a new entity of possible T-cell type. In Conflicts in Childhoood Cancer. Alan R. Liss Inc., New York, pp. 147, 1975.

8. Nathwani, B.N. et al.: Malignant lymphoma , lymphoblastic. Cancer 38: 964, 1976.

9. Lennert, K.: Presented at a meeting at the Istituto Nazionale per lo Studio e la Cura dei Tumori. Milan, December 1, 1975.

10. Dorfman, R.F.: Classification of non-Hodgkin's lymphoma. Lancet i: 1295, 1974.

11. Braylan, R.C. et al. Malignant lymphomas: current classification and new observations. Path Ann. 10: 213, 1975.

12. Brouet, J.C. et al.: Chronic lymphocytic leukemia of T-cell origin. Lancet ii: 890, 1975.

13. Jaffe, E.S. et al.: Membrane receptor sites for the identification of lympho-reticular cells in benign and malignant conditions. Brit. J. Cancer 31: Suppl. II, 107, 1975.

14. Spiro, S. et al.: Follicular lymphoma: a survey of 75 cases. Brit. J. Cancer 31: Suppl. II, 60, 1975.

15. Arseneau, J.C. et al. American Burkitt's lymphoma: a clinicopathologic study of 30 cases. Am. J. Med. 58: 314, 1975.

16. Warnke, R.A. et al.: Malignant histiocytosis. I. Clinico-pathologic study of 29 cases. Cancer 35: 215, 1975.

17. Epstein, E.H. et al.: Mycosis fungoides. Survival, prognostic features, response to therapy and autopsy findings. Medicine 15: 61, 1972.

18. Gerard-Marchant, R. et al.: Classification of non-Hodgkin's lymphomas. Lancet ii: 405, 1976.

SCHEMATIC REPRESENTATION OF TRANSFORMATION OF FOLLICULAR CENTER CELLS IN STAGES

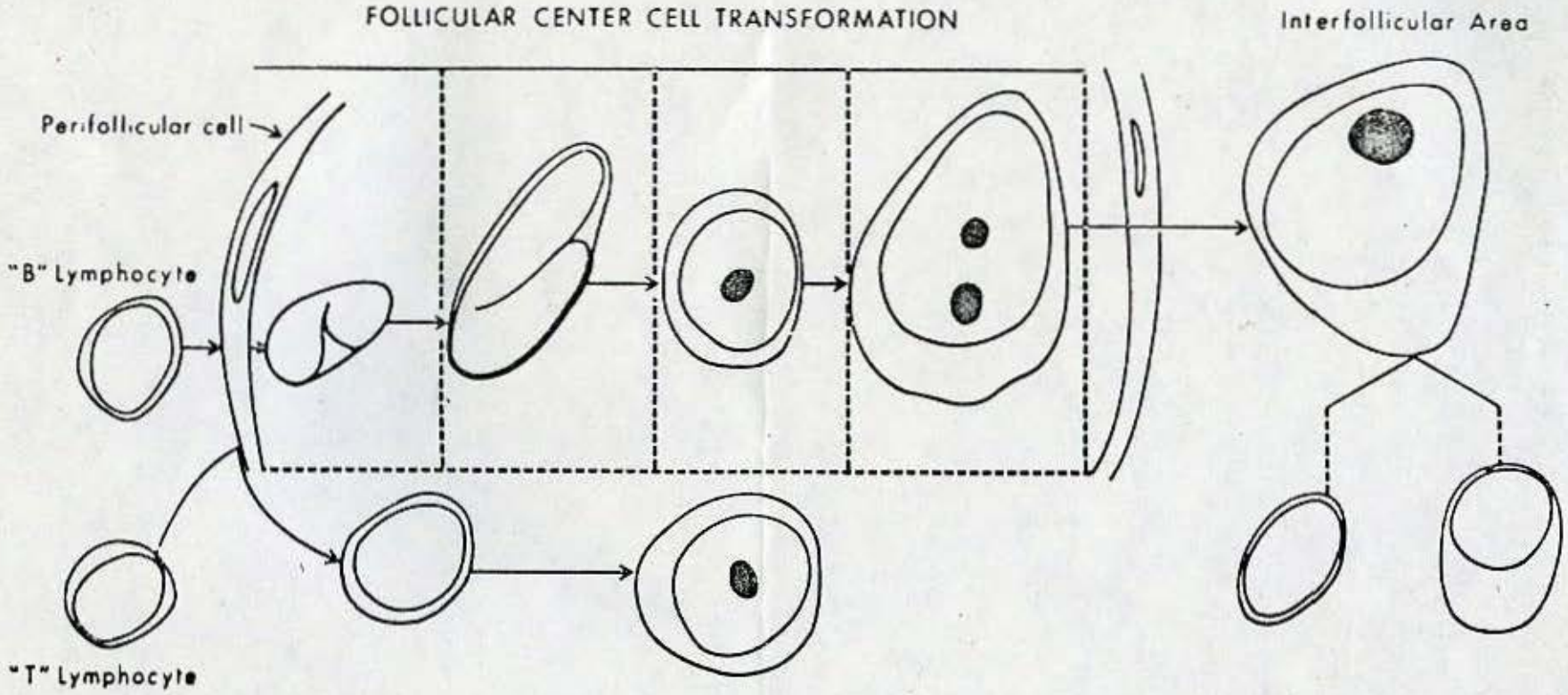

1A

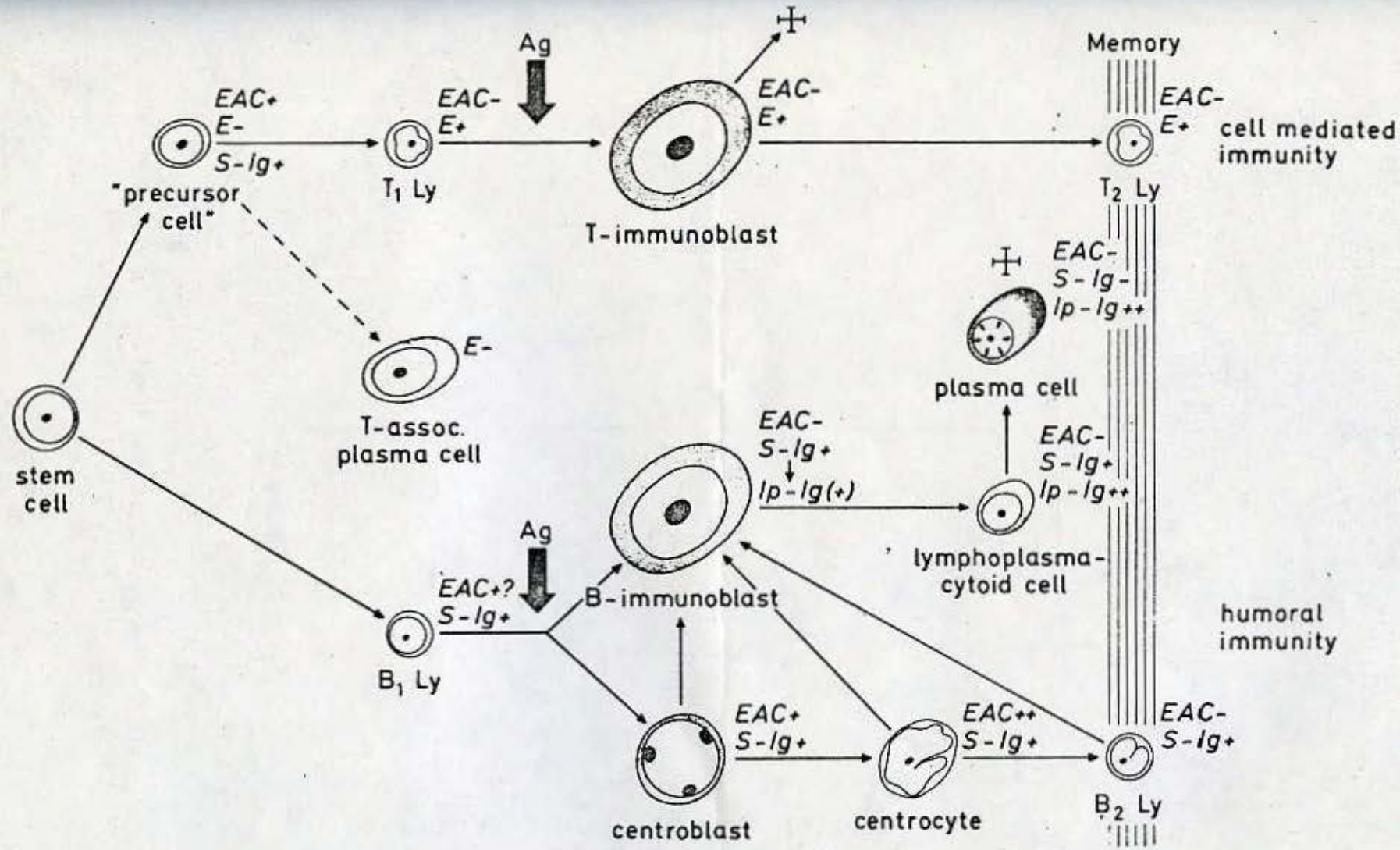
Ag
Memory
EAC+
E-
S-Ig+
"precursor cell"
EAC-
E+
T1 Ly
EAC-
E+
T-immunoblast
EAC-
E+
T2 Ly
cell mediated immunity
EAC-
S-Ig-
Ip-Ig++
plasma cell
E-
T-assoc. plasma cell
stem cell
EAC-
S-Ig+
Ip-Ig(+)
EAC-
S-Ig+
Ip-Ig++
lymphoplasma-cytoid cell
Ag
EAC+?
S-Ig+
B-immunoblast
B1 Ly
humoral immunity
EAC+
S-Ig+
EAC++
S-Ig+
EAC-
S-Ig+
centroblast
centrocyte
B2 Ly

1 B

MALIGNANT LYMPHOMAS
Lukes-Collins Classification (1974)

U cell (undefined cell) type

B cell types

- small lymphocyte (CLL)
- plasmacytoid lymphocyte
- follicular center cell types
  - cleaved, small or large
  - noncleaved, small or large
  - immunoblastic sarcoma (of B cells)

T cell types

- mycosis fungoides
- convoluted lymphocyte
- immunoblastic sarcoma (of T cells)

Histiocytic type

MALIGNANT LYMPHOMAS
Kiel Classification (1974)

LOW-GRADE MALIGNANCY

- Lymphocytic
  - CLL
  - hairy cell leukemia
  - mycosis fungoides
- Lymphoplasmacytoid (immunocytic)
- Centrocytic
- Centroblastic-centrocytic

HIGH-GRADE MALIGNANCY

- Centroblastic
- Lymphoblastic
  - Burkitt's type
  - convoluted cell type
  - others
- Immunoblastic

Malignant Lymphomas

A Dictionary of Cell Types

CELL TYPES	RAPPAPORT	LUKES-COLLINS	KIEL	DORFMAN
	WDL	Small L	L, CLL Type	Small L
	WDL with plasmacytoid features	Plasmacytoid L	Lympho-plasmacytoid cell	Small L with plasmacytoid differentiation
	PDL	Cleaved FCC	Centrocyte	Small lymphoid follic. cell (in foll. ML) Atypical small L (in diffuse ML)
	H	Noncleaved FCC	Centroblast	Large lymphoid follic. cell (in foll. ML) Large lymphoid (pyroninophilic) (in diffuse ML)
		Immunoblast B	Immunoblast B	Large lymphoid (pyroninophilic) cell
	Lbl. convoluted	Convoluted L	Lbl. convoluted	Convoluted L
	Lbl. non-convol.		Lbl. non-convol.	
	H	Immunoblast	Immunoblast	H

Malignant Lymphomas

CLINICAL SYNDROME

AGE	SYMPT.	EVOL.	DISTRIBUTION	PROGNOSIS

MLs, Follicular

Middle Old	Scarce	Slow	Visceral dissemin.	Relatively GOOD
Child	Severe	Rapid	Viscera LN	POOR

Burkitt

MH

Any	Severe	Rapid	Dissemin.	VERY POOR

PATTERN | *CYTOLOGY* | *MARKERS*

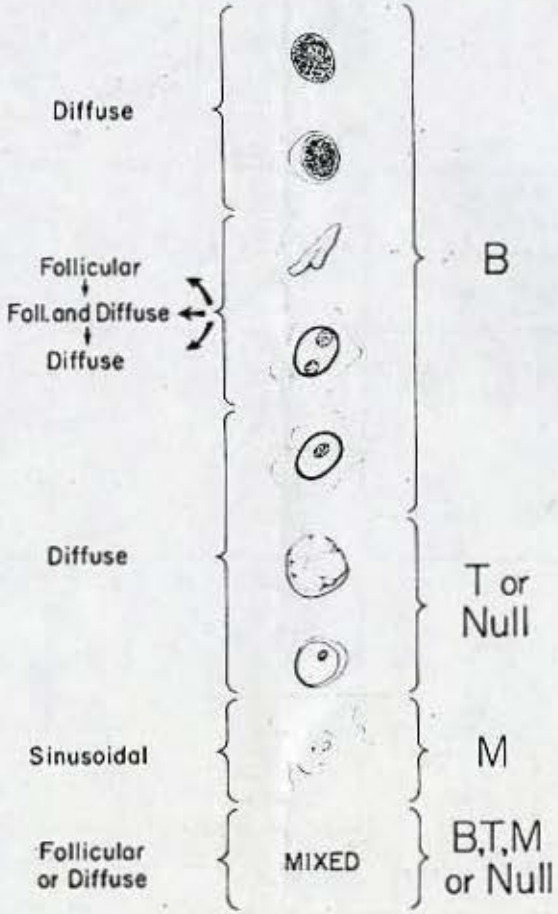

CLINICAL SYNDROME

AGE	SYMPT.	EVOL.	DISTRIBUTION	PROGNOSIS
Middle Old	Scarce	Slow	Local. (ML) Dissem. (CLL)	GOOD

ML, WDL

MF

Middle Old	Scarce	Long	Skin → diss.	POOR after tumors or diss.
Child Adol.	Severe	Rapid	Mediast. LN ↓ LEUKEMIC	VERY POOR

ML, Lbl

MALIGNANT LYMPHOMA, LYMPHOBLASTIC:

comparison with other ML of children and ALL

Type of Neoplasia	Age	Distribution						Survival: % or median
		mediast.	superf. LN	extra-nodal	spleen	b.m.	platelets at pres.	
Other ML (BURKITT'S excluded)	4 - 15 (also adults)	uncommon	20%	80% (G-I 54%)	uncommon	5%	normal	I-II: 50% III-IV: 7.7% (at 3 yrs)
ML, lymphoblastic	5 - 20 (also adults)	50%	66%	13%	7%	32% ↓ 77%	normal	8 mos. (with local therapy) 39 mos. (with systemic therapy)
ALL	70%: 2 - 10	10%	30%	uncommon	86%	100%	↓ in 90%	50% (at 5 yrs)

COMPARISON OF 3 CLASSIFICATIONS (GF 7.77)

	LUKES	RAPPAPORT: Und.	RAPPAPORT: Lbl.	RAPPAPORT: Lymph.	RAPPAPORT: Hist.	RAPPAPORT: Mixed	KIEL
B	Small lymphocyte			WDL			Lymphocyte, CLL
B	Plasmacytoid lymphocyte			WDL Pc.oid			Lympho-plasmacytoid (immunocytic)
B	FCC: Small cleaved			PDL		M	Centroblastic/centrocytic Centrocytic
B	FCC: Large cleaved				H	M	
B	FCC: Small noncleaved	U					Lymphoblastic, Burkitt's type
B	FCC: Large noncleaved				H		Centroblastic
B	FCC: Immunoblastic Sa. B				H	M	Immunoblastic
T	Mycosis fungoides			PDL,MF			Lymphocytic, mycosis fungoides
T	Convoluted lymphocyte	U	Lbl conv.	PDL			Lymphoblastic, conv. cell type
T		U	Lbl non conv.	PDL			Lymphoblastic, others
T	Immunoblastic Sa. T					M	Immunoblastic
.M	Histiocytic				H		