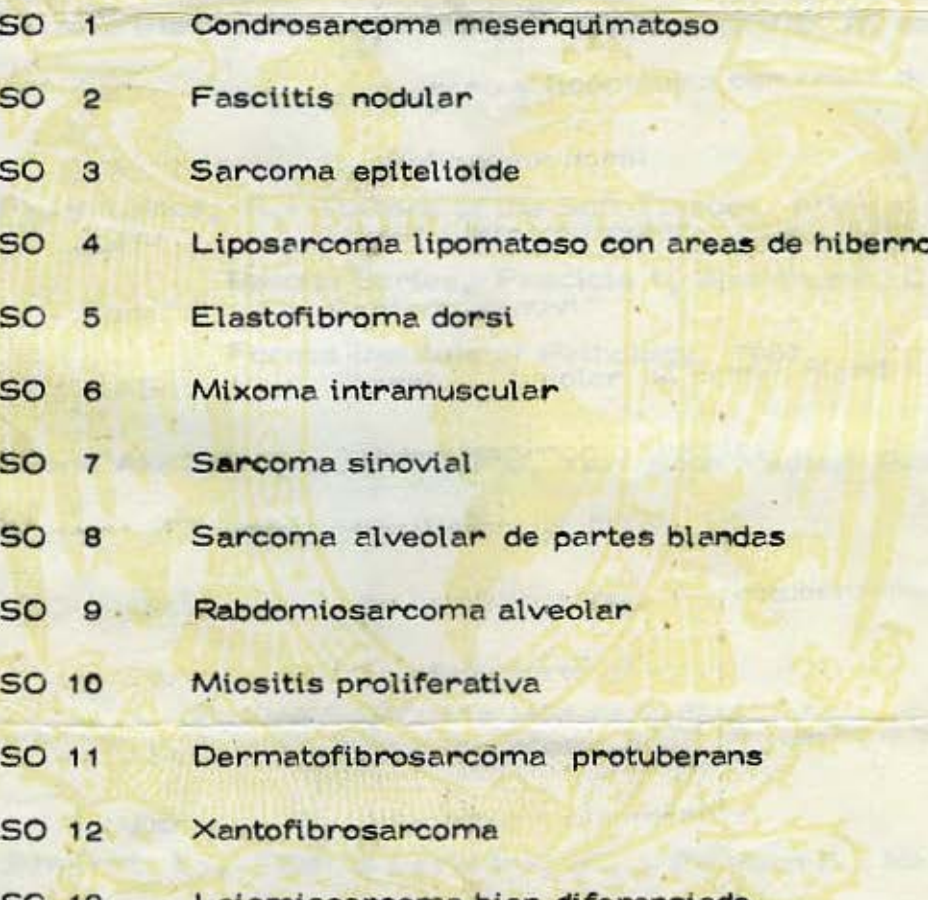


SEMINARIO SOBRE TUMORES DE PARTES BLANDAS

DIAGNOSTICOS

- 
- CASO 1 Condrosarcoma mesenquimatoso
- CASO 2 Fasciitis nodular
- CASO 3 Sarcoma epiteloide
- CASO 4 Liposarcoma lipomatoso con areas de hibernoma maligno
- CASO 5 Elastofibroma dorsi
- CASO 6 Mixoma intramuscular
- CASO 7 Sarcoma sinovial
- CASO 8 Sarcoma alveolar de partes blandas
- CASO 9 Rabdiosarcoma alveolar
- CASO 10 Miositis proliferativa
- CASO 11 Dermatofibrosarcoma protuberans
- CASO 12 Xantofibrosarcoma
- CASO 13 Leiomioma bien diferenciado
- CASO 14 Liposarcoma pleomórfico

SEMINARIO SOBRE TUMORES DE PARTES BLANDAS

REFERENCIAS GENERALES

- Albores Saavedra, J.: Sarcomas y lesiones pseudosarcomatosas de partes blandas. México, La Prensa Médica Mexicana, 1967.
- Enzinger, F.M.: Histological typing of soft tissue tumours. Ginebra, World Health Organization, 1969
- Stout, A.P., y Lattes, R.: Tumors of the Soft Tissues. Atlas of Tumor Pathology. Second Series, Fascicle 1, Washington, D.C., Armed Forces Institute of Pathology, 1967.
- Tumors of Bone and Soft Tissue. Chicago, Year Book Medical Publishers, Inc. 1965.

CONDROSARCOMA MESENQUIMATOSO

- Cárdenas Ramírez, L., Albores Saavedra, J., y De Buen S.: Mesenchymal chondrosarcoma of the orbit. Arch. Ophthalmol. En prensa.
- Cowling, E.A.: Mesenchymal chondrosarcoma, J. Bone Joint Surg. (Amer) 46: 747-754, 1964.
- Lichtenstein, L., y Bernstein, D.: Unusual benign and malignant chondroid tumors of bone. Cancer 12:1142-1157, 1959.

Salvador, H.A., Beabout, W.J., y Dahlin, D.: Mesenchymal chondrosarcoma. -
Observations on 30 new cases. Cancer 28:605-615, 1971.

FASCIITIS NODULAR

Hutter, R.V.P., Stewart, F.W., y Foote, Jr., F.W.: Fasciitis; a report of 70 -
cases with follow-up proving the benignity of the lesion. -
Cancer: 15:992-995, 1962.

Kleinstiver, B.J., y Rodríguez, H.A.: Nodular fasciitis; a study of forty-five cases
and review of the literature. J. Bone Joint Surg., 50-A:1204-
1212, 1968.

Konwaler, B.E., Keasbey, L., y Kaplan, L.: Subcutaneous pseudosarcomatous -
fibromatosis (fasciitis). Am.J.Clin.Path., 25:241-252, 1955

Price, Jr., E.B., Silliphant, W.M., y Shuman, R.: Nodular fasciitis: A clinico -
pathologic analysis of 65 cases. Am.J.Clin.Path. 35:122- -
136, 1961.

Stout, A.P.: Pseudosarcomatous fasciitis in children. Cancer 14:1216, 1222, 1961.

SARCOMA EPITELIOIDE

Bliss, B.O., y Reed, R.J.: Large cell sarcomas of tendon sheath. Malignant giant
cell tumors of tendon sheaths. Am.J.Clin.Path. 49:776-781,
1968.

Enzinger, F.M.: Epithelioid sarcoma. A sarcoma simulating a granuloma or a carcinoma. *Cancer* 26:1029-1041, 1970.

H I B E R N O M A

Brines, O.A., y Johnson, M.H.: Hibernoma, a special fatty tumor; report of a case. *Am.J.Path.* 25:467-479, 1949.

Gross, S. y Wood, C.: Hibernoma. *Cancer* 6:159-163, 1953.

May, C.J., D'Esopo, N.D., y Yewner, R.: Intrathoracic hibernoma. *Am.Rev. Resp.Dis.* 82:555-560, 1960.

Sutherland, J.C., Callahan, Jr., W.P., y Campbell, G.L.: Hibernoma: A tumor of brown fat. *Cancer* 5:364-368, 1952.

E L A S T O F I B R O M A D O R S I

Barfield, W.G., y Lee, C.K.: Elastofibroma: An electron microscopic study. *Nat.Cancer Inst.* 40:1067-1077, 1966.

Jarvi, O.H., Saxen, A.E., Hopsu-Havu, V.K., Wartiovaara, J.J., y Vaissalo, V.T.: Elastofibroma. A degenerative pseudotumor. *Cancer* 23:42-63, 1969.

Stemmermann, G.N., y Stout, A.P.: Elastofibroma dorsi. *Am.J.Clin.Path.* 37:499-506, 1962.

Winkelmann, R.K., y Mitchell-Sams, W.: Elastofibroma. Report of a case with special histochemical and electronmicroscopic studies. Cancer 23:406-415, 1969.

MIXOMA INTRAMUSCULAR

Enzinger, F.M.: Intramuscular myxoma; A review and follow-up study of 34 cases. Am.J.Clin.Path. 43:104-113, 1965.

Stout, A.P.: Myxoma, the tumor of primitive mesenchyme. Ann.Surg. 127:706-719, 1948.

Wirth, W.A., Leavitt, D. y Enzinger, F.M.: Multiple intramuscular myxomas; another extraskeletal manifestation of fibrous dysplasia. Cancer 27:1167-1173, 1971.

SARCOMA SINOVIAL

Cadman, L.N., Soule, E.H., y Kelly, J.P.: Synovial sarcoma. An analysis of 134 tumors. Cancer 18:613-627, 1965.

Crocker, D.W., y Stout, A.P.: Synovial sarcoma in children. Cancer 12:1123-1133, 1959.

Mackenzie, H.D.: Synovial sarcoma. A review of 58 cases. Cancer 19:169-190, 1964.

SARCOMA ALVEOLAR DE PARTES BLANDAS

Altamirano D., M. y Albores-Saavedra, J.: Alveolar soft part sarcoma of the orbit. Arch.Ophthal. 75:496-499, 1966.

Christopherson, W.M., Foote, Jr., F.W., y Stewart, F.W.: Alveolar soft part sarcomas; structurally characteristic tumors of uncertain histogenesis. Cancer 5:100-111, 1952.

Fisher, E.R., y Reidbord, H.: Electron microscopic evidence suggesting the myogenous derivation of the so-called alveolar soft part sarcoma. Cancer 27:150-159, 1971.

Lieberman, P.H., Foote, Jr., F.W., Stewart, F.W., y Berg, J.W.: Alveolar soft-part sarcoma. J.A.M.A. 198:1047-1051, 1966.

Shipkey, F.H., Lieberman, P.H., Foote, Jr., F.W., y Stewart, F.W.: Ultrastructure of alveolar soft part sarcoma. Cancer 17:821-830, 1964.

RABDOMIOSARCOMA ALVEOLAR

Albores Saavedra, J.: Rhabdomyosarcoma. En Progress in Clinical Cancer. Grune Straton, Inc. New York, Pag. 683-691, 1965.

Enzinger, F.M., y Shiraki, M.: Alveolar rhabdomyosarcoma. An analysis of 110 cases. Cancer 24:18-31, 1969.

MIOSITIS PROLIFERATIVA

Enzinger, F.M., y Dulcey, F.: Proliferative myositis; report of thirty-three cases
Cancer 20:2213-2223, 1967.

Kern, W.H.: Proliferative myositis; a pseudosarcomatous reaction to injury; A —
report of seven cases. Arch. Path. 69:209-216, 1960.

DERMATOFIBROSARCOMA PROTUBERANS

Adams, J.T., y Saltztein, S.L.: Metastasis ing dermatofibrosarcoma protuberans;
report of two cases, Amer.Surg. 29:878-886, 1963.

Burkhardt, B.R., Soule, E.H., Winkelman, R.K., y Ivins, J.C.: Dermatofibrosar-
coma protuberans. Study of 56 cases. Amer.J.Surg. 111: -
638-644, 1966.

Fisher, E.R., y Vuzevski, V.D.: Cytogenesis of schwannoma (neurilemoma), neuro-
fibroma, dermatofibroma, and dermatofibrosarcoma as -
revealed by electron microscopy. Amer.J.Clin.Path. 49: -
141-154, 1968.

Taylor, H.B., y Helwig, E.B.: Dermatofibrosarcoma protuberans: a study of 115 -
cases. Cancer 15:717-725, 1962.

FIBROXANTOMA ATÍPICO Y FIBROXANTOSARCOMA

Kempson, R.L., y McGavran, M.H.: Atypical fibroxanthomas of the skin. *Cancer* 17:1463-1471, 1964.

Kempson, R.L. y Kyriakos, M.: Fibroxanthosarcoma of the soft tissues; a type of malignant fibrous histiocytoma. *Cancer* (en prensa).

Kroe, D.J., y Pitcock, J.A.: Atypical fibroxanthoma of the skin; report of ten cases. *Am.J.Clin.Path.* 51:487-492, 1969.

Merkow, L.P., Frich, Jr., J.C., Slifkin, M., Kyreages, C.G., y Pardo, M.: Ultrastructure of a fibroxanthosarcoma (malignant fibroxanthoma). *Cancer* 28:372-383, 1971.

O'Brien, J.E., y Stout, A.P.: Malignant fibrous xanthomas. *Cancer* 17:1445-1455, 1964.

LEIOMIOSARCOMA

Phelan, J.T., Sherer, W., y Mesa, P.: Malignant smooth-muscle tumors (leiomyosarcomas) of soft-tissue origin. *New Eng.J.Med.* 266:1027-1030, 1962

Stout, A., y Hill, W.T.: Leiomyosarcoma of the superficial soft tissues, *Cancer* 11:844-854, 1958.

L I P O S A R C O M A

Enterline, H.T., Culberson, J.D., Rechlin, D.B., y Brady, L.W.: Liposarcoma; a clinical and pathological study of 53 cases. *Cancer* 13:932-950, 1960.

Enzinger, F.M., y Winslow, D.J.: Liposarcoma; a study of 103 cases. *Virchows Arch.Path. Anat.* 335:367-388, 1962.

Reszel, P.A., Soule, E.H., y Coventry, M.B.: Liposarcoma of the extremities and limb girdles. *J.Bone Joint Surg.* 48-A:229-244, 1966.

Rosas-U., A., Ring, A.M., y Rappaport, H.: Metastasizing retroperitoneal fibroxanthoma (malignant fibroxanthoma). *Cancer* 26:827-831, 1970.

Scarpelli, D.G., y Greider, M.H.: A correlative cytochemical and electron microscopic study of a liposarcoma. *Cancer* 15:776-789, 1962.